

Case
Report

Reoperation for Mid-term Failure of a Freestyle Bioprosthesis Using a Full Root Technique —A Surgical Case—

Hiromasa Nakamura, MD, Hiroki Yamaguchi MD, PhD, Tatsuya Nakao, MD, PhD, Yu Oshima, MD, PhD, Noriyuki Tokunaga, MD, PhD, Mikiko Murakami, MD, PhD, and Shinichi Mitsuyama, MD

The aortic root of a 30-year-old man was replaced with a Freestyle stentless aortic bioprosthesis for aortic regurgitation associated with annuloaortic ectasia. His clinical course was uneventful, and he was discharged without complications. Three years and six months after surgery, he presented with a high fever. Four years after surgery, transthoracic echocardiography revealed severe aortic regurgitation. We performed exploratory surgery and discovered a torn left coronary cusp of the Freestyle bioprosthesis. Organized vegetation was adherent to the left coronary cusp leaflet. The non-coronary cusp and the right coronary cusp were normal. The diagnosis was aortic regurgitation due to valve failure related to infective endocarditis. Consequently, we reconstructed the aortic root with a composite graft (26-mm Valsalva graft and a 21-mm ON-X mechanical valve).

Key words: freestyle bioprosthesis, infective endocarditis, full root technique

Introduction

Freestyle stentless aortic bioprosthesis (Medtronic Inc., Minneapolis, MN, USA) implanted by a full root technique for aortic root replacement offers a large effective orifice area (EOA) with lower gradients, lower prevalence of aortic regurgitation (AR), and a better, functional, New York Heart Association (NYHA) class on follow-up.¹⁾ Furthermore, early redo surgery is rarely required when the full root technique is used for implantation of a Freestyle bioprosthesis.²⁻⁴⁾

Here, we report midterm failure of the Freestyle bioprosthesis that was implanted by the full root technique.

Department of Cardiovascular Surgery, Shin Tokyo Hospital, Matsudo, Chiba, Japan

Received: December 15, 2009; Accepted: March 10, 2010
Corresponding author: Hiromasa Nakamura, MD. Department of Cardiovascular Surgery, Shin Tokyo Hospital, 473-1 Nemoto, Matsudo, Chiba 271-0077, Japan
Email: nakamurakin-ths@umin.ac.jp
©2011 The Editorial Committee of *Annals of Thoracic and Cardiovascular Surgery*. All rights reserved.

Case Report

A 30-year-old male with severe AR associated with annuloaortic ectasia, related to Marfan syndrome, underwent aortic root replacement with a Freestyle stentless aortic bioprosthesis (29 mm), implanted by the full root technique. The ascending aorta was also replaced due to an aneurysm. The patient was discharged without complications and was followed up at Shin Tokyo Hospital, Chiba, Japan.

Three years after surgery, echocardiography showed no recurrence of AR, the left ventricular end-diastolic diameter (LVEDD) was 57 mm, left ventricular end-systolic diameter (LVESD), 44 mm, and left ventricular ejection fraction, 45%.

Three years and six months after the surgery, the patient was admitted to community hospital due to high fever, nausea, and vomiting. His blood culture confirmed the presence of *Streptococcus*; therefore, antibiotics were administered. Echocardiography revealed no vegetation or AR.

Four years after the surgery, a diastolic cardiac murmur

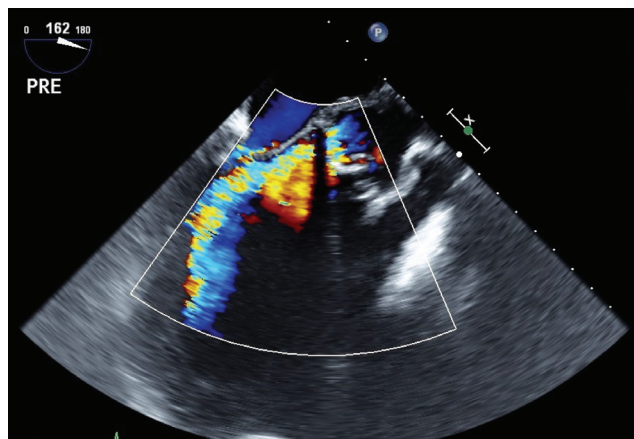


Fig. 1 Transesophageal echocardiogram of severe aortic regurgitation at the level of the Freestyle bioprosthesis.

developed, though it went unnoticed by the patient. Transthoracic echocardiography demonstrated the presence of severe AR: LVEDD and LVESD were considerably enlarged to 71 mm and 55 mm, respectively (**Fig. 1**).

The patient underwent a second surgery, during which the left coronary cusp (LCC) of the Freestyle bioprosthesis was found to be torn and detached from the aortic annulus (**Fig. 2**). An organized vegetation was adherent to the LCC leaflet. The non-coronary cusp and the right coronary cusp were normal. Consequently, the diagnosis was AR due to valve failure associated with infective endocarditis (IE). As the aortic root remained in good condition after the removal of the Freestyle bioprosthesis, we reconstructed it with a 26-mm Valsalva graft (Valsalva-prosthesis, Vascutec, Terumo) 21-mm On-X mechanical valve (On-X Life Technologies, IncTM) and TiCron 2-0 felt-butressed mattress sutures. Histological examination of the explanted Freestyle bioprosthesis revealed inflammatory cells and growth of fibrocytes in the connective tissue. No remarkable findings suggestive of infection were present. (**Fig. 3**)

The patient had an uneventful recovery and was discharged from the hospital 2 weeks after the surgery.

Discussion

Full root aortic replacement with a stentless tissue valve has become widely available over the past 15 years. Advantages of the stentless valve in the replacement mainly arise from the mechanics and hemodynamics of the valve and minimization of stress-related structural changes in the valvular tissue, resulting in prolonged

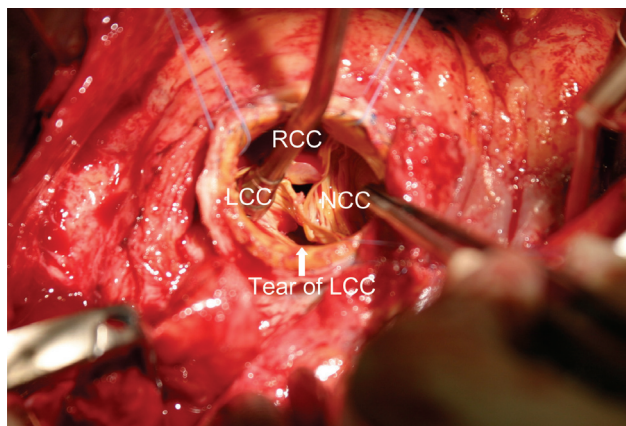


Fig. 2 Aortic view of the Freestyle bioprosthesis, showing perforation of the left coronary cusp.
LCC, left coronary cusp; NCC, non-coronary cusp; RCC, right coronary cusp

valve durability.⁵⁾

The Medtronic Freestyle aortic root bioprosthesis is the preferred biological valve substitute for root replacement at our institution; we prefer the root replacement technique since it is easier to perform than root implantation or root remodeling. Moreover, several clinical studies have demonstrated the excellent clinical performance of the Medtronic stentless valve over the last decade.⁶⁻¹¹⁾

A recent study by the Freestyle Valve Study Group demonstrated that full root implantation of valve prosthesis is associated with large EOA and lower gradients, a lower prevalence of AR, and better functional NYHA class on follow-up.¹⁾

Between August 2004 and April 2009, we performed full root aortic replacement with the Freestyle aortic root bioprosthesis in 51 patients. Two (3.9%) hospital deaths occurred. However, the 4-year survival rate was 93.3%, and the 4-year rate of freedom from recurrence of AR (more than grade) was 87.5%. The case we report here is of a patient in which AR recurred 4 years after the replacement surgery.

Some authors have reported early failure of the Freestyle stentless bioprosthesis.²⁻⁴⁾ Jurgen et al. reported the results of introducing the Freestyle stentless bioprosthesis in 1014 patients. There were 12 endocarditis episodes and 7 patients required reoperation (a subcoronary technique was used in 5 patients, and a full root technique in 2).¹²⁾ Otto also reported 93% freedom from endocarditis at 5 years with the stentless full root bioprosthesis.⁶⁾ In our case, AR was secondary to IE 4 years after surgery.

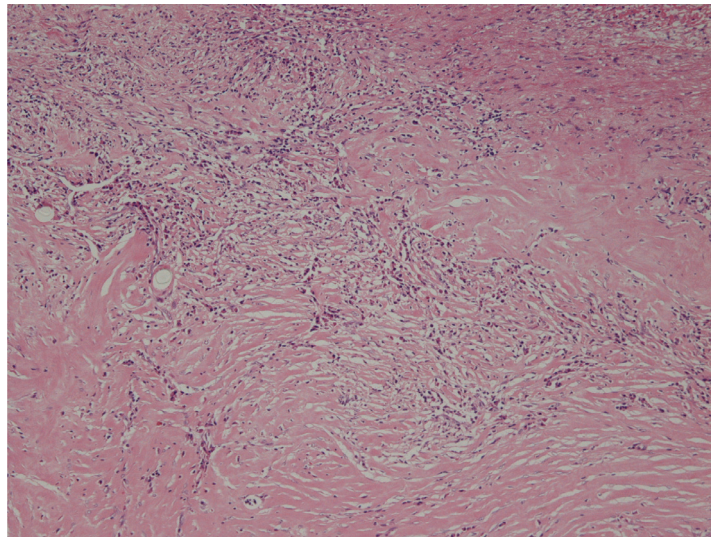


Fig. 3 Tissue section of inflammatory cells and fibrocytes in the connective tissue. samples from explanted Freestyle bioprosthesis. ($\times 40$ magnification and HE stain)

Conclusion

We presented a case of mid-term failure of a Freestyle bioprosthesis that was implanted by the full root technique. In this case, the failure of the Freestyle bioprosthesis was probably caused by infective endocarditis 4 years after the initial surgery.

References

- 1) Bach DS, Cartier PC, Kon ND, Johnson KG, Deeb GM, et al. Freestyle Valve Study Group. Impact of implant technique following freestyle stentless aortic valve replacement. *Ann Thorac Surg* 2002; **74**: 1107-13. Discussion 1113-4.
- 2) Kajiwara T, Imoto Y, Sakamoto M, Tanaka K, Matsumoto T, et al. Primary tissue failure of the freestyle stentless aortic root bioprosthesis. *Jpn J Thorac Cardiovasc Surg* 2003; **51**: 333-5.
- 3) Takami Y, Ina H. Resolution of perivalvular hematoma of the freestyle stentless aortic root bioprosthesis implanted with a subcoronary technique. *Jpn J Thorac Cardiovasc Surg* 2001; **49**: 675-8.
- 4) Kitamura A, Handa N, Shomura Y, Wakiyama H, Shinka M, et al. Reoperation for early failure of a freestyle bioprosthesis using a full root technique. *J Heart Valve Dis* 2007; **16**: 275-7.
- 5) Hazekamp MG, Goffin YA, Huysmans HA. The valve of the stentless bivalve prosthesis. An experimental study. *Eur J cardiothorac Surg* 1993; **7**: 514-9.
- 6) Dapunt OE, Easo J, Hölzl PP, Murin P, Südkamp M, et al. Stentless full root bioprosthesis in surgery for complex aortic valve-ascending aortic disease: a single center experience of over 300 patients. *Eur J Cardiothorac Surg*. 2008; **33**: 554-9.
- 7) David TE, Pollick C, Bos J. Aortic valve replacement with stentless porcine aortic bioprosthesis. *J Thorac Cardiovasc Surg* 1990; **99**: 113-8.
- 8) Westaby S, Huysmans HA, David TE. Stentless aortic bioprostheses: compelling data from the second international Symposium. *Ann Thorac Surg* 1998; **65**: 235-40.
- 9) Pibarot P, Dumesnil JG, Jobin J, Cartier P, Honos G, et al. Hemodynamic and physical performance during maximal exercise in patients with an aortic bioprosthetic valve: comparison of stentless versus stented bioprostheses. *J Am Coll Cardiol* 1999; **34**: 1609-17.
- 10) Kon ND, Riley RD, Adsir SM, Kitzman DW, Cordell AR. Eight-year results of aortic root replacement with the freestyle stentless porcine aortic root bioprosthesis. *Ann Thorac Surg* 2002; **73**: 1817-21. Discussion 1821.
- 11) Doty DB, Cafferty A, Cartier P, Huysmans HA, Kon ND, et al. Aortic valve replacement with Medtronic Freestyle bioprosthesis: 5-year results. *Semin Thorac Cardiovasc Surg* 1999; **11** (Suppl 1): 35-41.
- 12) Ennker JA, Ennker IC, Albert AA, Rosendahl UP, Bauer S, et al. The Freestyle Stentless Bioprosthesis in more than 1000 patients. *J Card Surg* 2009; **23**: 41-8.