

Five Cases of Lymphangioma of the Mediastinum in Adult

Taro Oshikiri, MD,¹ Toshiaki Morikawa, MD,¹ Eisei Jinushi, MD,²
Yoshikazu Kawakami, MD, PhD,² and Hiroyuki Katoh, MD, PhD¹

Mediastinal lymphangioma is a rare disease. Above all the cavernous type of mediastinal lymphangioma is very rare. We report 5 cases of mediastinal lymphangioma including cavernous type. All underwent a computed tomographic (CT) scan, which revealed smoothly margined and cystic lymphangioma. All were surgically resected and specimens were classified pathologically into cystic type (3 cases), cavernous type (1 case) and a mixed type of the two (1 case). Magnetic resonance imaging (MRI) was performed in the cavernous type and it suggested that the mass was lymphangioma because of a pathognomonic lesion. Despite that preoperative diagnosis of mediastinal lymphangioma is difficult, MRI is a useful examination. In the follow-ups there has been no recurrence in our series. (Ann Thorac Cardiovasc Surg 2001; 7: 103–5)

Key words: mediastinal lymphangioma, cavernous type, MRI

Introduction

Mediastinal lymphangioma is very rare, accounting for 0.7-4.5% of all mediastinal tumors.^{1,2)} Being asymptomatic, most of them are found in adulthood accidentally; preoperative diagnosis is difficult and most of them are diagnosed intra- or post-operatively. Here we report 5 adult cases of mediastinal lymphangioma that we have experienced, and discuss the usefulness of MRI at the preoperative diagnosis.

Case Reports

Five cases were 2 men and 3 women, ranging in age from 20 to 74 years old. Symptoms such as dyspnea and superior vena cava (SVC) syndrome were noticed only in 1 case where the mass was located in the upper mediastinum. The other 4 cases were asymptomatic and were in-

identally detected on chest X ray. The lesions were located in the upper mediastinum in 1 case, in the middle mediastinum in 1 case and in the posterior mediastinum in 3 cases. Chest CT was performed in all the cases, which revealed that all the masses had well defined margins, showing low attenuation inside. In all the cases the masses were pressing against the mediastinal vessels, but no invasion was observed. Magnetic resonance imaging (MRI) was carried out in the cavernous type (Fig. 1). T1-weighted MR image showed heterogenous texture, mostly low intensity areas but partially high intensity areas, from which mucoid matter was suspected. T2-weighted MR image showed mainly high intensity areas, where the structure of the septum was shown. Since the mass surface and a part of the septum were vaguely intensified on the image, a cystic tumor was suspected. From its multi-locular type and continuous extension in the potential space of the mediastinum, lymphangioma was the most likely diagnosis. Complete resection was attained in all the cases. However, in the cavernous type adhesion to the adjacent tissue was obstinate and resection was very difficult. Definite diagnosis was made from pathological examination of the resected specimens. They were cystic type in 3 cases, cavernous type in 1 case (Fig. 2) and mixed-type in 1 case. During the postoperative follow-ups ranging from 1 to 17 years at the longest, there

From the ¹Second Department of Surgery, and ²First Department of Internal Medicine, Hokkaido University Hospital, Sapporo, Japan

Received June 19, 2000; accepted for publication September 5, 2000.

Address reprint requests to Taro Oshikiri, MD: Second Department of Surgery, Hokkaido University Hospital, N-14, W-5, Sapporo 060-8648, Japan.

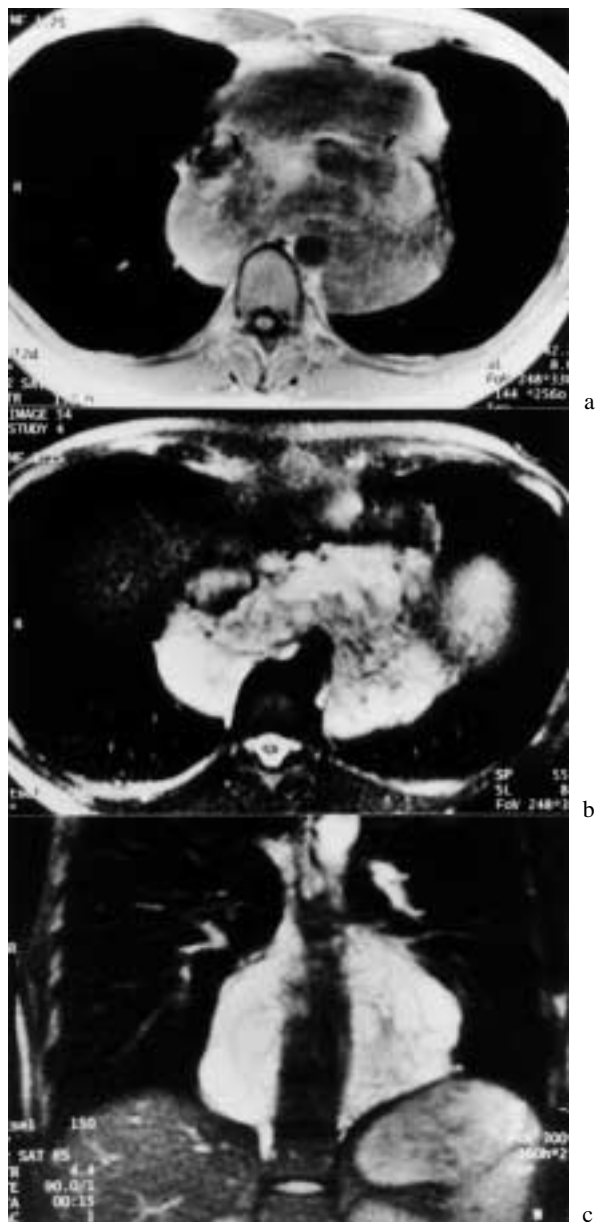

Fig. 1.
 a: T1-weighted MR image showed a mainly low-intensity signal but partially faint high-intensity signal, from which mucoid matter was suspected.
 b, c: T2-weighted MR image showed a mostly high-intensity signal, revealing the the multilocular septum within the mass.

has been no recurrence.

Discussion

Lymphangiomas are caused by congenital developmental anomalies. As they develop mostly in the body surface, 90% of all lymphangiomas are found by 2 years of age.³⁾ However, those developed in the mediastinum,

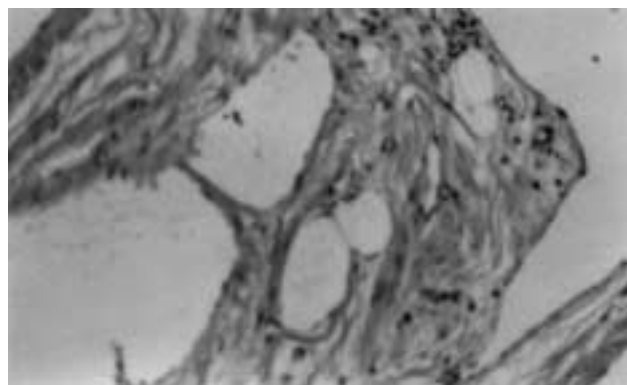


Fig. 2. Pathologically the lesion was a tumor derived from lymphatic vessels; the tumor wall consisted of medium- or small-size lumina containing lymphatic fluid and a mixture of loose collagen tissue and adipose tissue (Hematoxylin-eosin; $\times 100$).

which account for less than 1%, are mostly asymptomatic and found accidentally in adulthood. In our series, too, the masses were asymptomatic in 4 of the 5 cases; an abnormal image found on chest X ray was the clue to detection. As to CT findings of 19 cases of thoracic lymphangioma, Shaffer et al.⁴⁾ described that the most common characteristics were well-capsulated, smoothly margined and cystic, but they varied in type and density. Whereas Siegel⁵⁾ and Pilla et al.⁶⁾ reported that in MRI findings of lymphangioma, there were various signals in their series, and concluded that diagnosis of lymphangioma on image findings was difficult.

In all of our cases, the masses were shown as cystic tumors with smooth margins and their density was close to the signal of water or protein on CT. The tumor sizes averaged 11 cm and the mediastinum was oppressed in 60%. Despite the tumor diameter, the oppression was mild, which appeared to have contributed to the lack of symptoms. Although the MRI, performed in the cavernous type, did not present particularly abnormal signals, it revealed the multilocular septum within the mass, which was an important finding. Lymphangioma, cystic teratoma, cystic thymoma, or thymic cyst was the possible diagnosis. Cystic teratoma are mostly solid and often present with a high signal on T1-weighted image, reflecting fat contents in the cyst. Cystic thymoma are hardly cystic entirely, and most of thymic cysts are uni-locular. Additionally these tumors are localized in the precardiovascular region of the mediastinum. Taking the extending style into consideration, differential diagnosis of these tumors from lymphangioma can be done on MRI. Pathologically, lymphangiomas are classified into three types, i.e., cystic type (macro cystic type), simple type

(super micro cystic type) and cavernous type (micro cystic type). Since the mediastinum is hypobaric, most of them are cystic types. That is to say, the cavernous type and simple type are very rare.

Complete resection was attained in all of them and there has been no recurrence during the follow-ups for 18 years at the longest. The results prove the usefulness of the operation.

Conclusion

We experienced 5 cases of rare mediastinal lymphangioma. MRI is a useful examination tool at the preoperative diagnosis. No recurrences developed, which proves the effectiveness of surgical resection.

Reference

1. Shenoy SS, Barua NR, Patel AR, Culver GJ, Jennings EC. Mediastinal lymphangioma. *J Surg Oncol* 1978; **10**: 523–8.
2. Yacoub MH, Lise M. Intrathoracic cystic hygromas. *Respir Med* 1969; **63**: 107–11.
3. Feutz EP, Yune HY, Mandelbaum I, Brasher RE. Intrathoracic cystic hygroma: a report of three cases. *Diag Radiol* 1973; **108**: 61–6.
4. Shaffer K, Christenson MLR, Patz EF Jr, Young S, Farver CF. Thoracic lymphangioma in adults: CT and MR imaging features. *American Journal of Roentgenology* 1994; **162**: 283–9.
5. Sigel MJ, Glazer HS, St. Aomur TE, Rosenthal DD. Lymphangiomas in children: MR imaging. *Radiology* 1989; **170**: 467–70.
6. Pilla TJ, Wolverson MK, Sundaram M, et al. CT evaluation of cystic lymphangiomas of the mediastinum. *Radiology* 1982; **144**: 841–2.