Case Report

Double Left Renal Vein Associated with Abdominal Aortic Aneurysm

Riichiro Toda, MD,[1] Yoshifumi Iguro MD,[1] Yukinori Moriyama, MD,[2]
Yosuke Hisashi, MD,[1] Hiroshi Masuda, MD,[1] and Ryuzo Sakata MD[1]

Double left renal vein is a rare venous anomaly. We operated on a 72-year-old man with an abdominal aortic aneurysm (AAA) with a double left renal vein. Massive hemorrhage was encountered during encircling the tape around the abdominal aorta. One vein passing posterior to the aorta was injured. Further dissection revealed the presence of a double left renal vein forming a ring around the aorta. The patient underwent an abdominal aortic replacement following prompt repair of the injured vein. He had an uneventful postoperative course without renal complication. We missed that preoperatively that the computed tomographic (CT) scan had demonstrated a double left renal vein. Preoperative contrast-enhanced CT scan is useful and essential not only for evaluation of AAA, but also for establishing the presence of venous anomalies. Venous anomalies should be taken into consideration in an AAA operation. (Ann Thorac Cardiovasc Surg 2001; 7: 113–5)

Key words: double left renal vein, abdominal aortic aneurysm

Introduction

Several variations of left renal vein have been reported.[1-4] Of them, only two patients with a double left renal vein associated with abdominal aortic aneurysm (AAA) have been reported.[3] The presence of a renal vein anomaly causes a possibility of massive bleeding during an AAA operation. Therefore, surgeons should pay attention to this anomaly with an AAA operation. We herein present a surgical case of AAA with a double left renal vein.

Case

The patient was a 72-year-old man who had been medically treated for hypertension. During follow-up for hypertension, an abdominal ultrasound (US) revealed an AAA, about 5 cm in diameter. His blood pressure was 140/70 mmHg, and pulse rate 54 beats per minute on admission. His renal function was found to be slightly impaired with serum creatinine of 1.2 mg/dl and creatinine clearance of 51.7 ml/minute. Contrast-enhanced computed tomography (CT) demonstrated an AAA of about 5 cm, expanding from 3 cm below the renal arteries to both common iliac arteries (Fig. 1, top). An operation was performed through a vertical midline incision. Infra-renal type AAA involving the common iliac artery bifurcation was detected. After confirming the left renal vein was lying in a normal position, encircling the umbilical tape around the aorta was attempted with care to prevent injury to the lumbar arteries. However, massive hemorrhage was encountered on this maneuver. Further dissection revealed an injured vein passing posterior to the aorta. Compression by two fingers on both sides of the injured vein made it easier to perform direct repair using 5-0 polypropylene. The injured vein lying posterior to the aorta was about one-third of the inferior vena cava (IVC) in diameter. Further examination revealed the presence of a double left renal vein forming a ring around the aorta (Fig. 2). AAA replacement was performed using an infra-renal aorto-bicommon iliac bifurcated knitted Dacron graft (20mm × 10 mm × 10 mm). He had an uneventful postoperative course without deterioration of

From the [1]Second Department of Surgery, Faculty of Medicine, Kagoshima University, Kagoshima, and [2]Department of Cardiovascular Surgery, National Takasaki Hospital, Takasaki, Japan

Received June 2, 2000; accepted for publication September 12, 2000.
Address reprint requests to Riichiro Toda, MD: Second Department of Surgery, Faculty of Medicine, Kagoshima University, 8-35-1 Sakuragaoka, Kagoshima 890-8520, Japan.

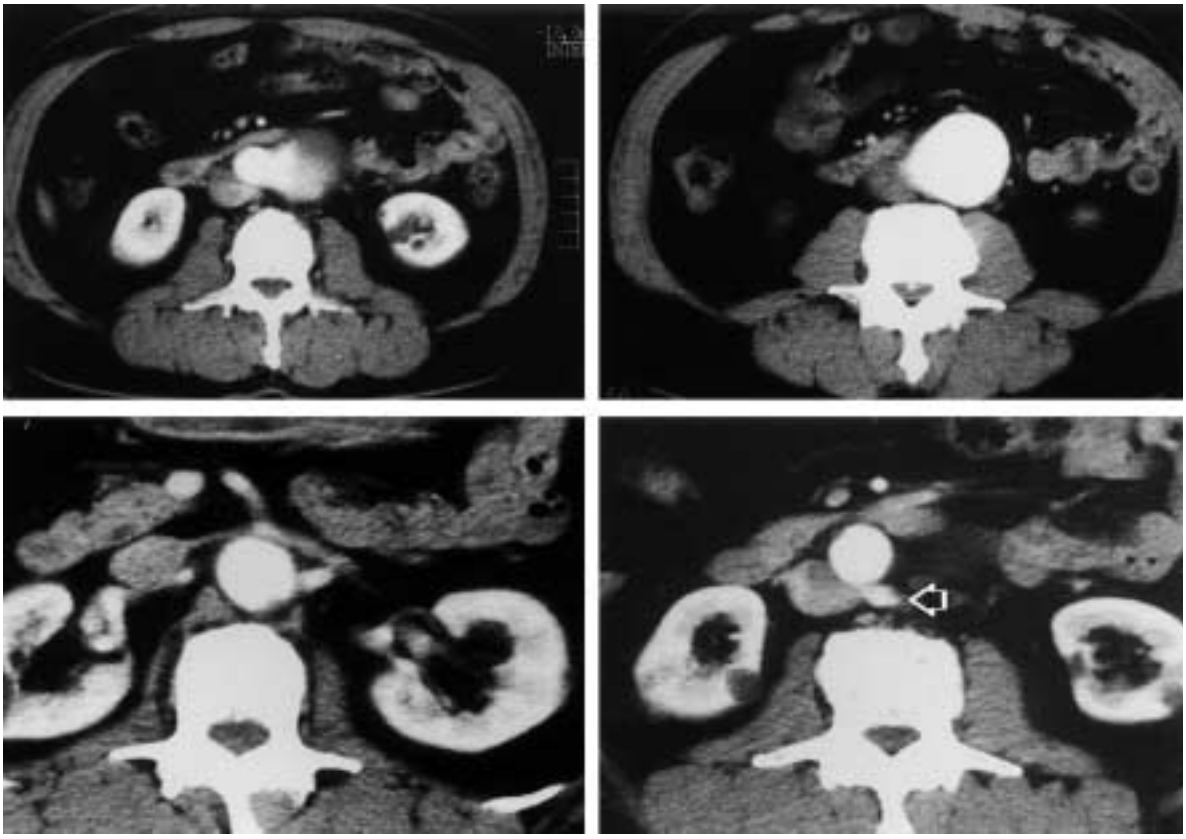

Fig. 1. Preoperative contrast-enhanced CT.
Top: CT identified the presence of an infra-renal AAA, 5 cm in diameter, involving the common iliac artery bifurcation; bottom: CT demonstrated a double left renal vein. One is normal-appearing, the other is lying retroaorta (arrow).

renal function. His postoperative serum creatinine was 1.3 mg/dl. We missed preoperatively that contrast-enhanced CT had demonstrated a double left renal vein forming a ring around the aorta (Fig. 1, bottom)

Discussion

In the embryo, a plexiform collar encircles the aorta and drains the blood from the permanent kidney. This collar connects with two sets of paired longitudinal channels, the subcardinal and supracardinal veins. Normally, only the anterior part persists and develops into the renal veins which thus lie anterior to the aorta and the renal arteries. Persistence of the whole collar on the left results in the anomalous condition of an additional renal vein which passes posterior to the aorta. This type anomaly was considered to be one type of double vena cava, in which Baldridge argued, the left-sided vena cava developed poorly or segmental.[1] These developments result in the left double renal vein encircling the aorta.

Several variations of a left renal vein have been reported.[1-4] They were renal collars, retroaortic vein, additional veins, and posterior primary tributary. The definition of renal collars is similar to circumaortic venous collar. Double renal vein is thought as renal collars or circumaortic venous collar. The incidence of this type of anomaly is reported to be from 1.5% to 8.7%.[1-2] However, the number of cases having a double renal vein with an AAA that have been reported were only two.[3] Other cases in the literature were other inferior vena cava and renal vein anomalies with an AAA. Our patient was the third case with this type of anomaly with an AAA. This anomaly is especially dangerous because the surgeon having identified a normal-appearing left renal vein, may not suspect a large vein lying posterior to the aorta, which can easily be injured. In our case, injury to one of the left renal veins lying posterior to the aorta occurred during encircling the umbilical tape around the abdominal aorta after identifying the normal-appearing left renal vein. Brener and Nonami emphasized the importance of the presence of the retroaortic renal vein indicating the possibility of severe hemorrhage.[3,4]

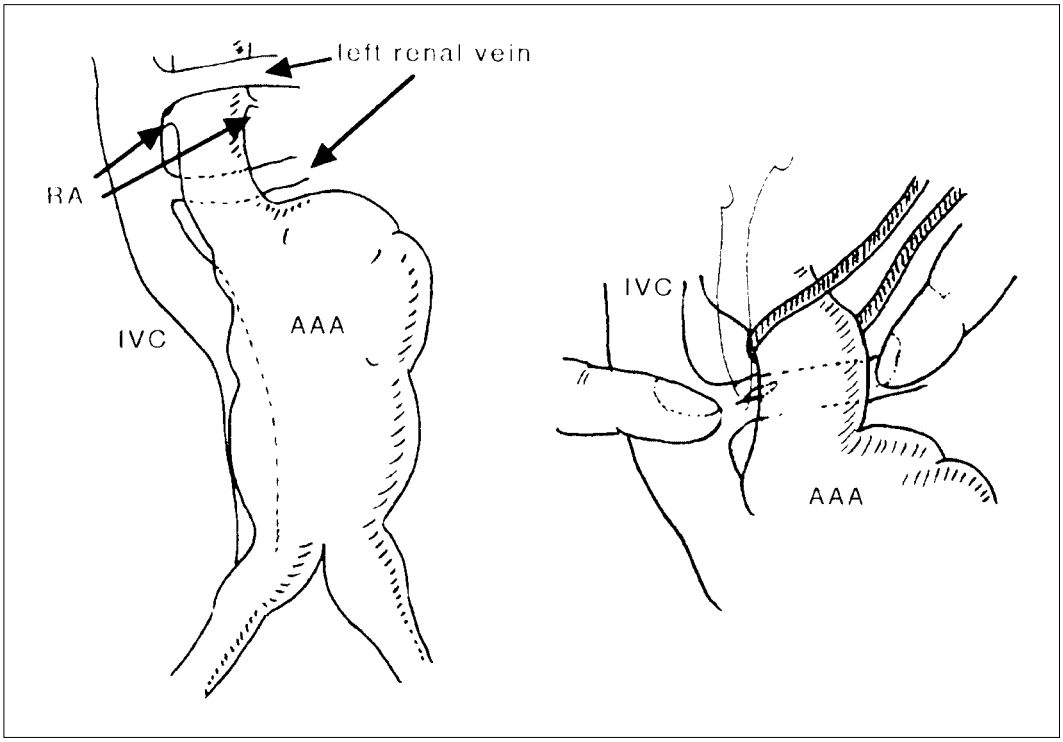

Fig. 2. Schema of intraoperative findings and repair of the injured vein.
RA: renal artery, IVC: inferior vena cava, AAA: abdominal aortic aneurysm.

Direct repair or ligation of the injured vein was considered to control bleeding. Nonami performed ligation of the injured vein,[4] and Brener did nephrectomy in two patients.[3] Fortunately, direct repair using 5-0 polypropylene under compression method by fingers on both sides of the injured vein was successfully carried out in our case. Though ligation of the injured additional left renal vein lying retroaorta could be made, we did not ligate it. It has been controversial whether ligation of the left renal vein in resection of an AAA deteriorates postoperative renal function or not.[5,6]

We missed preoperatively the presence of a double left renal vein on contrast-enhanced CT. Careful evaluation by CT is necessary and important. Aortography and/or venography has not usually been done in our institute on AAA patients. Contrast-enhanced CT can give us enough information about AAA and venous anomalies. Surgeons should pay attention to venous anomalies with an AAA operation.

References

1. Baldridge ED, Canos AJ. Venous anomalies encountered in aortoiliac surgery. *Arch Surg* 1987; **122**: 1184–8.
2. Satyapal KS, Kalideen JM, Haffejee AA, Singh B, Robbs JV. Left renal vein variations. *Surg Radiol Anat* 1999; **21**: 77–81.
3. Brener BJ, Darling RC, Frederick PL, Linton RR. Major venous anomalies complicating abdominal aortic surgery. *Arch Surg* 1974; **108**: 159–65.
4. Nonami Y, Yamasaki M, Sato K, Sakamoto H, Ogoshi S. Two types of major venous anomalies associated with abdominal aneurysmectomy: a report of two cases. *Surgery Today Jpn J Surg* 1996; **26**: 940–4.
5. Adar R, Rabbi I, Bass A, Papa MZ, Schneiderman J, Walden R. Left renal vein division in abdominal aortic aneurysm operations: effect on renal function. *Arch Surg* 1985; **120**: 1033–6.
6. AbuRahma AF, Robinson PA, Boland JP, Lucente FC. The risk of ligation of the left renal vein in resection of the abdominal aortic aneurysm. *Surg Gynecol Obstet* 1991; **173**: 33–6.