Original Article

Diagnostic Validity of Computed Tomography for Mediastinitis after Cardiac Surgery

Hiroichiro Yamaguchi, MD,[1] Hideto Yamauchi, MD,[1] Takafumi Yamada, MD,[1]
Tsuneo Ariyoshi, MD,[1] Hisayuki Aikawa, MD,[2] and Yukio Kato, MD[2]

Background: Optimal treatment based on appropriate early diagnosis is essential in managing mediastinitis after cardiac surgery. We evaluated the accuracy of thoracic computerised tomography (CT) in the diagnosis of mediastinitis.
Methods: Forty-one patients underwent CT after cardiac surgery and were classified into two groups as follows; six cases had mediastinitis requiring a redo surgical intervention (Group M). Thirty-five cases recovered without mediastinitis (Group C). Comparisons of CT findings in both groups were made retrospectively.
Results: In group M, CT and re-operations were performed 6.3±2.5 days and 8.0±5.2 days after the previous operation, respectively. All but one of redo surgical procedures were mediastinal lavage and omental transplantation. Two patients died due to septic shock and multiple organ failure. CT in group M showed a soft tissue mass with contrast enhancement in 4 patients, bilateral pleural effusion in 5, free gas appearance in 4, and sternal dehiscence or destruction in 2 patients. Consequently, we regarded 4 of the 6 patients in this group as showing postoperative mediastinitis radiographically. In group C, CT was carried out 16.6±7.1 days after the operation revealing findings suggestive of mediastinitis in 6 patients. Therefore, in terms of the validity of CT for the diagnosis of mediastinitis, the sensitivity was 67% and the specificity was 83%.
Conclusion: The sensitivity of CT for diagnosis of mediastinitis after cardiac operations is unsatisfactory. Diagnosis by seeking infective changes in a multidisciplinary way is important in dealing with mediastinitis. (Ann Thorac Cardiovasc Surg 2001; 7: 94–8)

Key words: cardiac surgery, computed tomography, mediastinitis

Introduction

Mediastinitis after cardiac surgery is a life-threatening complication, and optimal treatment based on early accurate diagnosis is essential for its management. Computed tomography (CT) is widely used for evaluating pathological process in the mediastinum and is a convenient method for the diagnosis of postoperative mediastinitis.[1,2] However, few reports have been made focusing on CT findings of mediastinitis after cardiac surgery.[3,4] In this study, the reliability of thoracic CT for diagnosis of postoperative mediastinitis is evaluated by retrospectively comparing CT findings in patients with mediastinitis requiring surgical reinterventions with those without mediastinitis.

From the Departments of [1]Cardiovascular Surgery, and [2]Radiology, Oita Prefectural Hospital, Oita, Japan

Received July 21, 2000; accepted for publication August 16, 2000.
Address reprint requests to Hiroichiro Yamaguchi, MD: Department of Cardiovascular Surgery, Oita Prefectural Hospital, Oita. Japan.

Patients and Methods

From April 1995 to March 2000, 350 consecutive patients who underwent cardiac surgery through a midline sternotomy were included in this study. Postoperative mediastinitis requiring surgical reexploration occurred in 6 patients (coronary artery bypass grafting in 3 patients, valvular surgery in 2, and total arch replacement

Table 1. Patient characteristic in group M

Case	Age/gender	Procedures	CT (POD)	Redo (POD)	Definitive evidence	Pathogen	Results
1	50 / F	AVR + MVR	11	18	pus (wound)	MRSA	alive
2	74 / F	CABG	7	9	pus (drain)	MRSA	dead
3	68 / F	AVR	6	6	pus (wound)	MRSA	dead
4	79 / M	CABG	5	6	pus (wound)	MRSA	alive
5	64 / M	total arch replacement	4	4	pus (drain)	MRSA	alive
6	62 / M	CABG	5	5	pus (wound)	MRSA	alive

POD: post operative day, AVR: aortic valve replacement, MVR: mitral valve replacement, CABG: coronary artery bypass grafting, MRSA: methicillin-resistant *Staphylococcus Aureus*.

in 1 patient). The median age was 66 years (range, 50 to 79 years). The definition of mediastinitis was regarded as the wound infection with sternal osteomyelitis with infected retrosternal space.[3] The final diagnosis was made on the basis of a positive bacterial culture from the mediastinum. All had a thoracic CT before reexploration (Group M). Five patients received contrast material intravenously, but one did not owing to compromised renal function. On the other hand, 35 patients had postoperative CTs because of the suspicion of mediastinitis in 25 (fever of unknown origin 17, wound breakdown,[8] follow-up of thoracic aortic surgery in 4, lung disease in 4, and hemothorax in 2 (Group C). The median age was 67 years (range 47 to 84 years). All of the patients recovered and were discharged without suffering mediastinitis. We reviewed all scans retrospectively based on radiological reports, and comparisons were made between the two groups.

Results

In group M, purulent discharge was found from the midline wound in 4 patients and from the drainage tube in the retrosternal space in 2 patients. Microbiological examination confirmed that the mediastinitis was caused by methicillin-resistant *Staphylococcus Aureus* in all patients. Subsequent surgical reexploration performed 8.0±5.2 days after the first operation included simultaneous mediastinal lavage and the transfer of an omental flap to the retrosternal space in 5 patients and secondary transfer of an omental flap in 1 patient after lavage for several days. Two patients in whom infection was difficult to control died of septic shock and multiple organ failure (Table 1).

CTs were performed 6.3±2.5 days after the initial operation. CT findings included mediastinal soft tissue mass with contrast enhancement containing fluid collection in 4 patients, bilateral pleural effusion in 5, free gas appearance in 4, and sternal dehiscence or destruction in 2 patients. Accordingly, 4 patients whose CT revealed abnormal soft tissue mass, suggesting abscess formation in the mediastinum, were strongly suspected of having mediastinitis (Table 2).

Table 2. CT findings in group M

Case	1	2	3	4	5	6
- Soft tissue mass (fluid collections) with contrast enhancement	○	○	○	○	×	×
- Bilateral pleural effusion	○	×	○	○	○	○
- Sternal dehiscence or destruction	○	×	×	×	×	○
- Free gas	○	×	×	○	○	○
Suspected mediastinitis	○	○	○	○	×	×

The CTs of 4 patients of mediastinitis which was diagnosed radiologically in group M (true-positive) are shown in Fig. 1. Soft tissue mass with contrast enhancement suggestive of abscess formation, bilateral pleural effusion, and free gas may indicate infectious mediastinitis. On the other hand, a CT which did not appear to be suggestive of mediastinitis is shown in Fig. 2 (false-negative). It showed only high density fluid collection around the drainage tube in the retrosternal space and minimal free gas. Marked septic symptoms continued clinically, despite CT findings not demonstrating pathological changes consistent with mediastinitis radiologically. Therefore, surgical reexploration was undertaken, and we found an unexpected massive pus accumulation in the mediastinum.

In group C, CT was carried out 16.6±7.1 days after the operation because of the suspicion of mediastinitis in 25 patients and for miscellaneous reasons in 10 patients. Six patients of the former subgroup were suspected of having mediastinitis radiologically (false-positive). They had a soft tissue mass with contrast enhancement containing fluid collection in the retrosternal space with or without free gas and pleural effusions. As such, we

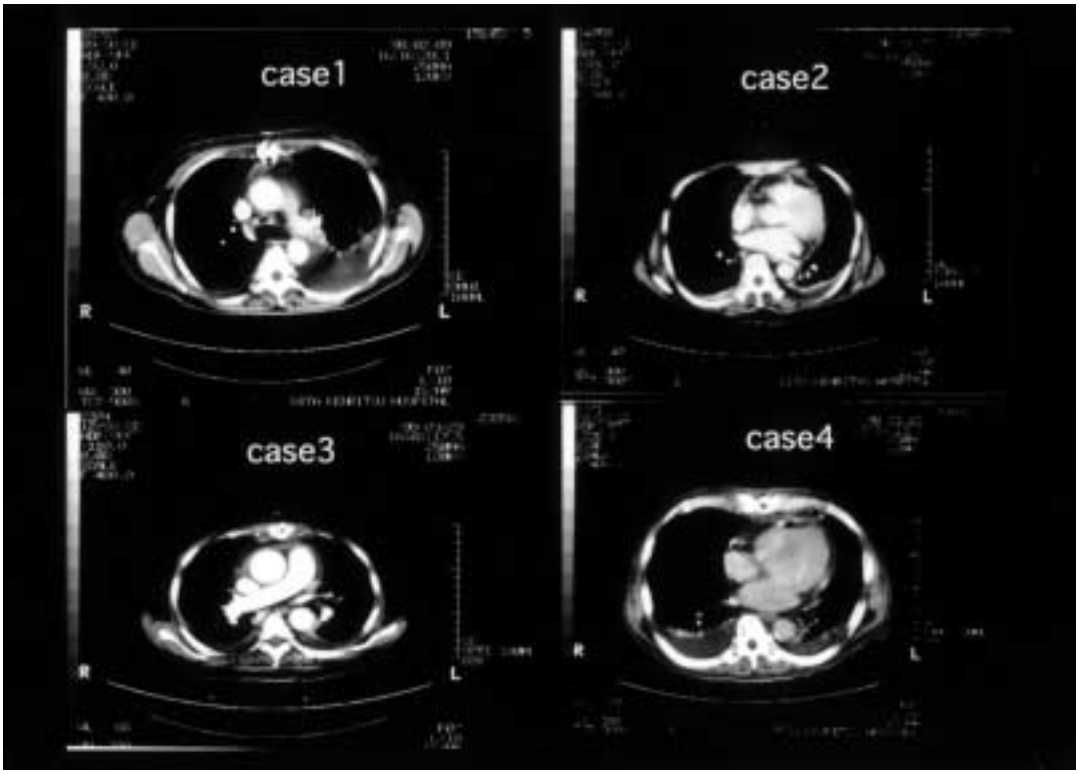

Fig. 1. CT findings suggestive of the mediastinitis in 4 patients of group M (true-positive). All had soft tissue mass suggestive of abscess formation. Bilateral pleural effusion in case 1, 3, and 4, free gas in case 1 and 4, and sternal dehiscence in case 1 are shown.

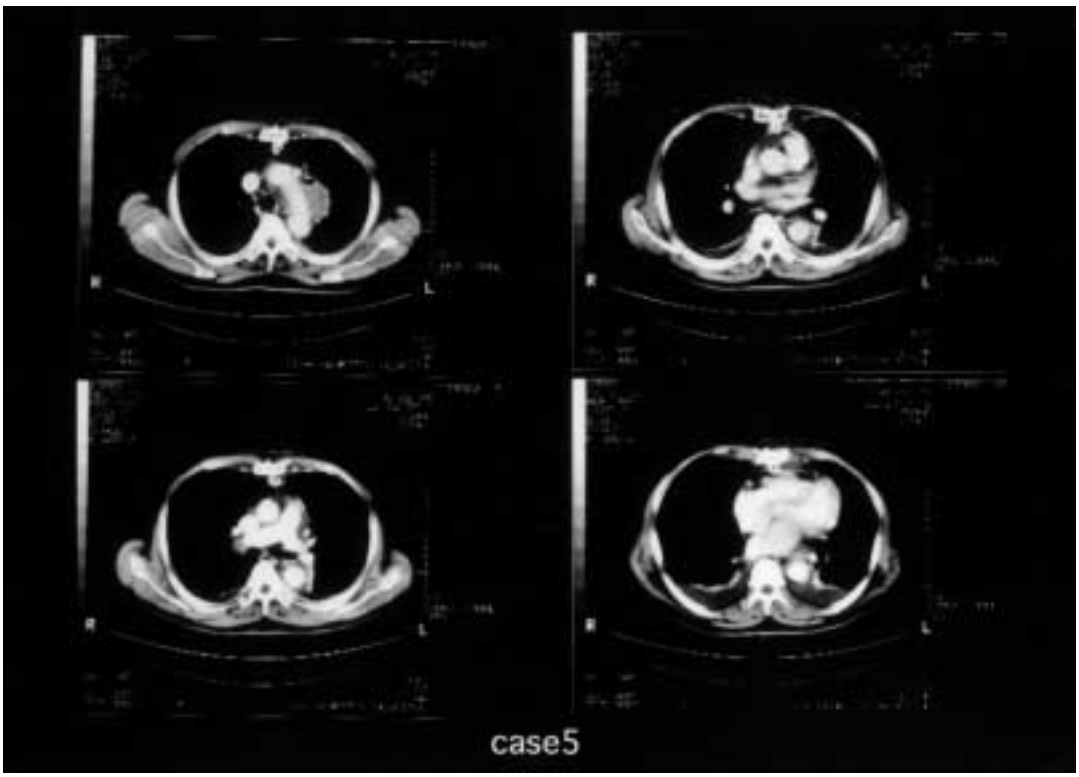

Fig. 2. CT in one of false-negative in group M. Localized fluid collection around the drainage tube in the retrosternal space revealed massive pus accumulation in the anterior mediastinum at the time of reexploration.

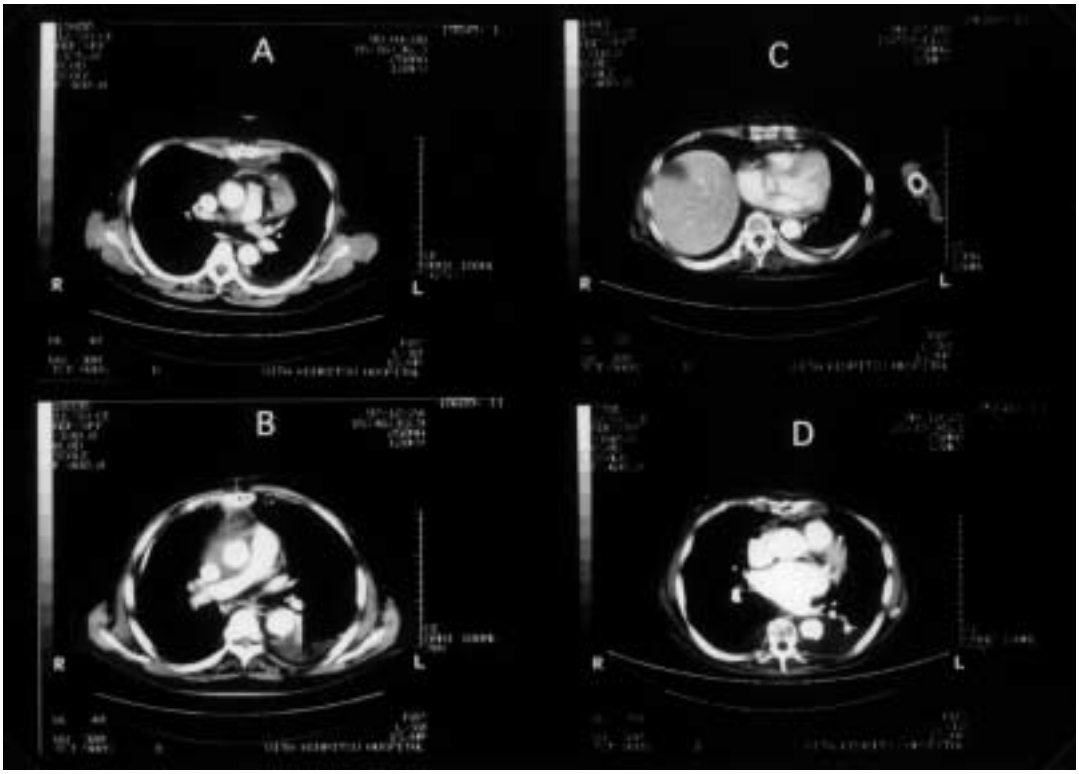

Fig. 3. CT findings in 4 patients diagnosed with mediastinitis in group C (false-positive). Massive irregular soft tissue mass suggestive of abscess formation are found in A and B, whereas localized fluid collection is found in C and D.

were not able to exclude the possible presence of infectious mediastinitis. The CTs of 4 of the cases are shown in Fig. 3. All of them were managed conservatively, recovered, and were discharged without further development of sepsis.

In summary, of the 6 instances of mediastinitis, 4 showed abnormal CT findings suggesting mediastinitis, thus giving a sensitivity of 67%. On the other hand, CT was falsely-positive in 6 of 35 scans, giving a specificity of 83%.

Discussion

In general, the CT diagnosis of mediastinitis is based on the presence of mediastinal air and fluid collections with or without peristernal abnormalities, such as edema of the adjacent soft tissues or sternal separation.[1,8] However, even in poststernotomy patients without problems, postoperative changes, such as focal edema, focal hematomas, and minor sternal irregularities, may still be present 2-3 weeks after operation.[1] Bubbles of mediastinal air, if present, usually resolve by 7 days after surgery, but may persist for longer.[1] Minor sternal separation has been seen up to 6 months postoperatively and defects in sternal closure do not necessarily indicate a significant clinical problem.[1,4] Concerning the CT diagnosis of mediastinitis in our patients, therefore, we emphasized the importance of abnormal fluid collections suggestive of abscess formation in the anterior mediastinum.

CT findings in 4 patients of the true-positive group in this study were able to be distinguished from normal postoperative appearance with confidence. Massive irregular soft tissue mass with contrast enhancement around the mass were the pathognomotic findings. Similar CT findings were not evident in one of 2 patients who was thus false-negative because he did not receive intravenous contrast material because of compromised renal function. In another patient in the false-negative group the CT revealed a small amount of fluid that had collected around the drainage tube in the retrosternal space. We did not expect to find the massive pus collection which was occupying the anterior mediastinum. In retrospect, both CTs in the false-negative cases showed bilateral pleural effusion, which appeared also in the CTs in 3 patients of 4 of the true-positive cases. Misawa et al.[3]

emphasized the importance of soft tissue mass combined with bilateral pleural effusion as a characteristic CT finding in poststernotomy infectious mediastinitis. The radiological literature pays less attention to pleural effusion as the evidence of mediastinitis,[1,8] however, it may be a useful predictor.

False-positives on CT study is another cause of concern. CT findings in 6 patients of the control group showed abnormal soft tissue mass with contrast enhancement around them, and were strongly suggestive of mediastinal abscess formation. On re-examining these 6 scans, the soft tissue mass was clearly separated from the surrounding tissue and was localized at the site of the draining sinus tract in 3 of 6, which might have made us confuse sterile fluid collections with the abscess formation. However, another 3 cases had a mild to moderate irregular soft tissue mass in the retrosternal space similar to the findings in patients who were true-possitives. In addition, one of them had a massive bilateral pleural effusion, which was the reason why we were not able to differentiate these findings from those of mediastinitis.

A sensitivity of 67% of CT for clinical mediastinitis as reported in this study is not satisfactory. Bitkover and colleagues[4] reported a sensitivity of only 25%, whereas Goodman and colleagues[1] demonstrated that CT was better able to distinguish patients without significant infection from those with major infection. The timing of the CT examination within the postoperative period is thought to be explain this wide discrepancy in the reliability of CT. Jolles et al.[2] demonstrated that CT had a sensitivity of 100% for clinical mediastinitis but a specificity of 33% through postoperative day 14, whereas the sensitivity and the specificity were 100% after postoperative day 14, which reflects the difficulty of the diagnosis by CT in the earlier period following surgery. In previous reports, most cases of mediastinitis occur within the first few postoperative weeks.[7,8] A notable feature in patients with mediastinitis in our series was that mediastinitis developed relatively earlier after the cardiac operation. This might be one of the factors which determined the lower sensitivity. On the other hand, an 83% specificity means that a negative CT scan is useful in directing attention elsewhere for a source of postoperative sepsis. It is supposed that later postoperative CT examinations in the control group, compared with those in the mediastinitis group, might cause the earlier postoperative error bias influence and should account for less diagnostic error. However, 6 of the false-positives did not develop mediastinitis requiring surgical intervention, and they could be managed conservatively. There also remains the possibility that concealed mediastinitis not requiring surgical reexploration existed. This confused clinical situation in the diagnosis of mediastinitis in this study might lead to an incorrect assessment of the reliability of CT, and may leave the methodology of this study open to criticism.

Conclusion

This study shows that the sensitivity of CT for the diagnosis of mediastinitis after cardiac surgery is not satisfactory. The overlap of the pathological process due to mediastinitis and the “normal” appearance in the early postoperative period serves to compromise the reliability of the CT diagnosis of mediastinitis. In this period, the preferred strategy is to use comprehensive testing with different diagnostic modalities when sepsis in mediastinitis is suspected. On the other hand, the relatively higher specificity may explain the tendency of CT not to misdiagnose other postoperative complications as being due to mediastinitis.

References

1. Goodman LR, Kay HR, Teplick SK, Mundth ED. Complications of median sternotomy: computed tomographic evaluation. *AJR* 1983; **141**: 225–30.
2. Jolles H, Henry DA, Roberson JP, Cole TJ, Spratt JA. Mediastinitis following median sternotomy: CT findings. *Radiology* 1996; **201**: 463–6.
3. Misawa Y, Fuse K, Hasegawa T. Infectious mediastinitis after cardiac operations: computed tomographic findings. *Ann Thorac Surg* 1998; **65**: 622–4.
4. Bitkover CY, Cederlund K, Aberg B, Vaage J. Computed tomography of the sternum and mediastinum after median sternotomy. *Ann Thorac Surg* 1999; **68**: 858–63.
5. El Oakley RM, Wright JE. Postoperative mediastinitis: Classification and management. *Ann Thorac Surg* 1996; **61**: 1030–6.
6. Templeton PA, Fishman EK. CT evaluation of poststernotomy complications. *AJR* 1992; **159**: 45–50.
7. Bitkover CY, Gardlund B. Mediastinitis after cardiovascular operations: a case-control study of risk factors. *Ann Thorac Surg* 1998; **65**: 36–40.
8. Loop FD, Lytle BW, Cosgrove DM, et al. Sternal wound complications after isolated coronary artery bypass grafting: early and late mortality, morbidity, and cost of care. *Ann Thorac Surg* 1990; **49**: 179–87.