Original Article

Functional and Perfusional Assessment with Electrocardiograph-gated Single Photon Emission Computed Tomography after Minimally Invasive Direct Coronary Artery Bypass Grafting

Kazuhiko Nishizaki, MD,[1] Yoichi Kameda, MD,[1] Tetsuji Kawata, MD.[1]
Kazumi Mizuguchi, MD,[1] Teruhiko Imai, MD,[2] and Shigeki Taniguchi MD[1]

Background: Because of limited surgical field, minimally invasive coronary artery bypass grafting (MIDCAB) requires anastomosis to the distal portion of the left anterior descending artery (LAD) of the left internal thoracic artery (LITA) with the heart beating. Though the diameters of these arteries are very small, it is unknown whether blood flow sufficient for the LAD territory is obtained by bypass grafting.
Method: Eight patients with single-vessel disease of the LAD underwent MIDCAB with the LITA to the LAD and we evaluated the perfusion and function in the LAD territory by quantitative ECG-gated SPECT (QGS) with 99m-technetium sestamibi (MIBI) before and after operation.
Result: The intraoperatively measured diameters of the LITA and LAD at the site of anastomosis were 1.1±0.2 mm and 1.3±0.4 mm, respectively. The percentage increases in end-diastolic perfusion, regional ejection fraction (EF) and regional wall thickening in the anteroseptal area after MIDCAB were 136.3±11.7(p=0.071), 148.4±6.6(p=0.007) and 133.0±5.6(p=0.029), respectively (paired t-test, mean ± SD %). Stress-rest MIBI SPECT indicated no ischemia in the anteroseptal wall.
Conclusion: The MIDCAB technique thus appeared to improve perfusion and function in the LAD territory despite bypass to the distal LAD, and ECG-gated MIBI SPECT using QGS software was very useful for evaluating the quality of anastomosis after MIDCAB. (Ann Thorac Cardiovasc Surg 2001; 7: 99–102)

Key words: MIDCAB, QGS, SPECT, technetium

Introduction

The number of MIDCAB procedures through a small left anterior thoracotomy has increased in recent years. This technique has mainly been used to anastomose the LITA to the LAD. However, it is difficult to anastomose the LITA to the distal region of a LAD through a small incision. Ideally, every patient should undergo postoperative angiography to check the quality of an anastomosis, but this is not always possible. In addition, it is unknown whether blood flow sufficient for the LAD territory is obtained by bypass grafting. Previous reports on assessment of the quality of anastomosis have indicated the use of intraoperative angiography,[1)] and flow measurement,[2)] or transcutaneous ultrasound evaluation of the LITA.[3)] On the other hand, SPECT with 99m-technetium has recently permitted assessment not only of perfusion but also of ventricular function due to its use of higher energy and QGS software.[4)] However, perfusional and functional assessment and evaluation of the quality of anastomosis both before and after MIDCAB have not been reported yet.

The purposes of this study was to evaluate the perfusion and function in the LAD territory with MIBI QGS before and after MIDCAB in patients who underwent anastomosis of the LITA to the distal LAD through a small left anterior thoracotomy with the heart beating.

From the Departments of [1]Surgery III and [2]Oncoradiology, Nara Medical University, Nara, Japan

Received August 10, 2000; accepted for publication October 24, 2000.
Address reprint requests to Kazuhiko Nishizaki, MD: Department of Surgery III, Nara Medical University, 840 Shijo-cho, Kashihara, Nara 634-8522, Japan.

Patients and Methods

Patients

Between September 1998 and February 2000, forty-three patients underwent single coronary artery bypass grafting (CABG) of the LITA onto the LAD using the MIDCAB technique. Of these patients, eight who had single vessel disease of the LAD and normal sinus rhythm underwent MIBI (Cardiolite Daiichi™, Daiichi Radioisotope Laboratories, Tokyo) ECG-gated SPECT before and after MIDCAB. These patients had severe stenotic LAD with 95% to 99% stenosis. The patients' characteristics are listed in Table 1.

Table 1. Demographic characteristics of patients

Age	67.4 ± 8.5
Gender (male : female)	7 : 1
Prior revascularization	
Percutaneous transluminal coronary angioplasty	5
Conventional coronary artery bypass grafting	2
Coronary risk factors	
Hyperlipidemia	5
Hypertension	6
Diabetes mellitus	2
History of Smoking	5
Prior myocardial infarction	3
Ejection fraction*	0.45 ± 0.12

*Ejection Fraction calculated by ECG gated SPECT imaging

Operative technique

The LITA was harvested in a pedicled fashion with a thoracoscope (Olympus, Tokyo, Japan) up to the upper margin of the first rib. Branches of the LITA were coagulated and divided. A small left anterior thoracotomy was performed in the fourth or fifth intercostal space and the distal LITA was harvested under direct vision through the thoracotomy incision. After opening of the pericardium and systemic heparinization, we transected the LITA and checked the blood flow. The internal diameters of the LITA and LAD were measured, following CABG of the LITA onto the LAD (Segment 8) using the MIDCAB technique. All anastomosis were performed using 7-0 polypropylene monofilament suture using a stabilizer. After the anastomosis, we measured the LITA graft flow and then closed the wound.

SPECT acquisition and processing

A week before and 2 months after the operation, MIBI QGS was performed to evaluate left ventricular function and coronary perfusion. Patients were injected with 4 mCi of MIBI after exercise. Image acquisition was performed 60 minutes after injection using a three-headed system (Multi SPECT 3™, Siemens Co. Ltd.). After reinjection of 12 mCi of MIBI, image acquisition was performed 90 minutes after reinjection. QGS was performed with a temporal resolution of 8 frames per R-R interval. Images were acquired with an ultrahigh-resolution parallel-hole collimator. The camera was rotated over a 120-degree orbit; and 20 projection images per head (1 min / projection) were obtained, resulting in 60 projections over 360-degrees. A 15% window centered on the 140-keV peak was used. The raw MIBI projections were processed with a two-dimensional Butterworth filter with a 0.3 cutoff and an order of 5, and reconstructed with a ramp filter. On the other hand, two patients with unstable angina underwent only rest SPECT using 12 mCi MIBI before the operation.

Data analysis

The regional end-diastolic perfusion, regional ejection fraction (EF), regional wall thickening and global left ventricular EF were automatically calculated using a commercially available software package (ICON, Siemens Co, Ltd.). Polar maps were constructed using the maximal pixel value between the endocardial and epicardial contours. Each polar map of end-diastolic perfusion, regional EF and regional wall thickening was divided into 26 sectors: 3 rings of 8 sectors and 2 sectors for the apex. The LAD territory had 10 sectors including the apex sectors (Fig. 1). For quantification of results, we used an index in which counts in the polar maps were normalized to the maximal counts in the right coronary artery or left circumflex coronary artery territory without stenosis (<25%). The mean index of the LAD territory of the rest MIBI cardiac images was used for further analysis.

Statistical analysis

Results are expressed as mean ± standard deviation unless otherwise indicated. Statistical comparisons of two groups were performed with the paired t-test. Probability values less than 0.05 were considered significant statistically.

Results

Operation

We performed LITA - distal LAD (Segment 8) bypass using MIDCAB technique for eight patients who had

single-vessel disease of the LAD. The diameters of the LITA and LAD at the site of anastomosis were 1.1±0.2 mm and 1.3±0.4 mm, respectively. After bypass grafting, perioperative LITA flow was 12.8±5.66 ml/min. On the next day, we confirmed that each LITA flow of all patients was good with a transcutaneous ultrasound. The postoperative course was uneventful for all patients. One of these patients underwent simultaneous replacement of an abdominal aortic aneurysm.

Image analysis

ECG-gated MIBI SPECT was performed before and after MIDCAB. These MIBI perfusion images were read with the gated SPECT images by two experienced observers blinded to the results of coronary angiography. Postoperative MIBI cardiac images of all patients indicated no ischemia in all regions.

For quantification of results, the counts in the polar maps were normalized to the maximal counts in the territories other than the LAD territory. The quantitative and qualitative score data for end-diastolic perfusion, regional EF, regional wall thickening and global left ventricular EF were listed in Table 2. All indices were higher postoperatively than preoperatively. The increase rates were 136.3±11.7%, 148.4±6.6%, 133.0±5.6%, and 100.4±5.6%, respectively. In particular, regional EF and regional wall thickening were significantly higher postoperatively.

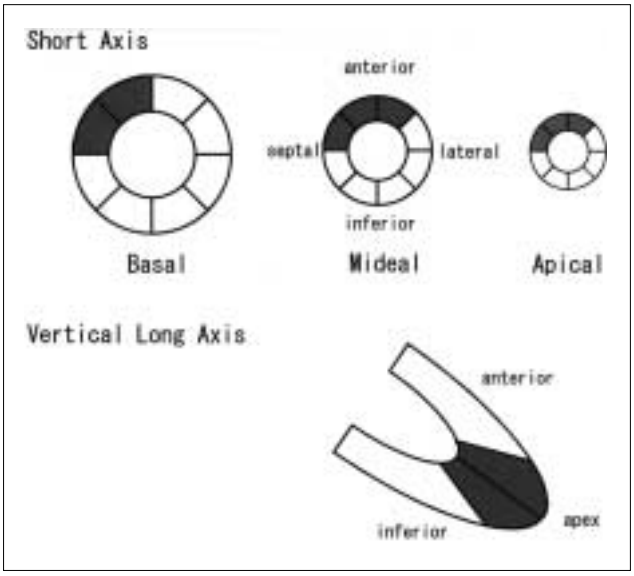

Fig. 1. Example of ^{99m}Tc sestamibi (MIBI) polar map. Solid sectors are the territory of left anterior descending artery (LAD). There is a known 1:1 correspondence between sectors in the polar map and sectors in the delineated left ventricular wall. The mean value of this region was used for further analysis

Discussion

Compared with conventional CABG, MIDCAB requires a difficult anastomotic technique, because the LITA and LAD of the distal portion are very small and the heart is beating within a limited small surgical field. On the other hand, it is unknown whether perfusion obtained is sufficient to supply the territory of the LAD and whether LV function in the LAD territory is improved postoperatively. In this study, we demonstrated with MIBI ECG-gated SPECT that even if the site of anastomosis of the LAD and LITA was located distally, MIDCAB improved perfusion and function in the territory of the LAD.

A previous study evaluated the quality of anastomosis of the LITA and LAD by measurement of LITA flow[2)] as well as coronary angiography. These assessments may reveal the quality of anastomosis, but even if the quality of anastomosis is excellent, it is unknown whether this bypass supplies blood flow sufficient for the LAD territory. In some cases, the anastomosis in the distal portion of coronary arteries in which diameters are very small may be necessary. In our patients, the diameters of the

Table 2. The preand postoperative regional ED perfusion, regional EF, wall thickening and global LVEF calculated by QGS

	Index (%)		Increase rate (%)	p value
	Preoperation	Postoperation		
Regional ED perfusion	80.7 ± 13.9	93.4 ± 26.3	138.3 ± 13.5	0.071
Regional EF	61.8 ± 26.0	74.5 ± 27.2	149.4 ± 8.7	0.007*
Regional wall thickness	87.3 ± 35.5	91.0 ± 31.5	133.5 ± 6.6	0.029*
	Preoperation	Postoperation	Increase rate (%)	p value
Global LVEF	0.45 ± 0.12	0.53 ± 0.14	101.6 ± 6.4	0.085

ED: end-diastolic, EF: ejection fraction, LVEF: left ventricular ejection fraction, QGS: quantitative ECG-gated, *p<0.05.

LITA and LAD at the site of anastomosis were 1.1±0.2 mm and 1.3±0.4 mm, respectively. In addition to this, stress-rest MIBI SPECT indicated no ischemia in the anteroseptal wall. Therefore it appeared that MIBI ECG-gated SPECT showed sufficient perfusion of the LAD territory after MIDCAB in spite of anastomosis of small vessels in the distal portion of the LAD. Previously, it was reported that the internal mammary artery graft is a "live" conduit with potential for growth and adaptation.[5,6] Though our postoperative QGS were performed two months after the operation, these indices might show even more recovery if postoperative QGS was performed a year or more after the MIDCAB.

The prognostic value of ^{201}Tl myocardial perfusion imaging for detecting coronary artery disease is well-established.[7] On the other hand, 99m-technetium myocardial perfusion imaging has recently come into use because the shorter half-life of 99m-technetium allows administration of higher doses which, along with the higher intrinsic energy of 99m-technetium, provide images superior to those obtained with ^{201}Tl imaging. The diagnostic accuracy of MIBI imaging for detection of coronary artery diseases has been shown to be comparable to that with ^{201}Tl.[8,9] The higher count rates obtained with MIBI allow image acquisition in a gated frame mode and analysis of regional and global ventricular function. ECG-gated SPECT using MIBI can evaluate not only perfusion but also function in regions of interest.[4] In addition, MIBI myocardial perfusion imaging with exercise testing provides important prognosis information. Normal MIBI cardiac imaging predicts a very low cardiac event rate.[10-12] Therefore this technique is very useful for evaluating left ventricular perfusion and function before and after MIDCAB.

Findings of MIBI QGS assessment can predict whether anastomoses are both patent and non-restrictive, limiting the requirement for postoperative angiography. In conclusion, even if anastomosis of the LAD and LITA with MIDCAB technique is performed in the distal portion, regional perfusion and regional function in the territory of the LAD are improved. MIBI QGS assessment is a reliable technique for follow-up of patients who have undergone MIDCAB. With it, the requirement for postoperative angiography will be reduced, costs will be contained, and patient comfort will be increased.

Acknowledgment

We gratefully thank Ms. Etsuko Murakami and Mr. Hirokazu Okada for their technical assistance.

References

1. Barstad RM, Fosse E, Vatne K, et al. Intraoperative angiography in minimally invasive direct coronary artery bypass grafting. *Ann Thorac Surg* 1997; **64**: 1835–9.
2. Calafiore AM, Gallina S, Iaco A, et al. Minimally invasive mammary artery Doppler flow velocity evaluation in minimally invasive coronary operations. *Ann Thorac Surg* 1998; **66**: 1236–41.
3. Gupta S, Murgatroyd F, Widenka K, Spyt TJ, De Bono DP. Role of transcutaneous ultrasound in evaluation of graft patency following minimally invasive coronary surgery. *Eur J Cardiothorac Surg* 1998; **14** (suppl 1): 88–92.
4. Germano G, Erel J, Lewin H, Kavanagh PB, Berman DS. Automatic quantitation of regional myocardial wall motion and thickening from gated technetium-99m sestamibi myocardial perfusion single-photon emission computed tomography. *J Am Coll Cardiol* 1997; **30**: 1360–7.
5. Kitamura S, Seki T, Kawachi K, et al. Excellent patency and growth potential of internal mammary artery grafts in pediatric coronary artery bypass surgery. New evidence for a "live" conduit. *Circulation* 1988; **78**: I129–39.
6. Kitamura S, Kawachi K, Seki T, et al. Bilateral internal mammary artery grafts for coronary artery bypass operations in children. *J Thorac Cardiovasc Surg* 1990; **99**: 708–15.
7. Brown KA. Prognostic value of thallium-201 myocardial perfusion imaging: a diagnostic tool comes of age [see comments]. *Circulation* 1991; **83**: 363–81.
8. Levine MG, McGill CC, Ahlberg AW, et al. Functional assessment with electrocardiographic gated single-photon emission computed tomography improves the ability of technetium-99m sestamibi myocardial perfusion imaging to predict myocardial viability in patients undergoing revascularization. *Am J Cardiol* 1999; **83**: 1–5.
9. Taillefer R, DePuey EG, Udelson JE, Beller GA, Latour Y, Reeves F. Comparative diagnostic accuracy of Tl-201 and Tc-99m sestamibi SPECT imaging (perfusion and ECG-gated SPECT) in detecting coronary artery disease in women. *J Am Coll Cardiol* 1997; **29**: 69–77.
10. Soman P, Parsons A, Lahiri N, Lahiri A. The prognostic value of a normal Tc-99m sestamibi SPECT study in suspected coronary artery disease. *J Nucl Cardiol* 1999; **6**: 252–6.
11. Iskander S, Iskandrian AE. Risk assessment using single-photon emission computed tomographic technetium-99m sestamibi imaging. *J Am Coll Cardiol* 1998; **32**: 57–62.
12. Raiker K, Sinusas AJ, Wackers FJ, Zaret BL. One-year prognosis of patients with normal planar or single-photon emission computed tomographic technetium 99m-labeled sestamibi exercise imaging. *J Nucl Cardiol* 1994; **1**: 449–56.