

Two Cases of Off-pump Coronary Artery Bypass Grafting Combined with Abdominal Aortic Aneurysm Repair

Shigeki Tabata, MD, Yoshiharu Tomita, MD, Makoto Tsubota, MD,
and Masahiro Seki, MD

Two cases of coronary artery disease coexisting with abdominal aortic aneurysm (AAA) were treated with off-pump coronary artery bypass grafting (CABG) combined with repair of the aneurysm. The first patient was a 67-year-old man exhibiting a large pulsating abdominal mass. Abdominal computed tomography demonstrated a 9-cm aneurysm and coronary angiogram revealed a 90% stenosis of the obtuse marginal branch for which percutaneous transluminal coronary angioplasty (PTCA) could not be performed. He underwent simultaneous single CABG coronary without cardiopulmonary bypass, and bifurcated graft replacement. The second patient was a 71-year-old man who had acute myocardial infarction, and one month later underwent coronary angiogram which revealed three vessel disease in the coronary artery. Computed tomography revealed a 4-cm aneurysm, and angiography showed a 90% stenosis of the left renal artery. He underwent a single stage operation that involved three CABGs without cardiopulmonary bypass, straight graft replacement, and reconstruction of the left renal artery using the saphenous vein graft. The postoperative course was uneventful in both cases. We currently recommend a single stage operation involving off-pump CABG. (Ann Thorac Cardiovasc Surg 2001; 7: 254–7)

Key words: off-pump CABG, abdominal aortic aneurysm repair

Introduction

Coronary artery bypass grafting (CABG) without cardiopulmonary bypass (Off-pump CABG, OPCAB) with median sternotomy has recently become a common procedure due to the development of new techniques for coronary artery exposure¹⁾ and for target vessel stabilization.²⁻⁴⁾ We report two cases of simultaneous OPCAB and abdominal aortic aneurysm (AAA) repair.

Method

After a median laparotomy was made and AAA was dissected to prevent oozing by heparinization, a median ster-

notomy was performed and grafts were harvested. After intravenous administration of heparin (100 IU/kg), the grafts were anastomosed under local vascular occlusion with 7-0 or 8-0 polypropylene sutures. Octopus II stabilizer (Medtronic Inc, Minneapolis, MN) was used to stabilize the target arteries. For the circumflex territory, the patient was placed in the Trendelenburg position and rotated rightward, and using the strategy proposed by Lima, three stay sutures were positioned deep in the pericardium, and pulled up.¹⁾ If hemodynamics were unstable, pericardial counterincision to create heart herniation through the right chest was used.

Case Reports

Case 1

Abdominal computed tomography (CT) scan of a 67-year-old man exhibiting a large pulsating abdominal mass revealed a 9-cm infrarenal AAA (Fig. 1). Coronary angiogram revealed a 90% stenosis of the obtuse marginal (OM) branch for which percutaneous transluminal coro-

From the Department of Cardiovascular Surgery, Ishikawa Prefectural Central Hospital, Kanazawa, Japan

Received December 1, 2000; accepted for publication March 19, 2001.

Address reprint requests to Shigeki Tabata, MD: Department of Cardiovascular Surgery, Kanazawa Cardiovascular Hospital, 16-Ha, Tanaka-machi, Kanazawa 920-0007, Japan.

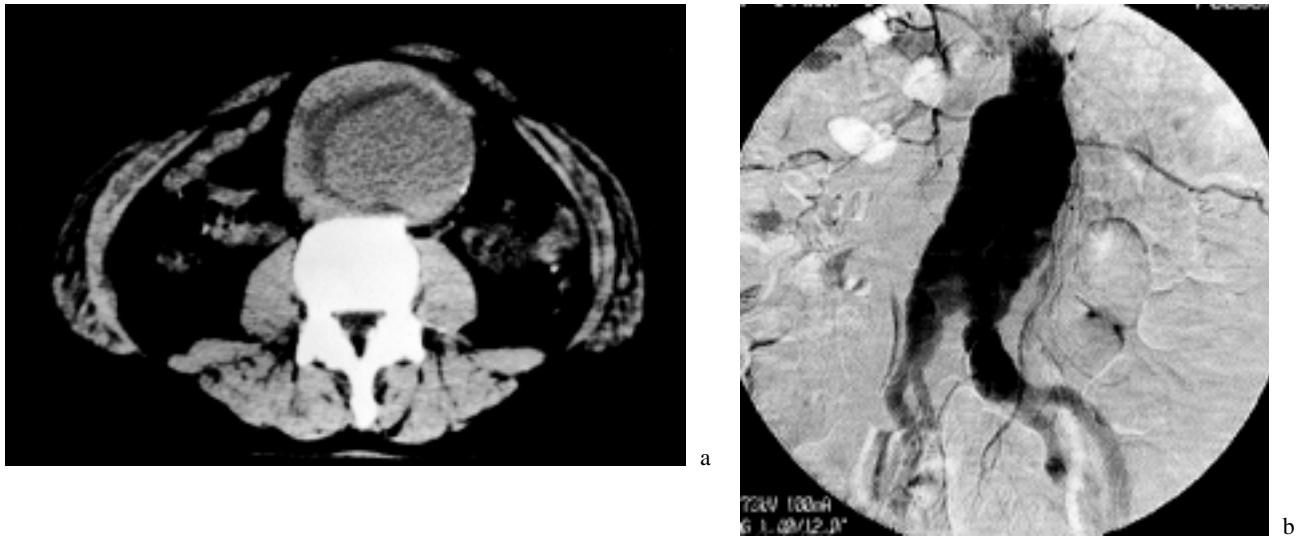


Fig. 1. Aortogram (a) and computed tomography (CT) (b) in case 1. CT reveals a 9-cm AAA.

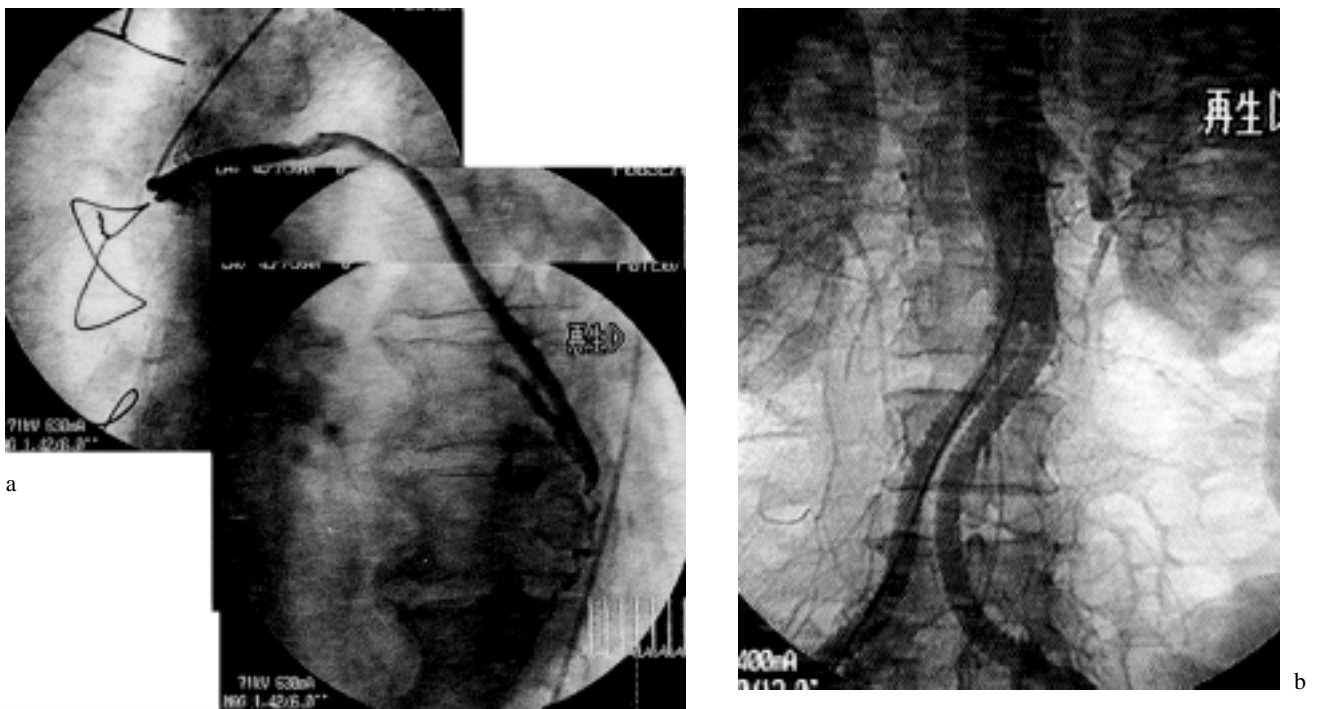

Fig. 2. Postoperative coronary angiography (CAG) showing the excellent patency of the saphenous vein graft (SVG).

nary angioplasty (PTCA) could not be performed, for anatomical reasons.

On October 15, 1999, the patient underwent simultaneous OPCAB and AAA repair. As described above, a median laparotomy was performed, and anastomosis of a saphenous vein (SV) graft to the OM was performed. Concomitantly, bifurcated graft replacement of the aorta was performed. The endotracheal tube was extubated 10 hours postoperatively. His postoperative course was un-

eventful (Fig. 2), and he was ambulatory on discharge.

Case 2

A 71-year-old man with multivessel disease of the coronary artery and AAA was admitted to our department for operation. At 65 years of age, he had undergone a sigmoidectomy for cancer of the sigmoid colon. On November 22, 1999, he had acute myocardial infarction and received direct PTCA with stent for the right coronary

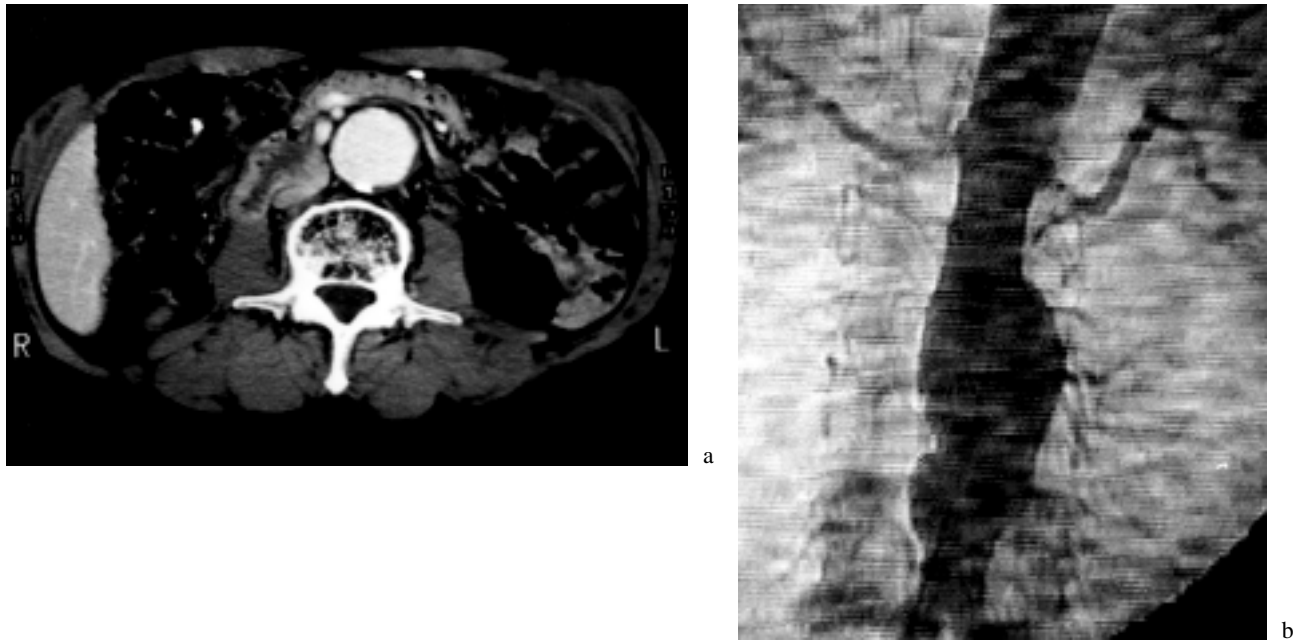


Fig. 3. Angiogram (a) and computed tomography (CT) (b) in case 2. Angiogram reveals a 90% stenosis of the left renal artery.

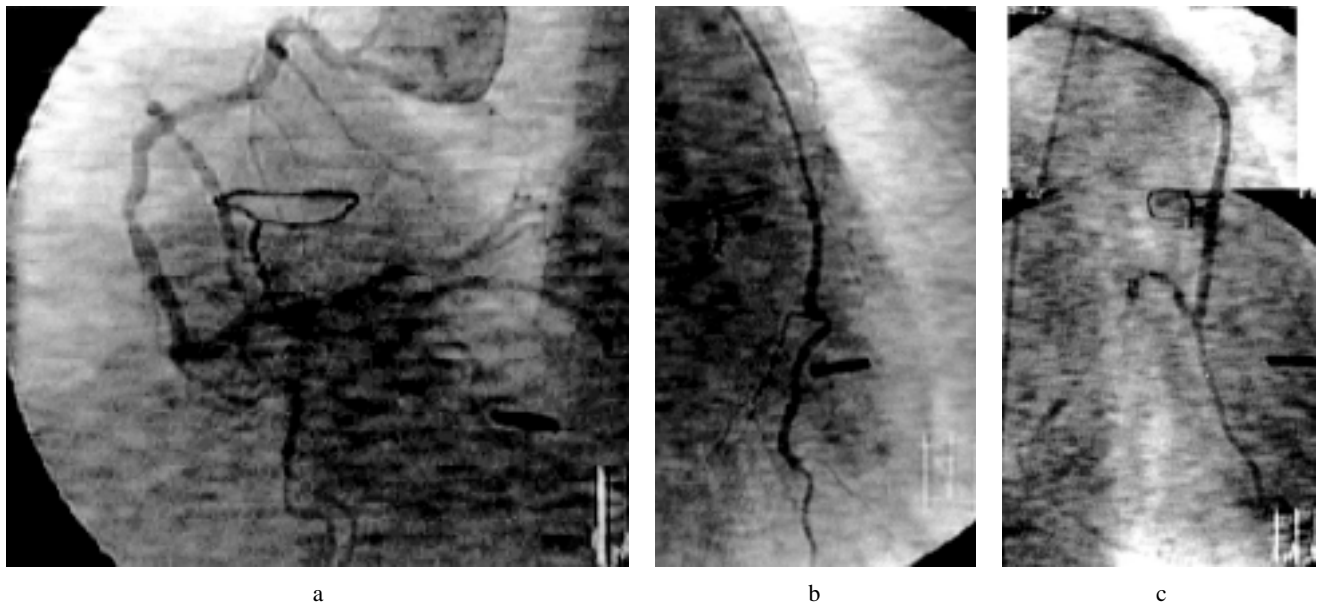


Fig. 4. Postoperative coronary angiography (CAG). All of the grafts, the gastroepiploic artery (GEA) graft (a), the left internal thoracic artery (LITA) graft (b), and the SVG (c) are clearly patent.

artery (RCA). One month later, coronary angiogram revealed 75% stenosis of the proximal left anterior descending artery (LAD), 90% stenosis of the postrolateral (PL) branch and 75% stenosis of RCA. Abdominal CT scan revealed a 4-cm infrarenal AAA (Fig. 3a), and angiography showed a 90% stenosis of the left renal artery (Fig. 3b).

On February 14, 2000, he underwent simultaneous OPCAB and AAA repair. As described above, a median laparotomy was performed, and the right gastroepiploic

artery (GEA) was harvested. A median sternotomy was performed and the left internal thoracic artery (LITA) was harvested. After intravenous administration of heparin (100 IU/kg), we performed three coronary artery bypass graftings (the LITA-LAD, SV graft-PL branch, and the right GEA-RCA) (Fig. 4). Concomitantly, we performed straight graft replacement of the aorta. Finally, the bypass graft between the straight graft and the left renal artery was placed using an SV graft (Fig. 5). The

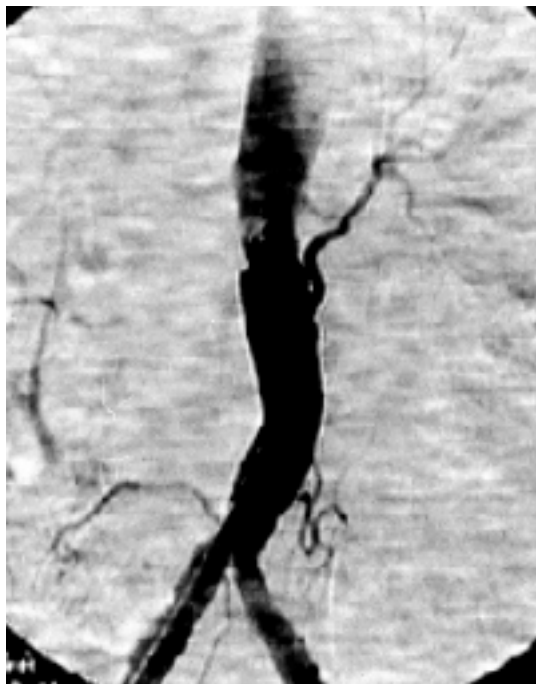

Fig. 5. Postoperative aortogram reveals good patency of the straight graft and the SVG to the left renal artery.

endotracheal tube was removed 12 hours after operation. The patient has had a satisfactory postoperative course.

Discussion

Abdominal aortic aneurysm and coronary artery disease (CAD) have high incidences of coexistence. Surgical strategy for coronary artery disease coexisting with AAA has been controversial. Treatment options available can be staged repair of AAA following CABG or combined CABG and AAA repair.

In some of the cases, the conventional CABG is carried out first, followed later by elective AAA repair. However, it was documented that 11% to 33% of patients who underwent CABG prior to AAA repair died due to aneurysm rupture.^{5,6} Blackbourne et al.⁶ reported that patients with surgically correctable CAD and an AAA 5 cm or greater in diameter should undergo coronary revascularization followed by AAA repair within 2 weeks.

Several studies have shown that a single operation for conventional CABG followed by AAA repair is a safe and effective procedure.⁶⁻¹⁰ King et al.¹⁰ reported that the use of a single stage operation not only eliminates the risk of aneurysm rupture, but also avoids the risk of

repeated anesthesia in a population with high operation risk, limits the risk of embolic catastrophe associated with cross-clamping the severely diseased aorta, and decreases patient discomfort. Nevertheless, the conventional procedure has a marked problem due to the use of cardiopulmonary bypass (CPB); it is well known that CPB induces inflammatory reactions and hematologic disorders.

In recent years, as new techniques for coronary artery exposure¹ and for target vessel stabilization²⁻⁴ have developed, OPCAB has become a common procedure. In the cases of CAD coexisting with AAA, we recommend a single stage operation involving OPCAB.

References

1. Calafiore AM, Teodori G, Giammarco GD, et al. Multiple arterial conduits without cardiopulmonary bypass: early angiographic results. *Ann Thorac Surg* 1999; **67**: 450-6.
2. Boonstra PW, Grandjean JG, Mariani MA. Local immobilization of the left anterior descending artery for minimally invasive coronary bypass grafting. *Ann Thorac Surg* 1997; **63**: S76-8.
3. Takahashi M, Yamamoto S, Tabata S. Immobilized instrument for minimally invasive direct coronary artery bypass: MIDCAB doughnut. *J Thorac Cardiovasc Surg* 1997; **114**: 680-2.
4. Jansen EWL, Lahpor JR, Borst C, Grüdeman PF, Bredée JJ. Off-pump coronary bypass grafting: how to use the octopus tissue stabilizer pump. *Ann Thorac Surg* 1998; **66**: 576-9.
5. Durham SJ, Steed DL, Moosa HH, Makaroun MS, Webster MW. Probability of rupture of an abdominal aortic aneurysm after an unrelated operative procedure: a prospective date. *J Vasc Surg* 1991; **13**: 248-52.
6. Blackbourne LH, Tribble CG, Langenburg SE, et al. Optimal timing of abdominal aortic aneurysm repair after coronary artery revascularization. *Ann Surg* 1994; **219**: 693-8.
7. David TE. Combined cardiac and abdominal aortic surgery. *Circulation* 1985; **72** (suppl 2): 18-21.
8. Ruby ST, Whittemore AD, Cough NP, et al. Coronary artery disease in patients requiring abdominal aortic aneurysm repair. *Ann Surg* 1985; **201**: 758-64.
9. Westaby S, Parry A, Grebenik CR, Pillai R, Lamont P. Combined cardiac and abdominal aortic aneurysm operations: the dual operation on cardiopulmonary bypass. *J Thorac Cardiovasc Surg* 1992; **104**: 990-5.
10. King RC, Parrino PE, Hurst JL, Shockey KS, Tribble CG, Kron IL. Simultaneous coronary artery bypass grafting and abdominal aneurysm repair decrease stay and costs. *Ann Thorac Surg* 1998; **66**: 1273-6.