Case Report

Subtotal Thoracic Aortic Replacement as Reoperation for Ruptured Aortic Dissection: Report of a Case

Kazuo Yamamoto, MD, Shigetaka Kasuya, MD, Satoshi A. Tanaka, MD, Okihiko Akashi, MD, and Fumiaki Oguma, MD

We report successful repair of a ruptured chronic aortic dissection in a 63-year-old female who had undergone end-to-end anastomosis for acute type A dissection 8 years before. The patient had hypotension with back pain and cough. A computed tomogram revealed a large chronic aortic dissection (Stanford type A) and complete atelectasis of the left lung due to hemothorax. The brachiocephalic artery was also dissected and aneurysmal. Emergency surgery was performed. Subtotal thoracic aortic replacement with reconstruction of 4 cervical vessels was carried out using hypothermic circulatory arrest with selective cerebral perfusion via a redo-sternotomy and a left anterolateral thoracotomy. The patient was discharged from the hospital without any sequelae. (Ann Thorac Cardiovasc Surg 2001; 7: 319–22)

Key words: aortic dissection, subtotal thoracic aortic replacement, ruptured aortic dissection, reoperation

Introduction

Emergency surgery for acute type A aortic dissection is generally a palliative procedure aimed at preventing blood flowing into the pericardium due to rupture of the aorta, and evolving dissected aneurysmal formation or recurrence of the dissection is therefore a common complication. Although a reoperation for aortic dissection is not rare, there have been few reports of an extensive reoperation for a ruptured chronic aortic dissection. We herein report a successful subtotal thoracic aortic replacement for a patient with a ruptured aortic dissection who had previously undergone end-to-end anastomosis.

Case Report

A 63-year-old female who had undergone reinforcement of a dissected ascending aorta and end-to-end anastomosis[1)] for acute type A aortic dissection 8 years before was admitted to a local hospital due to back pain and cough. Since a chest X-ray showed left pleural effusion, treatment for pleuritis was first performed. After a few days, she was transferred to our department because of dyspnea with anemia (hemoglobin, 8.2 g/dL) and severe hypotension (systolic blood pressure, 40-50 mmHg), which necessitated the use of intravenous inotropics. A chest X-ray showed left hemothorax (Fig. 1). A computed tomogram revealed chronic aortic dissection from the ascending aorta to its bifurcation (type A dissection; maximum diameter, 9.5 cm; Fig. 1) and left hemothorax. Most of thoracic aorta was markedly enlarged. Emergency surgery was performed. Redo-sternotomy was done after the beginning of a partial cardiopulmonary bypass (femorofemoral bypass and right axillary artery cannulation), because of tight compression of the dissected ascending aorta to the sternum. The superior vena cava was also cannulated, and the pulmonary artery was vented. Left anterolateral thoracotomy was added to manipulate the lower part of the descending thoracic aorta. When the bladder temperature reached 21°C, circulation was arrested. After the ascending aorta and arch had been incised, selective cerebral perfusion (SCP) was commenced and myocardial protection was achieved by selective antegrade cold blood cardioplegia. SCP flow was maintained via the right axillary artery cannulation

From the Department of Cardiovascular Surgery, Tachikawa General Hospital, Nagaoka, Japan

Received January 29, 2001; accepted for publication April 11, 2001.
Address reprint requests to Kazuo Yamamoto, MD: Department of Cardiovascular Surgery, Tachikawa General Hospital, 3-2-1 Kandamachi, Nagaoka 940-8621, Japan.

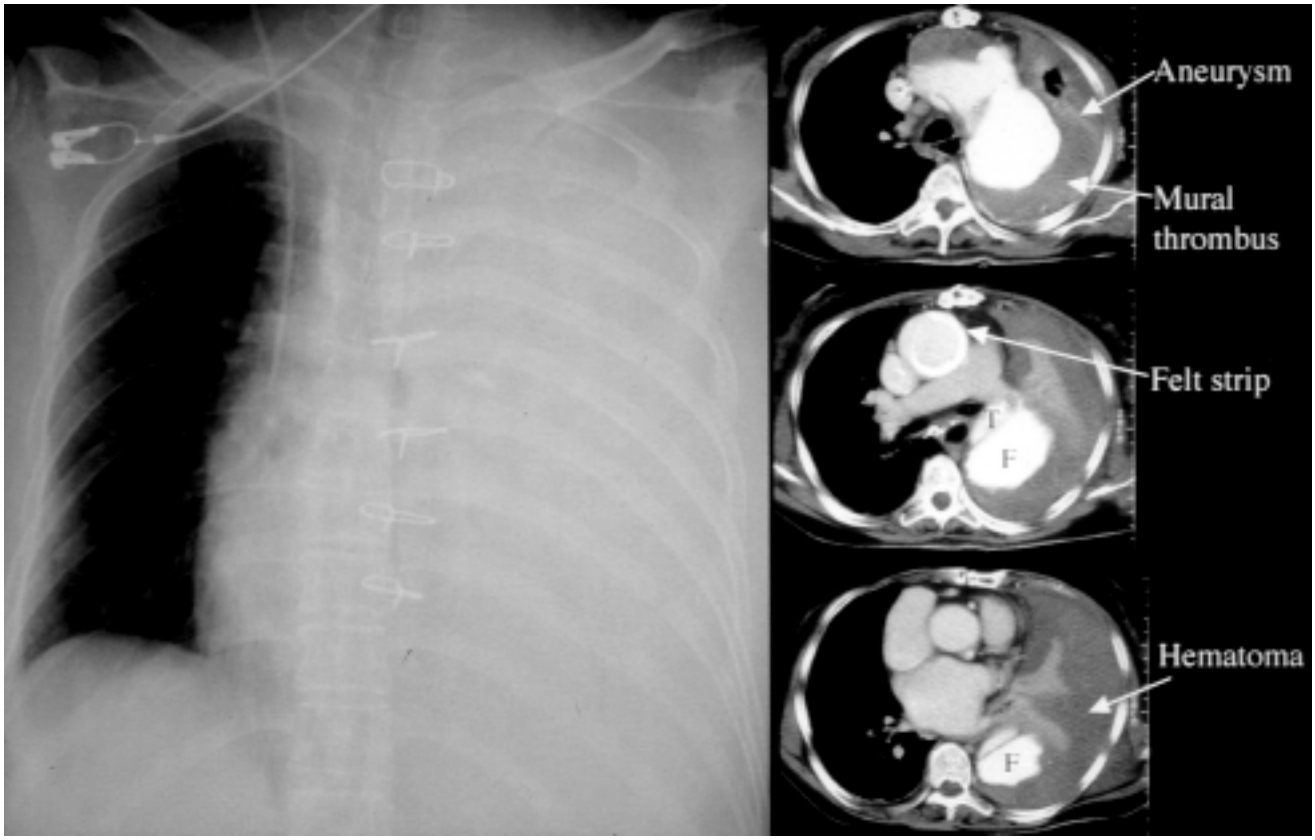

Fig. 1. a: Chest X-ray showing massive left hemothorax.
b: CT image of a large aortic dissection from the ascending aorta to the descending aorta.
c: CT image of Dacron felt strips at the ascending aorta used in previous surgery.
d: CT image of the dissecting descending aorta and hemorrhage in the left pleural space.

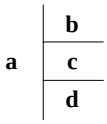

and a balloon catheter inserted in the left common carotid artery (total flow: 500 ml/min). Perfusion pressure of SCP was not monitored in this emergency operation. The brachiocephalic artery was clamped distally. A distal anastomotic site of the descending aorta (about 4.2 cm in diameter) several centimeters above the diaphragm was selected. The distal anastomosis was located almost at the level of Th9. After resection of a portion of the dissecting membrane, distal anastomosis was performed by the double-barreled procedure using a branched woven Dacron graft (Hemashield™ 28/10/8/8×10 mm, Meadox Medicals, Oakland, NJ, USA) during circulatory arrest. The graft was passed through the dissected descending thoracic aorta because of tight and wide adhesion of the left lung to the aorta. Vagus and phrenic nerves were preserved. An intimal tear was present in the lesser curvature of the aortic arch. The rupture site was present in the proximal descending thoracic aorta. After the left subclavian artery had been reconstructed, proximal anastomosis was performed at the level of the sino-tubular junction. The graft was unclamped and the heart was defibrillated. The left common carotid artery was reconstructed, and this was followed by individual reconstruction of the right common carotid artery and the right subclavian artery because of the presence of a dissected aneurysmal formation of the brachiocephalic artery. Circulatory arrest time, cardiopulmonary bypass time, and operation time was 35, 274, and 475 min, respectively.

Postoperative hemorrhage required re-exploration of the left chest. The patient was extubated on postoperative day 9 because of prolonged hypoxia due to reperfusion lung edema. No brain damage or spinal injury occurred. Postoperative CT and angiography (Fig. 2) results were satisfactory, and the patient was discharged on postoperative day 44 without any sequelae.

Discussion

The majority of late deaths following primary surgery

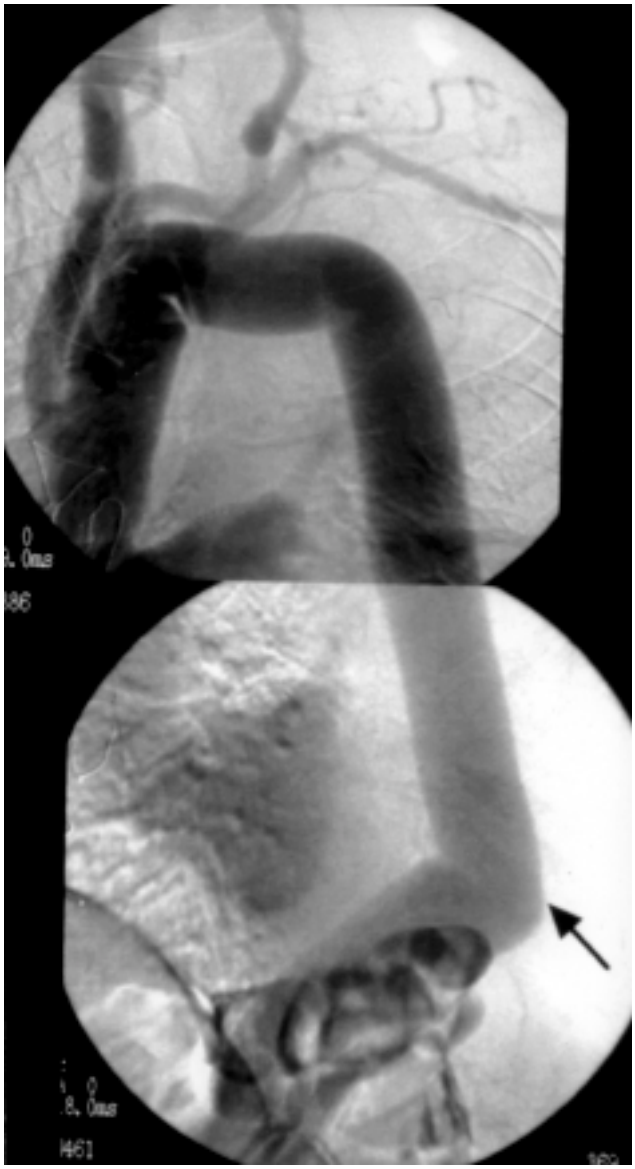

Fig. 2. Postoperative subtraction angiogram showing reconstructed thoracic aorta and cervical vessels. The arrow shows the distal anastomotic site.

for an aortic dissection have been due to rupture of the aorta.[2] In DeBakey et al.'s large series,[3] 5%, 32%, and 57% of patients who had survived died at 5, 10, and 20 years after primary surgery, respectively. The rates of reoperation for type A dissection have been reported to be from 13 to 25% within 5 years after the first operation and from 21 to 40% within 10 years.[3-5] Although a reoperation for an aortic dissection is not rare, extensive repair of a ruptured aortic dissection, such as that performed in our patient from the ascending aorta to the descending aorta, is uncommon.

Reoperations are technically demanding. Borst et al. stated the mortality rate of reoperation for type A dissection varied between 10% to 50%, depending on, among other general factors, the acuity of the disease and the aortic portion affected.[2] The highest mortalities occurred in cases involving the arch and the thoracoabdominal aorta. In our patient, subtotal thoracic aortic replacement including the arch was inevitable, but combined repair of the thoracoabdominal aorta could be avoided. The distal anastomotic site was also mildly dilated, and anastomosis using the open distal method was not so difficult.

Murashita et al. reported a successful extensive (from the ascending aorta to the supraceliac abdominal aorta) replacement for a chronic dissecting aneurysm performed by both a median sternotomy and a thoracoabdominal approach.[6] We used a left anterolateral thoracotomy in addition to a redo-sternotomy. In our emergency reoperation, the combination of a median sternotomy and a thoracoabdominal approach would have been too invasive for the seriously ill patient. Antegrade blood stream via the right axillary artery cannulation prevented thromboembolism in the patient who had lots of mural thrombi in the descending thoracic aorta. Although the brachiocephalic artery was aneurysmal and dissected, blood flow via the right axillary artery cannulation was safe because the dissection was chronic and stable. For prevention of left lung injury, manipulation of the descending thoracic aorta was done from the left side. Because the distal part of the descending thoracic aorta was also dissected and mildly dilated, open distal anastomosis using circulatory arrest was advantageous. It was not considered necessary to reconstruct intercostal arteries (ICAs) because the ICAs below Th9 were preserved in this procedure. Since the left lung, especially the upper lobe portion was severely adhered to the descending thoracic aorta and thoracic wall, the prosthetic graft was passed through the dissected thoracic aorta instead of lysing and incising the aorta. This procedure prevented catastrophic lung injury and saved operative time. The use of circulatory arrest with deep hypothermia and open distal, double-barreled anastomosis was very useful in this patient. Selective cerebral perfusion and the use of a branched graft were also helpful.

In conclusion, an emergency reconstruction of the subtotal thoracic aorta was successfully performed on a patient with a ruptured aortic dissection who had undergone end-to-end anastomosis eight years before. A comprehensive strategy, including an antegrade perfusion for prevention of thromboembolism, manipulation from the left side during distal anastomosis, the use of the open

distal technique with hypothermia and selective cerebral perfusion, and the no-touch technique for severe lung adhesion to the dissected aorta, seemed to contribute to the successful outcome.

References

1. Koster JK Jr, Cohn LH, Mee RB, Collins JJ Jr. Late results of operation for acute aortic dissection producing aortic insufficiency. *Ann Thorac Surg* 1978; **26**: 461–7.
2. Borst HG, Heinemann MK, Stone CD. Reoperations of aortic dissection. In: Borst HG, Heinemann MK, Stone CD eds.; Surgical Treatment of Aortic Dissection. New York: Churchill Livingston Inc, 1996; pp 321–37.
3. DeBakey ME, McCollum CH, Crawford ES, Morris GC Jr. Dissection and dissecting aneurysms of the aorta: twenty-year follow-up of five hundred twenty-seven patients treated surgically. *Surgery* 1982; **92**: 1118–34.
4. Haverich A, Miller DC, Scott WC, et al. Acute and chronic aortic dissections-determinants of long-term outcome for operative survivors. *Circulation* 1985; **72** (suppl II): 22–34.
5. Bachet J, Brizard Ch, Goudot B, et al. Repeated surgery for recurrent dissection of the aorta. *Eur J Cardiothorac Surg* 1990; **4**: 238–44.
6. Murashita T, Yasuda K, Shiiya N, Sakai S, Sakuma M. Extensive replacement of the aorta from the ascending aorta to the supraceliac abdominal aorta during a one-stage operation. *Surgery Today* 1997; **27**: 368–72.