Original Article

Bronchopleural Fistula in the Surgery of Non-small Cell Lung Cancer: Incidence, Risk Factors, and Management

Horia Sirbu, MD, FETCS, Thomas Busch, MD, PhD, I. Aleksic, MD, FETCS, W. Schreiner, MD, O. Oster, MD, and H. Dalichau, MD, FETCS

Background: The incidence of a bronchopleural fistula (BPF) as a major complication after non-small cell lung carcinoma (NSCLC) surgery has decreased in recent years, due to new surgical refinements and a better understanding of the bronchial healing process. We reviewed our most recent experience with BPFs and tried to determine methods which may effectively reduce its occurrence.

Methods: Data on 490 patients with lung resections for NSCLC over a period from 1990 to 1999 were retrospectively reviewed. Details regarding surgery and the subsequent treatment were carefully reviewed. Particular attention was paid to factors possibly affecting the occurrence of BPFs: the technique of the initial bronchial closure, previous radiation and/or chemotherapy, need for postoperative ventilation and presence of residual carcinomatous tissue at the bronchial suture line. Information about age, sex, clinical diagnosis, associated conditions, TNM stage, period between primary operation and rethoracotomy and postoperative outcome was also recorded.

Results: The overall BPF incidence was 4.4% (22/490). There were 21 (95.5%) males and 1 (4.5%) female, mean age was 57.8 years. BPFs occurred after pneumonectomy in 12 (54.6%), after lobectomy in 9 (40.9%) patients and after sleeve resections in 1 (4.5%) patient. Mortality rate was 27.2% (6/22). Right-sided pneumonectomy and postoperative mechanical ventilation were identified as risk factors for BPFs ($p<0.05$). Initial chest re-exploration was performed in 20 (90.9%) patients. After debridement, the bronchial stump was reclosed by hand suture in 10 (45.4%) patients. All 10 (45.4%) patients with a post-lobectomy- and sleeve resection BPF necessitated completion surgery. The BPF was additionally covered with a vascularized flap in 20 (90.9%) patients. In 2 (9%) patients with small BPFs and poor overall condition the initial treatment was endoscopic. In both the fistula persisted and the stump had to be surgically resutured.

Conclusions: A BPF remains a major complication in the surgery of NSCLC because of its high mortality and morbidity rate. A BPF is more common after right-sided pneumonectomy and is frequently associated with postoperative mechanical ventilation. The management varies according to the initial type of surgery, the size of the BPF, the overall patient condition and that of the remaining lung. Endoscopic treatment is reserved only for small fistulas associated with poor general condition. (Ann Thorac Cardiovasc Surg 2001; 7: 330–6)

Key words: bronchopleural fistula, rethoracotomy, postoperative complications, bronchial stump insufficiency

From the Department of Thoracic and Cardiovascular Surgery, Georg-August University, Göttingen, Germany

Received February 14, 2001; accepted for publication May 29, 2001.

Address reprint requests to Horia Sirbu MD, FETCS: Klinik für Thorax-, Herz- und Gefäßchirurgie, Georg-August-Universität Göttingen, Robert Koch Straße 40, D-37075 Göttingen, Germany

Introduction

Bronchopleural fistula (BPF) is the most dreaded complication after pulmonary resection for non-small cell lung carcinoma (NSCLC). The incidence of BPF has decreased in the past decades with a better understanding of the bronchial healing process, refinements of bron-

chial surgical techniques and advances in postoperative intensive care.[1] Despite a widespread understanding of these surgical principles the latest reported incidence of BPFs is still high and varies from 1.5% to 11.1%.[2,3]

Over the last few years we have noticed an increasing number of extensive operative procedures for NSCLC.[1,2] Present advances in radio- and chemotherapy make down staging of advanced NSCLC possible to stages where surgery can safely be performed.[3,4] The risk of postoperative major complications in this group of patients is high because they are older, often present with extended local disease and/or iatrogenic induced pathology. Therefore the occurrence of BPFs is still associated with high mortality rates ranging from 25% to 71.2%, the most common cause of death being aspiration pneumonia with subsequent acute respiratory distress syndrome (ARDS).[1,3,5] This might be explained with new factors interfering in the bronchial stump healing process, factors not seen previously in the tuberculosis era.[3]

From our own case material we sought to review the experience with this major complication in order to establish the reasons for and thus find out how such problems might become avoidable.

Material and Methods

Between January 1990 to June 1999, 565 patients underwent various lung resections for the surgical therapy of NSCLC at the University of Göttingen. Only 490 patients were included in this study. 75 patients where excluded because of incomplete records and/or follow-up, surgery for small-cell carcinoma, carcinoid tumor and exploratory thoracotomy. Of these 490 patients, 165 had undergone pneumonectomies, 305 bi-lobectomies, 15 sleeve resections, and 5 wedge resections. Mean age was 57.8 years (range 22-86). We reviewed the hospital records of all these patients. NCSLC was diagnosed histologically and staged according to the New International Staging System for Lung Cancer and after 1997 re-staged according to revisions in the International System.[6]

Details regarding the type and method of surgery and the subsequent treatment were carefully reviewed for each patient. Particular attention was paid to factors possibly affecting the occurrence of BPFs: technique of initial bronchial closure, extent of lymphadenectomy, previous radiation and/or chemotherapy, need for postoperative ventilation and presence of residual carcinomatous tissue at the bronchial suture line. Information about age, sex, clinical diagnosis, associated conditions (diabetes mellitus, corticotherapy, tuberculosis, or liver disease), preoperative TNM stage, period between primary operation and rethoracotomy and postoperative outcome was also recorded.

Surgical technique

The surgical therapy of NCSLC consisted of lobectomy, pneumonectomy and/or sleeve resection followed by a systematic extensive hilar and mediastinal lymph node dissection. Wedge resections with less extensive lymphadenectomy were performed only if there were patients with limited pulmonary reserve and/or clinical conditions making the standard operation difficult. Primary bronchial closure was performed by using both the open-hand and the closed-stapler technique. Many years ago, Sweet emphasized the principles of bronchial closure: minimal bronchial trauma, preservation of blood supply to the cut end and adequate tissue reinforcement of the bronchial suture line.[7] These principles have been respected in all patients.

When performing pneumonectomy the main bronchus was cut oblique. The membranous wall was left longer in order to reduce the tension on the bronchial suture line because of its natural tendency to retract due to the muscular mucosa (Fig. 1a). After a negative bronchial margin was ensured by frozen-section analysis, hand suture closure was performed using simple 3-0 Vicryl sutures (Ethicon Inc. Norderstedt, Germany). First, the midpoint of the membranous bronchus was carefully approximated to the cartilaginous wall. Then the remaining left and right stump segments were systematically closed with simple 3-0 Vicryl sutures (Fig. 1b). Occasionally, the approximation between the cartilaginous portions with the infolded membranous portion was performed. For mechanical bronchial closure a premium-type TA 35, parallel-jaw stapler was used. On the right side the pneumonectomy stump was covered with mediastinal pleura and a pericardial fat pad. Primary intercostal muscle or pericardial flap was used only in high-risk cases.

The most characteristic feature of our bronchoplastic procedures was the use of interrupted 3-0 Vicryl and/or 3-0 PDS sutures for the cartilaginous part of the bronchial anastomosis. Detailed technical aspects are described elsewhere.[8]

Early BPF was defined as fistulae occurring within 12 days after the initial operation. Late BPF was defined as fistulas occurring after more than 12 days. The management of a BPF varied according to the initial type of sur-

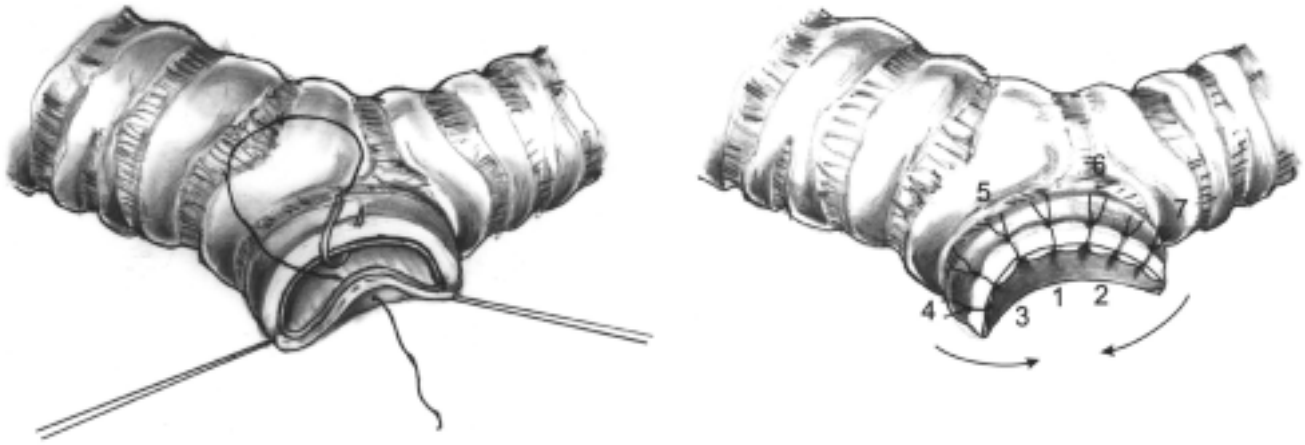

a b

Fig. 1. a: The open-hand technique. The main bronchus is cut oblique and the membranous wall is left longer in order to reduce the tension on the bronchial suture line because it has a natural tendency to retract.
b: First, the midpoint of the membranous bronchus is carefully approximated to the cartilaginous wall. Then the remaining left and right stump segments are systematically closed.

gery, the size of the BPF, the overall patient condition and that of the remaining lung. Early postpneumonectomy BPFs received immediate chest tube drainage prior to rethoracotomy in order to prevent aspiration pneumonia of the non-operated side. Re-exploration through the previous thoracotomy incision was performed immediately in 10 patients. After debridement and refashioning, the bronchial stump was reclosed by hand suture using absorbable 3-0 Vicryl or slowly absorbable 3-0 PDS sutures. The remaining chest cavity was then extensively irrigated with a polyvidon-iod solution (Braunol®) and closed.

Mortality was defined as one occurring within 30 days of surgery or beyond that period if the patient had not left the hospital.

Preoperative adjuvant treatment (down-staging)
In the treatment of NSCLC, various adjuvant modalities other than surgery have been used at our institution over the course of several years. In this series 15 patients with advanced, functionally operable stage IIIB lung cancer received 4 cycles of doxetaxel (100 mg/m^2, day 1) and carboplatin (AUC 7.5 mg, day 2) with G-CSF support after cycle 1 as preoperative down staging therapy and were subsequently evaluated for surgery.[4] Postoperatively these patients were irradiated with 50 Gy (Ro-resection) or 60 Gy (R1-resection).

For statistical analysis we used the statistical package Statistica 5-0 designed for Windows. Univariate testing of data was performed with chi-square or Fischer's exact test for discrete variables. A probability value of $p<0.05$ was considered significant.

Results

A BPF developed postoperatively in 22 patients. The overall incidence of BPFs after NSCLC surgery was 4.4%. The BPF incidence according to the type of surgery is presented in Table 1. There were 21 (95.5%) males and 1 (4.5%) female. The histological types were distributed as follows: 10 (45.5%) squamous cell carcinoma, followed by 8 (36.3%) adenocarcinoma, 3 (13.6%) large-cell carcinoma and 1 (4.6%) combined form squamous cell and adenocarcinoma.

Table 1. BPF incidence according to the type of surgery

Type of surgery	No. pts.	Incidence of BPF	(%)
Lobectomy	295	9	(3.0)
right	174	7	(4.0)
left	121	2	(1.6)
Pneumonectomy	175	12	(6.8)
right	74	10	(13.5)
left	101	2	(1.9)
Sleeve resection	15	1	(6.6)
right	11	1	(9.0)
left	4	0	(0)
Wedge resection	5	0	(0)
Total	490	22	(4.4)

Table 2. Clinical features of patients with BPF (from 1990 to 1999, n=12)

No.	Operation	Bronchial suture	Intervention	Coverage	Postop.	day	Outcome	Causes of death	Empyema	Down staging
1	PN-right	Stapler	D+R	PFP	Early	3	Healed			
2	PN-right	Manual	D+R	ICM	Early	2	Died	ARDS		
3	PN-right	Stapler	D+R	OF	Late	27	Healed			
4	PN-right	Manual	D+R	ICM	Late	42	Died	Sepsis		
5	PN-right	Manual	Endo	OF	Late	15	Healed		Yes	
6	PN-right	Stapler	D+R	PFP	Early	3	Healed			
7	PN-right	Manual	Endo	ICM	Late	30	Healed			
8	PN-right	Manual	D+R	PFP	Early	10	Died	ARDS		
9	PN-left	Manual	D+R	ICM	Early	2	Healed			DS
10	PN-left	Manual	D+R	ICM	Early	6	Healed			DS
11	PN-right	Stapler	D+R	OF	Early	4	Died	ARDS		
12	PN-right	Manual	D+R	OF	Early	8	Healed			
13	LL-right	Manual	CB	ICM	Late	20	Healed			
14	LBi	Manual	CP	ICM	Early	5	Healed			
15	LL-right	Stapler	CB	No	Early	3	Healed			
16	LL-left	Manual	CP	No	Early	12	Healed			
17	LBi	Manual	CP	PFP	Early	10	Died	ARDS		
18	LL-right	Stapler	CB	ICM	Early	7	Healed			
19	LL-left	Stapler	CP	ICM	Late	25	Died	Metas		
20	LL-right	Manual	CB	ICM	Early	10	Healed			
21	LBi	Manual	CP	PFP	Late	19	Healed			
22	SL-right	Manual	CP	PFP	Early	2	Healed			

PN: pneumonectomy; UL: upper lobectomy; LL: lower lobectomy; Lbi: lower bilobectomy; D: debridement; DS: down staging; R: reclosure; ARDS: acute respiratory distress syndrome; ICM: intercostal muscle, PFP: pericardial fat pad, OF: omental flap; CP: completion pneumonectomy; CB: completion bilobectomy; SL: sleeve lobectomy; Metas: metastasis.

Clinical features

The clinical features of all patients with BPFs are presented in Table 2. Postpneumonectomy stump insufficiency was the main cause of a BPF in 12 (54.6%) patients, followed by post-lobectomy BPF in 9 (40.9%) patients and postoperative bronchial dehiscence after sleeve resection in 1 (4.5%) patient. Postpneumonectomy stump dehiscence occurred in 10 patients on the right and in 2 patients on the left side. Postlobectomy BPF occurred on both sides after lower lobectomies only, on the right side in 4 patients after lower lobectomy, in 3 patients after lower bilobectomy and in both cases on the left side after lower lobectomy.

BPFs occurred early in 15 (68.1%) patients and late in 7 (31.9%) patients (mean postoperative day 12). Postpneumonectomy stump insufficiency developed early in 8 (36.3%) and late in 4 (18.1%) cases. Post-lobectomy BPF occurred early in 7 (31.8%) and late in 3 (13.6%) patients. No BPFs developed later than postoperative day 42.

Bronchial closure

Primary manual bronchial suture was performed in 64.7% (317/490) and stapler suture in 35.3% (173/490) patients. Postpneumonectomy stump insufficiency developed as follows: 7.6% (8/105) after manual- and 5.7% (4/70) after stapler bronchial suture (p=ns). Postlobectomy BFP occurred after manual suture in 3% (6/197) and stapler suture in 2.9% (3/103) patients (p=ns).

Mortality

The overall mortality rate for postoperative BPF was 27.2% (6/22). The mortality for postpneumonectomy BPF was 33.3% (4/12). Aspiration pneumonia with consequent ARDS caused death in 4, empyema with sepsis and cachexia in 1, and distant tumor recurrence in 1 patient. The diagnosis was suggested clinically, confirmed by X-ray studies and bronchoscopy. All patients with a right bronchial stump insufficiency required prolonged mechanical ventilation for postoperative respiratory insufficiency.

Risk factors

Risk factors that might contribute to the development of BPFs such as age, operative side, direct barotrauma due to postoperative mechanical ventilation, diabetes, ad-

Table 3. Possible risk factors analyzed in association with postpneumonectomy stump insufficiency (from 1990 to 1999, n=165)

Analyzed risk factor	No.	BFP (%)	*p*
Postoperative mechanical ventilation	40	18.7%	0.001
Right pneumonectomy	75	13.5%	0.04
Diabetes mellitus	52	8.5%	ns
Preoperative radiotherapy	19	6.5%	ns
Pleuropulmonary infection	25	7.9%	0.06
Advanced stage III-IV	20	2.1%	ns
Extensive systematic lymphadenectomy	121	5.8%	ns
Residual carcinomatous stump	7	0.5%	ns

ns: not significant.

vanced surgical stage, preoperative radiotherapy, preexisting pleuropulmonary infection, residual carcinomatous tissue at the bronchial stump and other technical factors such as type of bronchial suture, type of lymphadenectomy, were retrospectively evaluated (Table 3). The incidence of postpneumonectomy BPF in association with the aforementioned risk factors was compared with the incidence in patients who did not have these risk factors. Right-sided pneumonectomy and postoperative barotrauma due to mechanical ventilation were associated with a significantly higher risk of stump insufficiency. Preexisting pleuropulmonary infection and advanced surgical stage were associated with higher rates of BPFs, however the differences were not statistically significant.

In 2 patients with late, small BPFs (ϕ <5 mm, pinhole fistula) and poor overall condition the initial treatment was endoscopic using fibrin sealant and spongy iliacal bone. In both patients the fistula persisted and the stump had to be surgically resutured.

BPFs after lobectomy were treated as follows: on the right side completion bilobectomy was performed in 4 patients, and completion pneumonectomy in 3 patients; on the left side completion pneumonectomy was performed in both cases. In 1 patient the BPF developed 36 hours after a right upper sleeve resection in the membranous part of the bronchial anastomosis. A new anastomosis was technically impossible after refashioning the bronchial suture line so that pneumonectomy had to be performed.

At rethoracotomy the bronchial stump was additionally covered with a pedicled well-vascularized flap in 20 (90.9%) patients (10 intercostal muscle flaps, 6 pericardial fat pad and 4 omental flaps). The mediastinal pleura was avoided because of its poor blood supply.

Two (9%) patients developed early stump insufficiency after down staging and right pneumonectomy. After rethoracotomy and surgical treatment both patients recovered. No patients in this subgroup died from fistula-related causes.

Discussion

Although nowadays there are not many differences in case selection, mode of operation and background, the reported incidence of BPFs after pneumonectomy is still heterogeneous (Table 4). In our series the overall incidence of BPFs of 3.7% and a postpneumonectomy BPF incidence of 6.8% was acceptable. Postpneumonectomy stump dehiscence is the main cause of BPFs associated with a high mortality and morbidity. In the literature the mortality ranges from 25% to 67%, the most common cause of death being aspiration pneumonia with subsequent ARDS,[1,5] Our data confirm these findings.

The right side is associated with a higher postpneumonectomy BPF rate.[1] In our study the need for prolonged postoperative ventilation was correlated with a higher incidence of BPFs. This is probably due to the

Table 4. Postpneumonectomy bronchopleural fistula, incidence and mortality in the literature

Autor	Year	No. pat.	Incidence BPF	(%)	Mortality (%)
Hankins [12]	1978	148	11	(7.4)	46.6
Madsen [19]	1984	225	28	(12.5)	28.6
Vester [11]	1991	506	23	(4.5)	nm
Asamura [3]	1992	464	21	(4.5)	nm
Weissberg [10]	1992	72	7	(9.7)	nm
Al-Kattan [2]	1995	471	7	(1.5)	28.5
Wright [1]	1996	256	8	(3.1)	25
Holläus [5]	1997	797	96	(12.2)	67
Sirbu (current report)		175	12	(6.8)	33.3

nm: not mentioned.

larger size and greater tendency of the right main bronchus to spring open, facilitated by a prolonged barotrauma in conjunction with perturbances of the bronchial microvasculature which lead to stump necrosis.[1,9)]

The method of bronchial closure used to achieve a low incidence of BPF remains a controversial topic. Controversy exists regarding the merits of manual versus stapled bronchial sutures. Many authors are advocating the superiority of stapler sutures.[3,10,11)] Recently endostapler-type devices have also been used with good results. Because of both stapling and division simultaneously in only one firing motion associated with other practical advantages, these devices have also been advocated for open lung surgery.[9)] On the other hand manual bronchial suture is the preferred technique in other institutions.[2)] In our department, both techniques are routinely used. A stapling bronchial suture is preferred when there is a peripheral NSCLC with no evidence of endobronchial tumor at bronchoscopy. Possible advantages using staplers for surgical bronchial closure are: 1. contamination of the operative field can be minimized; 2. the time required for closure can be greatly reduced. Little information is currently available concerning the reliability of endostaplers in pulmonary resections.[9)] A manual suture of the open bronchus was considered when endobronchial tumor growth was present at endoscopy or when the tumor was located close to the hilum. In all cases an intraoperative negative bronchial margin assessed by fresh frozen sections is today's golden standard. When the bronchial wall is hard due to calcification of the cartilage or when massive hilar adenopathy co-exist a stapler is difficult to apply.[9)] In these cases a proper, oblique bronchial cut with a longer pars membranaceus and hand suture is to be considered. It is clear that manual bronchial closure is at least as good as stapled closure.[1,3,11)] More important, manual closure can always be performed in cases when stapled closure should be avoided.[1,11)]

After studying possible risk factors for BPFs another important surgical aspect that arises, is the necessity of primary stump coverage. Although no prospective randomized trials in humans have been reported, no controversial element regarding stump coverage has been reported. Based on our experience and results from other studies, it seems prudent to cover at least stumps from right pneumonectomies and stumps associated with possible risk factors.[1)]

Older reports have emphasized that early postpneumonectomy stump insufficiency should be treated with

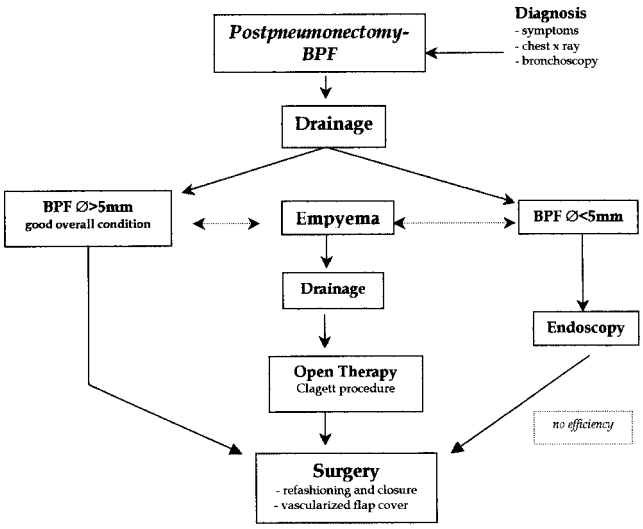

Fig. 2. Step-approach in the surgical therapy of BPF.

drainage alone rather than immediate bronchial stump reclosure.[12,13)] We have not adopted this strategy. Early drainage is only the first step in the surgical therapy of BPFs (Fig. 2). It is always indicated to prevent aspiration pneumonia on the non-operated side and empyema. Further surgical management varies according to the size of the fistula and the overall condition of the patient.[5)] When the overall patient condition permitted, reclosure was performed immediately after BPF diagnosis (clinical, radiological and bronchoscopic confirmation) regardless of time elapsed since pneumonectomy. The bronchial stump was debrided, refashioned, reclosed by hand suture technique and covered with a well-vascularized flap. Intercostal muscle, pericardial fat pad and/or omental flap have been used with good results.[1,5)] Some authors are advocating the use of an omentum flap in the treatment of postpneumonectomy BPFs. Its unique proprieties of enhancing neovascularity due to an angiogenesis factor, providing fibroblasts to promote healing, providing soft tissue coverage and functioning in the face of infection make it an ideal tool for the management of BPFs.[14)] Extrathoracic muscle flaps with latissimus dorsi and/or pectoralis major muscle have also been described as vascularized-flaps that can be used for the surgical therapy of BPFs.[15)] The transsternal approach has been described and used for the surgical treatment of BPFs associated with empyema.[16)] In our patient group we have not used this technique.

A BPF following lobectomies necessitates a completion bronchial resection.[17)] In one case we have performed a completion left sleeve resection with good results.

In patients with poor general condition and small fistulas, less then 5 mm, BPFs were initially treated endoscopically using fibrin sealant (Tissuecol®) and iliacal spongy bone. No decalcified human spongiosa or calf bone has been used.[5,18] Endoscopic treatment failed in all patients. Both underwent chest reexploration with secondary surgical procedures. These cases enforce our believe that aggressive treatment of postpneumonectomy BPF provides the best successful long-term results.

Bronchial stump insufficiency remains a major complication in the surgery of NSCLC because of its high mortality and morbidity rate. In all cases a successful treatment of BPFs requires early surgery and an individualized approach for each patient in order to prevent life threatening circumstances and to avoid late complications.

References

1. Wright CD, Wain JC, Mathisen DJ, Grillo HC. Postpneumonectomy bronchopleural fistula after sutured bronchial closure: incidence, risk factors, and management. *J Thorac Cardiovasc Surg* 1996; **112**: 1367–71.
2. Al-Kattan K, Cattelani L, Goldstraw P. Bronchopleural fistula after pneumonectomy for lung cancer. *Eur J Cardio-thorac Surg* 1995; **9**: 479–82.
3. Asamura H, Naruke T, Tsuchiya R, Goya T, Kondo H, Suemasu K. Bronchopleural fistulas associated with lung cancer operations univariate and multivariate analysis of risk factors, management, and outcome. *J Thorac Cardiovasc Surg* 1992; **104**: 1456–63.
4. Herse B, Dalichau H, Wormann B, et al. Induction combination chemotherapy with docetaxel and carboplatin in advanced non-small-cell lung cancer. *Thorac Cardiovasc Surg* 1998; **46**: 298–302.
5. Hollaus PH, Lax F, El-Nashef BB, Hauck HH, Lucciarini P, Pridun NS. Natural history of bronchopleural fistula after pneumonectomy: a review of 96 cases. *Ann Thorac Surg* 1997; **63**: 1391–7.
6. Mountain CF. Revisions in the international system for staging lung cancer. *Chest* 1997; **111**: 1710–7.
7. Sweet RH, Closure of the bronchial stump following lobectomy or pneumonectomy. *Surgery* 1945; **18**: 82–4.
8. Sirbu H, Herse B, Schorn B, Hüttemann U, Dalichau H. Successful surgery after complete disruption of the right bronchial system. *Thorac Cardiovasc Surg* 1995; **43**: 239–41.
9. Asamura H, Kondo H, Tscuchiya R. Management of the bronchial stump in pulmonary resections: a review of 533 consecutive recent bronchial closures. *Eur J Cardio-thorac Surg* 2000; **17**: 106–10.
10. Weissberg D, Kaufmann M. Suture closure versus stapling of bronchial stump in 304 lung cancer operations. *Scand J Thor Cardiovasc Surg* 1992; **26**: 125–7.
11. Vester SR, Faber LP, Kittle F, Warren W, Jensik RJ. Bronchopleural fistula after stapled closure of bronchus. *Ann Thorac Surg* 1991; **52**: 1253–8.
12. Hankis JR, Miller JE, Attar S, Satterfield JR, McLaughlin JS. Bronchopleural fistula. Thirteen-year experience with 77 cases. *J Thorac Cardiovasc Surg* 1978; **76**: 755–62.
13. Miller JI, Postsurgical empyemas. In: Shields TA ed.; General Thoracic Surgery, 4th ed. Baltimore: Williams and Wilkins 1994; p 696.
14. Mathisen DJ, Grillo HC, Vlahakes GJ, Daggett WM. The omentum in the management of complicated cardiothoracic problems. *J Thorac Cardiovasc Surg* 1988; **95**: 677–84.
15. Pairolero PC, Arnold PG, Trastek VF, Meland NB, Kay P. Postpneumonectomy empyema: the role of intrathoracic muscle transposition. *J Thorac Cardiovasc Surg* 1990; **99**: 958–68.
16. Stamatis G, Martini G, Freitag L, Wencker M, Greschuna D. Transsternal transpericardial operations in the treatment of bronchopleural fistulas after pneumonectomy. *Eur J Cardio-thorac Surg* 1996; **10**: 83–6.
17. Gregoire J, Deslauriers J, Guojin L, Rouleau J. Indications, risks, and results of completion pneumonectomy. *J Thorac Cardiovasc Surg* 1993; **105**: 918–24.
18. Baumann WR, Ulmer JL, Ambrose PG, Garvey MJ, Jones DT. Closure of a bronchopleural fistula using decalcified human spongiosa and a fibrin sealant. *Ann Thorac Surg* 1997; **64**: 230–3.
19. Madsen KH, Schulze S, Pedersen VM, Halkier E. Management of bronchopleural fistula following pneumonectomy. *Scand J Thor Cardiovasc Surg* 1984; **18**: 263–6.