Original Article

What can Doppler Wave Forms of the Left Internal Thoracic Artery Teach Us? –The Efficacy of Apical Transthoracic Approach of Doppler Echocardiography–

Mitsumasa Hata, MD,[1] Jai S. Raman, FRACS,[1] Motomi Shiono, MD,[2] Akira Sezai, MD,[2] Nanao Negishi, MD,[2] Yukiyasu Sezai, MD,[2] Sievn Seevanayagam, FRACS,[1] Robin Kanagasaby, FRCS,[1] Meg Store, BN (Hnos),[1] Elizabeth D. Croce, MA, CMI,[1] and Brian F. Buxton, FRACS[1]

The Doppler wave form along the proximal left internal thoracic artery (LITA), which is detected by the parasternal or suplaclavicular view, shows a different pattern from that of the distal side of the LITA due to the effect of blood pulsatility from the subclavian artery. We evaluated postoperative LITA function immediately after surgery with an apical approach of transthoracic pulsed Doppler echocardiography in 124 patients and compared its results with that of one month postoperative Doppler findings and graft angiogram. The LITA was effectively detected and good quality Doppler waveforms obtained in 120 (96.8%) patients. The LITA diameter was significantly enlarged in the first month after surgery compared with that of the postoperative early phase (1.99±0.31 vs. 1.71±0.72 mm, $p<0.05$). The diastolic peak velocity and diastolic/systolic velocity ratio (D/S) in the postoperative early phase were 0.26±0.08 m/sec. and 1.54±0.04, respectively. These results were unchanged one month postoperatively. In graft angiography, all LITAs were patent, but three types of abnormal findings around the anastomosis such as string sign, anastomotic stenosis, and distal native coronary stenosis were indicated in 6 (5.5%) patients. The Doppler study in these patients showed decreasing diastolic peak velocity and D/S of less than 1.0. LITA Doppler wave with D/S of more than 1.0 was associated with a good angiographic finding. This technique was considered not only noninvasive but also noninfective method for postoperative early graft assessment. (Ann Thorac Cardiovasc Surg 2002; 8: 92–6)

Key words: CABG, left internal thoracic artery, Doppler wave form, trans apical approach

Introduction

The use of the left internal thoracic artery (LITA) graft to revascularize the left anterior descending coronary artery (LAD) has significantly improved the long-term results of coronary artery bypass grafting (CABG).[1)] However, several investigators have pointed out that the postoperative early graft flow reserve of the LITA is not sufficient due to vasospasm or the effects of cardiopulmonary bypass.[2)] Therefore, several surgeons recommend postoperative early graft angiography to assess the LITA function. However, it is considered quite risky, particularly in the postoperative early phase. Meanwhile, several recent studies have suggested that transthoracic Doppler echocardiography, either utilizing a parasternal or supraclavicular approach, can reliably assess the postoperative early patency of the LITA following grafting.[3,4)] Even with these techniques, however, it might be unclean and

From the [1]Department of Cardiac Surgery, Austin & Repatriation Medical Centre, University of Melbourne, Australia, and the [2]Second Department of Surgery, Nihon University School of Medicine, Tokyo, Japan

Received July 17, 2001; accepted for publication October 2001.
Address reprint requests to Mitsumasa Hata, MD: Second Department of Surgery, Nihon University School of Medicine, 30-1 Ooyaguchi Kamimachi, Itabashi-ku, Tokyo 173-8610, Japan.

Fig. 1. Schematic drawing of the patient and echo probe position.

painful for the patient in the postoperative early phase because the probe position was very close to the median wound. Furthermore, the Doppler wave form along the proximal LITA shows a different pattern from that of the distal LITA due to the effect of blood pulsatility from the subclavian artery.[5] In this study, we used transthoracic Doppler echocardiography with an apical approach to evaluate the LITA function in the postoperative early phase and assessed the accuracy of this approach by comparing the Doppler findings with a graft angiogram.

Patients and Methods

Between January 1999 and December 2000, 886 patients underwent CABG at the Austin & Repatriation Medical Centre and Nihon University Itabashi Hospital. In this study, 124 patients undergoing primary CABG were studied with an apical approach of Doppler echocardiography. The mean age of the patients was 67.4±7.3 (mean±standard deviation: SD) years and the average number of grafts per patient was 3.22±0.74. Saphenous vein or radial artery were used for the bypass graft to the coronary arteries except for the LAD. We evaluated postoperative LITA function immediately after surgery or during the first postoperative day (POD1) with transthoracic pulsed Doppler echocardiography using an Acuson C256 machine (Acuson Co., CA, U.S.A.) equipped with a 7 MHz transducer and compared its results with that of the postoperative one-month Doppler study and graft angiography. In the Doppler imaging using an apical approach (Fig. 1), the LAD was firstly found running along the interventricular groove. The point of anastomosis between the LITA and the LAD was then detected by tilting the probe slightly upwards. The LITA diameter, average peak diastolic velocity, velocity time integral (VTI), and diastolic/systolic velocity ratio (D/S) were measured using on line calipers and averaged over three cardiac cycles. One hundred and ten of 124 (88.7%) patients underwent the postoperative graft angiography within two to four weeks of surgery.

The continuous results were expressed as mean±SD. Statistical analysis was performed with paired t-test and statistical significance was defined as a p value of less than 0.05.

Results

The LITA was effectively detected and good quality Doppler waveforms obtained in 120 (96.8%) of all the patients. Four patients were too obese to have their LITA scanned with an apical approach. The Doppler wave form in the distal portion of the grafted LITA has a biphasic velocity pattern with a higher mid-diastolic and lower antegrade component at end systole. This was a different pattern to a supraclavicular approach (Fig. 2).[5] The LITA diameter was significantly enlarged in the first month after surgery compared with POD1 (1.99±0.31 vs. 1.71±0.72 mm, $p<0.05$). The diastolic peak velocity and D/S on POD1 were 0.26±0.08 m/sec. and 1.54±0.04, respectively. These results were unchanged one month postoperatively. The VTI was also significantly increased in the first month after surgery compared with POD1 (12.2±2.7 vs. 10.4±2.1 cm, $p<0.05$).

In graft angiography, all LITA were patent, but the three types of abnormal findings around the anastomosis were indicated in 6 (5.5%) patients. Three of these patients had a LITA string sign, in which the LITA distal portion disappeared due to reversed flow from the native LAD, so called "blood flow competition." In these three patients, mean diastolic peak velocity and D/S in Doppler study were 0.17±0.11 m/sec. and 0.88±0.10, respectively (Fig. 3). The LITA 90% stenosis at the anastomosis portion were indicated in two other patients. In these patients, mean diastolic peak velocity and D/S in Doppler study were 0.16±0.12 m/sec. and 0.96±0.02, respectively (Fig. 4). The sixth patient had tight stenosis on the distal native

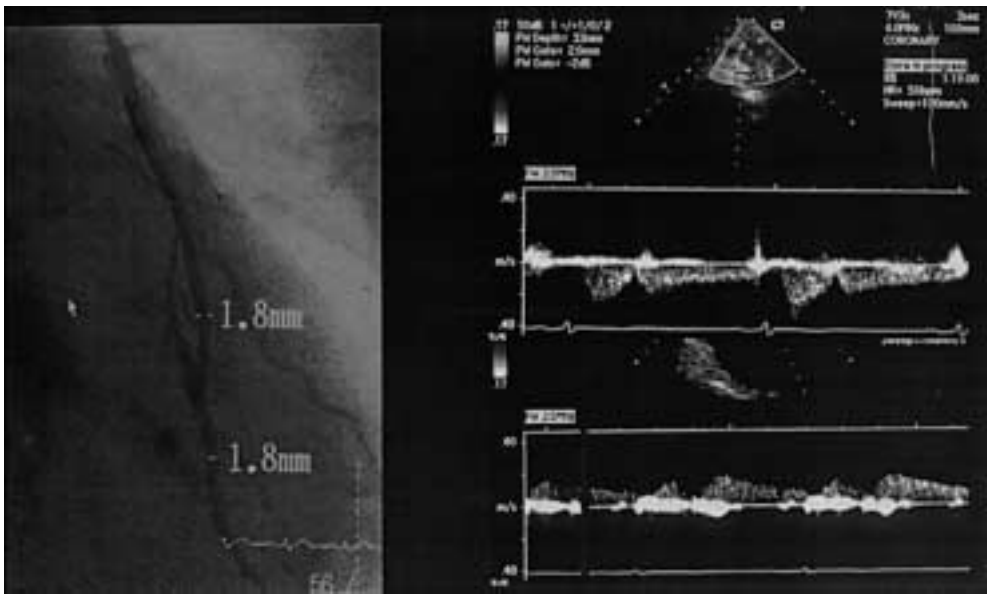

Fig. 2. Normal finding on the LITA angiogram (left). The Doppler wave form in the distal portion of the grafted LITA has a biphasic velocity pattern with a higher mid-diastolic and lower antegrade component at end systole (right, lower) which was a different pattern from that of the supraclavicular approach (right, upper).

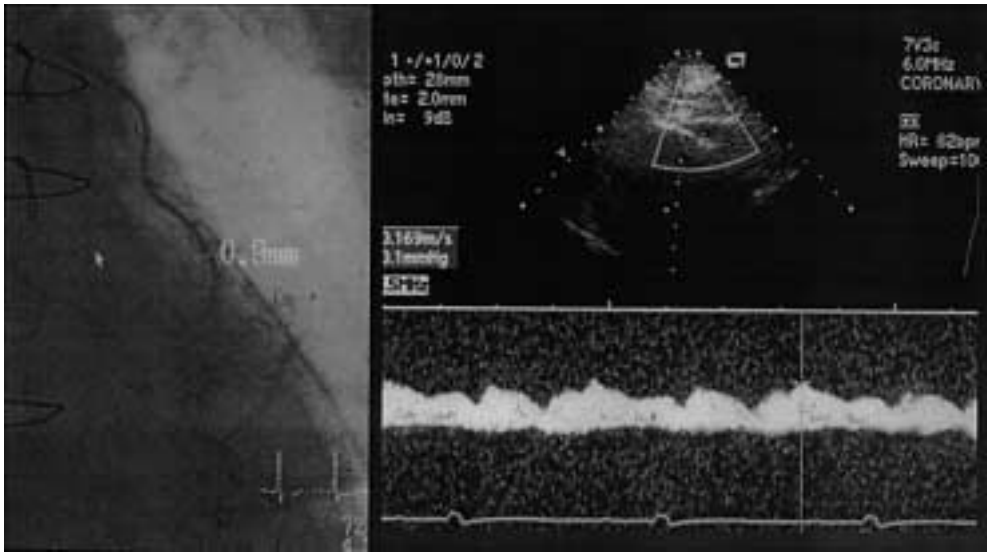

Fig. 3. The LITA string sign. Doppler wave form shows the lower diastolic peak velocity and D/S of less than 1.0.

LAD. The Doppler study in this patient also showed decreasing diastolic peak velocity and D/S of less than 1.0 (Fig. 5). LITA Doppler wave with D/S of more than 1.0 was associated with a good angiographic finding.

Discussion

It is generally accepted that the use of the LITA graft to revascularize the LAD has significantly improved the long-term results of CABG. However, it has been reported that the early postoperative graft flow reserve of the LITA at times may be insufficient due to vasospasm or to the effects of cardiopulmonary bypass.[2] Several surgeons recommend postoperative early graft angiography to assess the LITA function. However, the postoperative graft angiography is considered quite risky during the postoperative early phase. Also, there are some factors, such as injection pressure of contrast media, or different position of the catheter for angiography which may cause bias in the results. For example, we had several cases whose graft angiograms showed good patency of LITAs if catheters were wedged into the LITA itself. In those cases, however, the LITA angiogram detected the string sign due to flow competition if contrast media was injected from the subclavian artery. In fact, several investigators have reported a discrepancy between angiographic and pulse Doppler findings of LITA, in which the LITA D/S ratio was sometimes very low on the Doppler study, despite

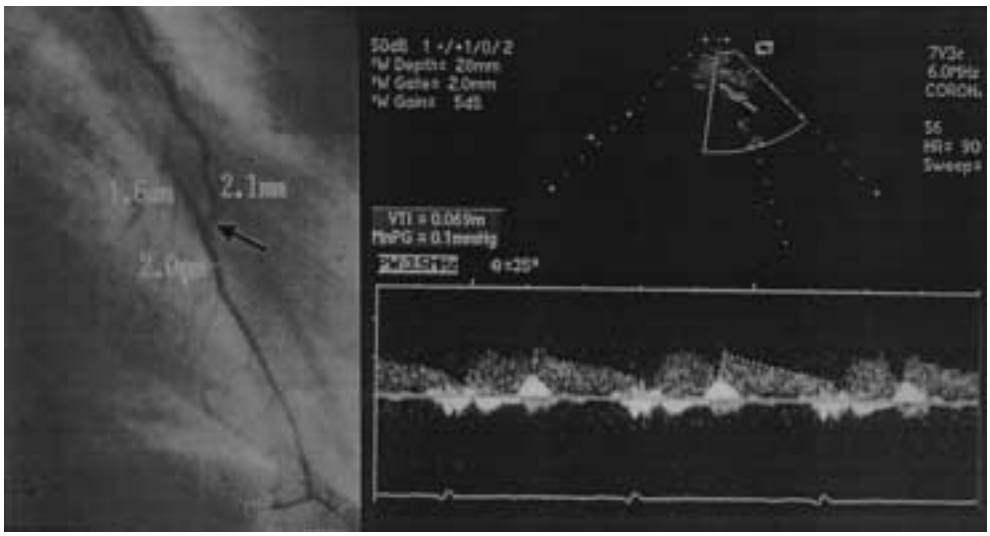

Fig. 4. The LITA 90% stenosis at the anastomosis portion (arrow). Doppler wave form shows the lower diastolic peak velocity and D/S of less than 1.0.

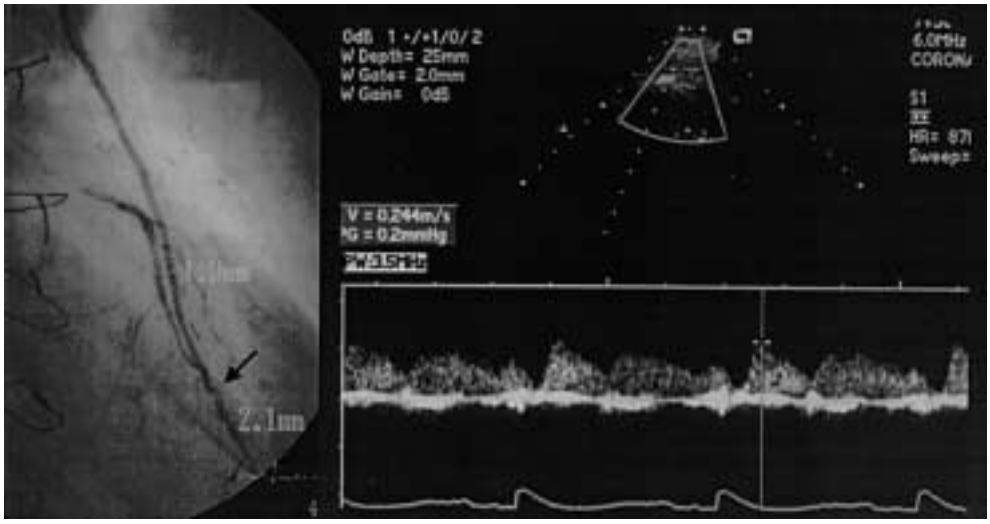

Fig. 5. Distal native LAD stenosis (arrow). Doppler wave form shows the lower diastolic peak velocity and D/S of less than 1.0.

excellent postoperative graft patency on angiography.[6)]

Even though LITA was assessed with Doppler echocardiography using a parasternal or supraclavicular approach,[3,4)] the Doppler wave form along the proximal LITA showed a different pattern from that of the distal LITA due to the effect of blood pulsatility from the subclavian artery.[5)] Therefore, it may be difficult to assess accurately whether the graft is functionally patent or not. We consider it important to evaluate the Doppler wave form along the LITA just proximal to the anastomosis with the LAD. This is because the distal portion of the LITA is the most sensitive and easily affected by vasospasm.[7)] Therefore, we consider the routine evaluation of the LITA Doppler wave form along the portion proximal to the anastomosis to the LAD early in the postoperative period to be an essential part of the assessment of LITA grafts postoperatively.

A previous report described a lower D/S ratio in a Doppler echocardiographic study caused by a stenosis of the LITA anastomosed to the LAD.[3)] On the other hand, Furutani and colleagues reported that the LITA D/S ratio was low in patients with minimal stenosis of the native LAD. These findings indicate competition between native blood flow and LITA blood flow, which may cause the LITA string sign in the late postoperative period.[8)] In our patients, early conduit or anastomotic malfunction was suggested in six cases because their D/S ratios were less than 1.0. Postoperative angiography at two to four weeks demonstrated competitive LITA flow from the native LAD in three cases, anastomotic stenosis in two cases, and distal native LAD stenosis in one case. However, no recurrent angina was reported. Three patients who

had LITA string sign due to flow competition were observed with expectation of the LITA remodeling. We previously reported a case in which an early postoperative LITA string sign due to flow reversal disappeared spontaneously.[9] The patency of the vessel was markedly improved on the one-year postoperative angiogram.[9] Those three patients had around 50 to 70% stenosis on the native LAD. In the present study, we anastomosed the LITA to the LAD with more than 50% stenosis. Cosgrove et al. also report even when the LITA is anastomosed to the LAD with less than 50% stenosis, it has no effect on the LITA graft quality.[10] In this study, the postoperative average diameter of the LITAs was significantly increased at one month. Other patients who had anastomotic stenoses might be treated with re-do grafting or catheter intervention for the LITA in the future if they had recurrent angina.

The presence of abnormal wave form using the apical view of the LITA Doppler study was correlated with angiographic abnormality. In contrast, a LITA with a D/S ratio of more than 1.0 and an enlarged diameter is likely to have an excellent LITA function.

Conclusion

The Doppler apical approach may offer a noninvasive, repeatable method of evaluating the LITA graft function in the immediate postoperative period. This technique is economical and avoids complications of angiography such as bleeding and infection.

References

1. Lytle BW, Loop FD, Cosgrove DM, Ratliff NB, Easley K, Taylor PC. Long-term (5 to 12 years) serial studies of internal mammary artery and saphenous vein coronary bypass grafts. *J Thorac Cardiovasc Surg* 1985; **89**: 248–58.
2. De Paulis R, Tomai F, Gaspardone A, et al. Coronary flow reserve early and late after minimally invasive coronary artery bypass grafting in patients with totally occluded left anterior descending coronary artery. *J Thorac Cardiovasc Surg* 1999; **118**: 604–9.
3. Calafiore AM, Gallina S, Iaco A, et al. Minimally invasive mammary artery Doppler flow velocity evaluation in minimally invasive coronary operations. *Ann Thorac Surg* 1998; **66**: 1236–41.
4. Süngün M, Duran E, Cebeci BS, Us MH, Saba D, Saygin G. The assessment of internal mammary artery grafts by color Doppler in coronary artery surgery. *J Cardiovasc Surg* 1998; **39**: 75–8.
5. Hata M, Shiono M, Orime Y, et al. Should use of the internal thoracic artery be avoided under conditions of low free flow? Postoperative hemodynamic assessment using pulsed Doppler echocardiography. *Jpn Circ J* 1999; **63**: 533–6.
6. Pezzano A, Fusco R, Child M, et al. Assessment of left internal mammary artery grafts using dipyridamole Doppler echocardiography. *Am J Cardiol* 1997; **80**: 1603–6.
7. He GW, Acuff TE, Yang CQ, Tyan WH, Mack MJ. Middle and proximal sections of the human internal mammary artery are not “passive conduits.” *J Thorac Cardiovasc Surg* 1994; **108**: 741–6.
8. Furutani Y, Takahashi T, Imagawa H, Taniguchi K, Kadoba K, Matsuda H. Noninvasive hemodynamic assessment of internal thoracic artery grafts using duplex echocardiography from supraclavicular fossa –a comparison with Doppler catheter method. *J Jpn Assoc Thorac Surg* 1997; **45**: 1803–9.
9. Hata M, Shiono M, Orime Y, et al. Spontaneous recanalization of postoperative severe graft stenosis. What is the cause and prognosis of the “string sign” in the internal thoracic artery? *Ann Thorac Cardiovasc Surg* 1999; **5**: 52–5.
10. Cosgrove DM, Loop FD, Saunders CL, Lytle BW, Kramer JR. Should coronary arteries with less than fifty percent stenosis be bypassed? *J Thorac Cardiovasc Surg* 1981; **82**: 520–30.