Original Article

Early Angiographic and Clinical Results of Branch Conduits Attached Proximally to Left Internal Thoracic Arteries

Mitsuharu Hosono, MD, Yoshihiro Shimizu, MD, Syuichiro Takanashi, MD, Hirokazu Minamimura, MD, Takumi Ishikawa, MD, Tadahiro Murakami, MD, Ken-u Fumimoto, MD, and Hiroyuki Nishi, MD

Background: We assessed the characteristics of composite branch conduits attached proximally to an in-situ left internal thoracic artery (LITA).
Methods: Sixty nine patients underwent coronary artery bypass grafting (CABG) using composite branch conduits. Overall 35 distal LITAs, 4 RITAs, 18 radial artery grafts (RAG), and 13 inferior epigastric artery grafts (IEA) (both the distal LITA and IEA were used in one patient) were used. Clinical and angiographic results were assessed.
Results: Patency of branch conduit was 97.1% in distal LITAs, 100% in RITAs, 100% in RAGs, and 90.9% in IEAs. All in-situ LITAs were patent. Ten branch conduits exhibited the string sign. The string sign was caused by competitive flow in seven patients. In three of seven patients with competitive flow, the string sign had resolved at one year after operation as the proximal stenosis of the native coronary artery increased in severity.
Conclusions: The results of CABG using branch conduits were satisfactory. It is feasible to observe and follow patients with composite grafts exhibiting the string sign in the absence of ischemia. (Ann Thorac Cardiovasc Surg 2002; 8: 145–50)

Key words: composite graft, coronary artery bypass grafting, arterial graft, string sign

Introduction

Since arterial grafts for coronary artery bypass grafting (CABG), particularly the left internal thoracic artery (LITA) have demonstrated excellent long-term patency, various arterial grafts have been utilized for CABG, including the radial, inferior epigastric, and right gastroepiploic arteries.[1-3] The aortic anastomosis is a critical issue for elderly patients, who are progressively increasing in number and whose aortic wall is often severely diseased. On occasion, we have to use a "no-touch" technique to manage the diseased ascending aorta in these patients when performing CABG. Moreover, the proximal caliber of the arterial graft is often small and the anastomosis to the aorta is technically more demanding. Therefore, free arterial grafts have often been used as composite grafts of the in-situ LITAs in CABG.[4-6]

We have also used various composite arterial grafts as side branches of the in-situ LITA in CABG, such as the right internal thoracic (RITA), radial (RAG), inferior epigastric (IEA), and the distal internal thoracic artery (dLITA; the distal portion of the LITA obtained after distal anastomosis of the in-situ LITA). In this study, we assessed the early angiographic and clinical results of arterial grafts used as branch conduits attached proximally to an in-situ LITA.

Patients and Methods

Patients

From January 1995 to December 2000, 69 patients (58 men and 11 women with a mean age of 62.7±8.8 years) underwent CABG using composite arterial grafts as branches of an in-situ LITA in our hospital. Comorbid conditions included hypertension (n=38), hyperlipidemia (n=34), diabetes (n=27), smoking (n=35), and hemodi-

From the Division of Cardiovascular Surgery, Osaka City General Hospital, Osaka, Japan

Received March 26, 2002; accepted for publication April 5, 2002.
Address reprint requests to Takumi Ishikawa, MD: Division of Cardiovascular Surgery, Osaka City General Hospital, 2-13-22, Miyakojimahondori, Miyakojima-ku, Osaka 534-0021, Japan.

Table 1. Anastomotic sites of branch conduits

	dLITA (n=35)	RITA (n=4)	RAG (n=18)	IEA (n=13)	Total (n=70)
No. of branch conduit used for sequential bypass	5/35 (14.3%)	0/4 (0%)	11/18 (61.1%)*	0/13 (0%)	16/70 (22.9%)
Total number of anastomosis of branch conduits	41	4	31	13	89
Anastomotic site					
LAD branch	34/41 (82.9%)*	2/4 (50%)	10/31 (32.3%)	2/13 (15.4%)	48/89 (53.9%)
LAD	2	1	1	0	4
Dx	32	1	9	2	44
Cx branch	7/41 (17.1%)	2/4 (50%)	21/31 (67.7%)*	11/13 (84.6%)*	41/89 (46.1%)
OM	5	0	10	7	22
PL	2	2	11	4	19

LAD=left anterior descending artery, Dx=diagonal branch, Cx=circumflexure artery, OM=obtuse marginal branch, PL=postero-lateral branch

*: $p<0.05$

alysis (n=7). Forty-eight patients underwent elective surgery. Preoperative coronary angiography revealed single-vessel disease in 3 patients, double-vessel disease in 19, and triple-vessel disease in 46; left main trunk stenosis was found in 9 patients, including 1 patient who only had disease in the left main trunk. Overall 35 dLITAs, 4 RITAs, 18 RAGs, and 13 IEAs were used (one patient had both the dLITA and IEA used) as branch conduits of an in-situ LITA.

Surgical technique

In-situ LITAs were harvested using the semi-skeletonization technique (LITA was harvested with its veins, but the muscle and fascia were left on the chest wall) using electrocautery. The in-situ LITA and its branch conduit were anastomosed using 8-0 polypropylene at various angles in order to avoid kinking and to obtain a smooth line to the distal anastomosis. The anastomosis between the in-situ LITA and branch conduit was constructed after the distal anastomoses. In off-pump CABG, this anastomosis was constructed prior to distal anastomosis. All nine patients undergoing CABG without cardiopulmonary bypass had RAGs as branch conduits. The mean (±SD) number of anastomoses by all grafts was 4.1±1.3 per patient. Mean (±SD) extracorporeal circulation time was 171.7±52.2 min, and aortic clamp time was 124.3±31.9 min (off-pump cases were not included in this data). Anastomotic sites of branch conduits are summarized in Table 1. The dLITAs were used more often for the diagonal branches than the others, and less for the branch of circumflexure artery. The RAG was used significantly more often for the sequential anastomosis than other grafts.

Follow-up

Sixty-six patients underwent early postoperative coronary angiography with informed consent. Early postoperative angiography was performed on average 26.4 days after operation. Follow-up data was collected annually or more frequently as was necessary, through direct patient contact, or by telephone interview. Mean follow-up time was 23.7 months (range from 0.9 to 61.2 months).

Statistical analysis

Patients with RITA were excluded from statistical analysis, since the number of patients was too small. Continuous variables were expressed as mean±SD. Direct variables expressed as the number or percentage of patients were compared using the χ^2 test. A $p<0.05$ was considered significant.

Results

Operative results

The mean intensive care unit stay was 2.4±1.3 days. Only one patient required an intra-aortic balloon pump to wean from cardiopulmonary bypass, and two patients died of mediastinitis in the hospital. Postoperative complications included two perioperative myocardial infarctions, one cerebral infarction, and the two cases of mediastinitis.

Angiographic findings

Sixty-six patients underwent postoperative coronary angiography with informed consent. Patency of composite grafts was 97.1% (34/35) in dLITAs, 100% (4/4) in RITAs, 100% (17/17) in RAGs, 90.9% (10/11) in IEAs. Patency of in-situ LITA is 100% (66/66). Seven dLITAs, 2 IEAs,

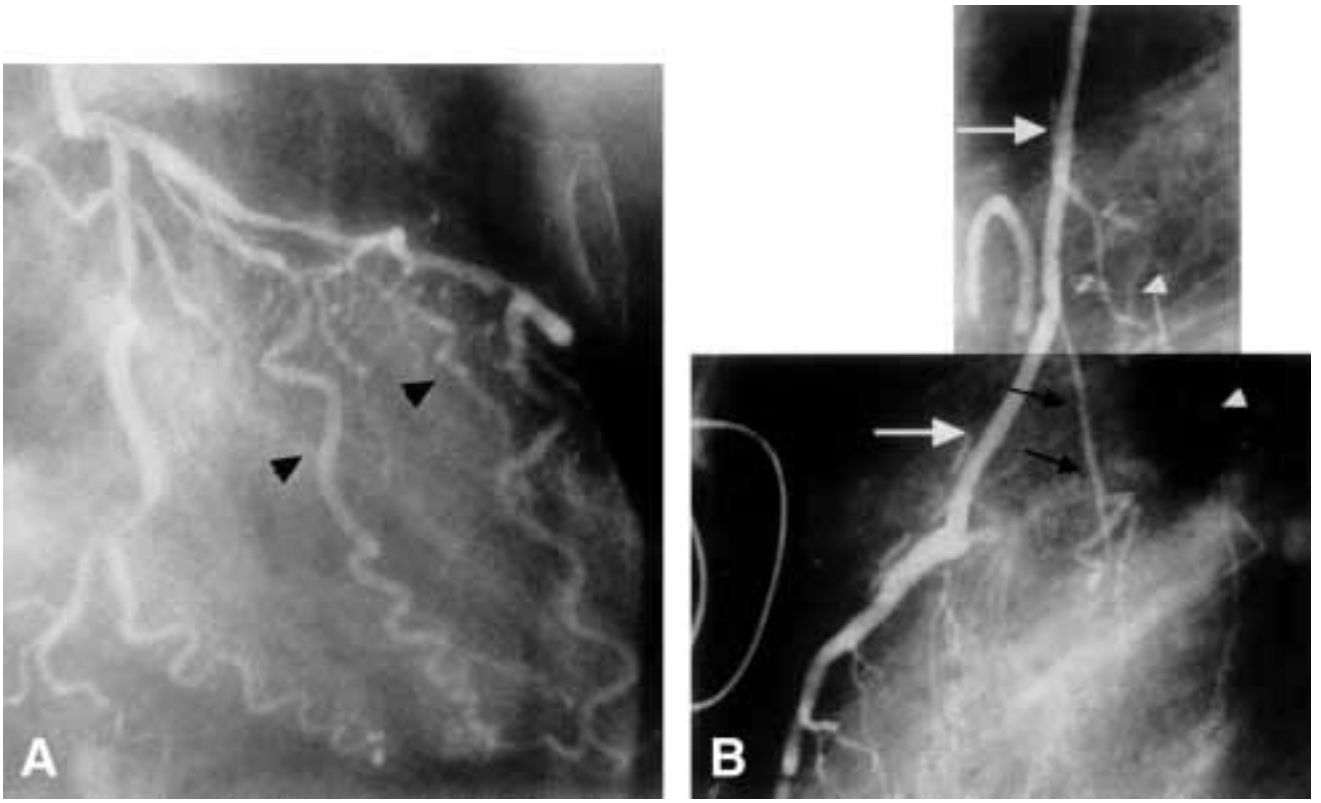

Fig. 1. Postoperative angiography revealed string sign in both the inferior epigastric artery and distal internal thoracic artery used as a branch conduit.
A: Preoperative angiogram. Arrowheads indicate the target vessels of the branch conduits.
B: Postoperative angiogram. White arrows indicate the in-situ left internal thoracic artery. White arrowheads indicate the inferior epigastric artery. Black arrows indicate the distal internal thoracic artery used as a branch conduit.

Table 2. Details of the patients with string branch conduits

Case	Branch conduit	Anastomotic site	Proximal stenosis (%)	Reason for string sign	Angiographic finding at 1 year after the operation
1	dLITA	Dx	75	Competitive flow	String sign
2	dLITA	LAD	90	Competitive flow	Unknown
3	dLITA	Dx	90	Competitive flow	Resolved
4	dLITA	Dx	99	Competitive flow	Resolved
5	dLITA	OM	90	Competitive flow	String sign
6	dLITA	Dx	90	Other	Occluded
7	dLITA	Dx	90	Poor run-off	String sign
	IEA	OM	50	Competitive flow	Occluded
8	IEA	Dx	75	Competitive flow	Resolved
9	RAG	Dx-PL	100-100	Poor run-off	Unknown

LAD=left anterior descending artery, Dx=diagonal branch OM=obtuse marginal branch, PL=postero-lateral branch

and 1 RAG exhibited the string sign (patent but diffuse narrowing) (Fig. 1). In seven of these grafts, the string sign was caused by competitive flow and in two by poor run-off (Table 2). All in-situ LITAs were patent (66/66). One in-situ LITA, which was anastomosed with RAG, exhibited string sign in this study. This string sign was observed only in the distal side of in-situ LITA after the anastomotic site with the composite RAG.

At one year after operation, seven of nine patients with string branch conduits underwent coronary angiography with informed consent. The string sign of composite grafts had resolved in three string branch conduits, three were

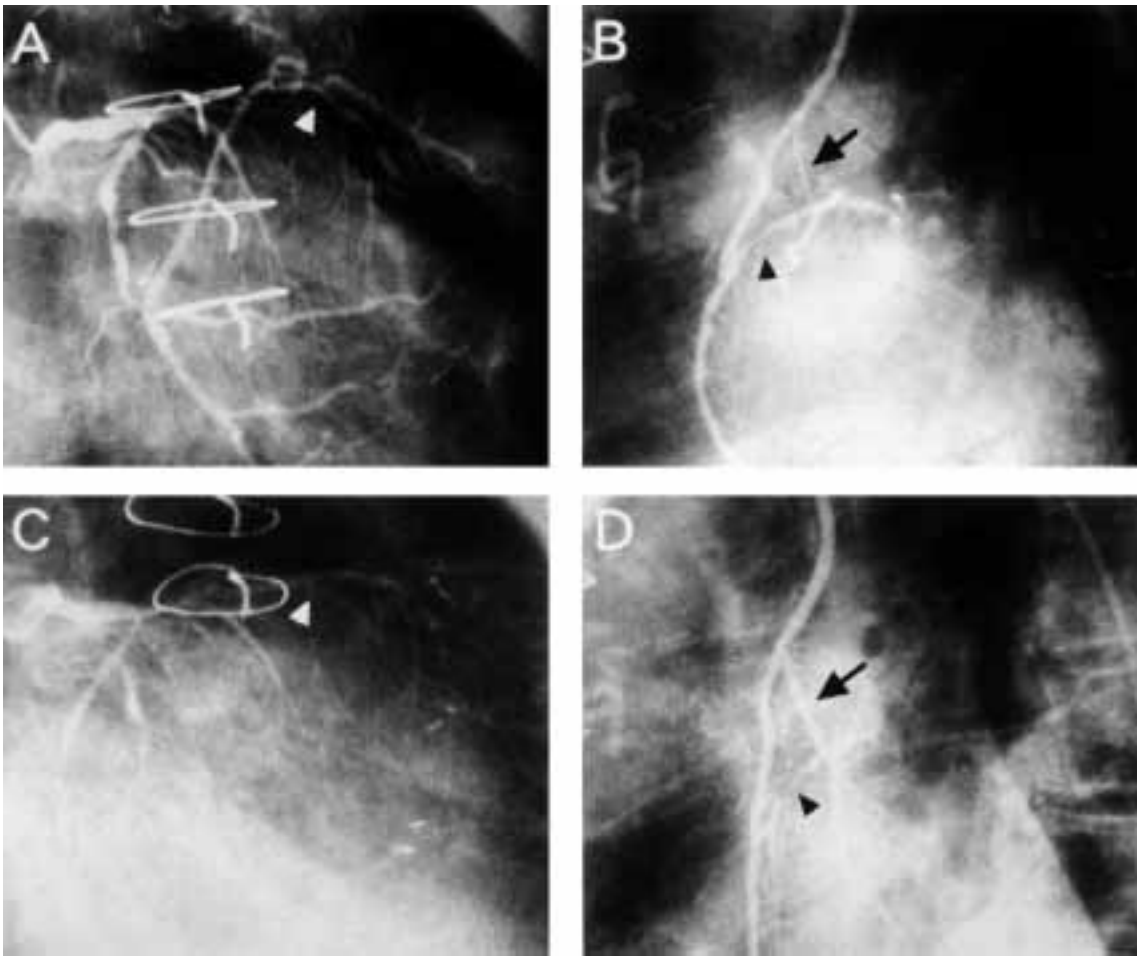

Fig. 2. Angiography of a distal internal thoracic artery graft used for the branch conduit (black arrow) demonstrating the string sign due to competitive flow in the early postoperative period, which was resolved at 1 year after operation.
A, B: Early postoperative angiography. Stenosis of the diagonal branch (white arrowhead) was mild and the diagonal branch filled with contrast medium from the in-situ left internal thoracic artery through the stenosis of the left anterior descending artery (black arrowhead).
C, D: Angiography at 1 year after operation demonstrating that the stenosis in the diagonal branch (white arrowhead) and the left anterior descending artery progressed (black arrowhead), and the string sign had resolved (black arrow).

unchanged, and two were totally occluded. In all resolved cases, the stenoses of the native coronary arterial anastomosed with a branch conduit had increased in severity and competitive flow was not observed at one year after operation (Fig. 2). None of the patients whose branch conduits showed the string sign developed perioperative myocardial infarction.

Follow-up

During a mean follow-up time of 23.7 months after the operation one patient died of acute aortic dissection, and two patients had cardiac events: one was angina pectoris due to progression of native coronary disease, and the other died of arrhythmia. However, none of the patients whose graft showed the string sign developed angina or myocardial infarction during the follow-up period.

Discussion

Recently, CABG using composite grafts as branches of an in-situ LITA has been adovocated by some authors.[4-8] In this study, we assessed the early angiographic results of various arterial grafts used as branch conduits of an in-situ LITA, and examined the clinical characteristics of these grafts. The overall operative and angiographic results of CABG using composite branch conduits have been

satisfactory in our hospital. Some authors have reported similar results for RAGs, RITAs, and IEAs used as branch conduits.[2,5,9] Tector et al.[5] reported that hypoperfusion was rarely observed even when complete bypass with a T graft was performed for patients with triple-vessel disease. In our study, hypoperfusion was also not observed with good follow-up results in all kinds of graft even in sequential grafting. Our results strongly suppport these successful reports.

Ten composite grafts exhibited the string sign in this study. The main cause of string sign was competitive flow. Some authors have demonstrated that the in-situ LITA can exhibit the string sign and its reversibility.[10-12] It has been suggested that the string sign is the result of competitive flow from a native coronary artery and results from the ability of the LITA to regulate blood flow according to myocardial demand.[13,14] The IEA has also been reported to exhibit the string sign.[15] ITA and IEA were similar in histologic characteristics, and may also have similar characteristics.[16,17] We suggest the dLITA, when used as a branch conduit, also has this characteristic. He[18] mentioned that the target vessel for the IEA must be one that is completely occluded or severely stenotic, with low coronary resistance to avoid string sign. Taking these facts into account, composite dLITA and IEA should also be used for such target vessels, in order to avoid the development of string sign. In this present study, some IEAs and dLITAs exhibited string sign caused by competitive flow, even when these grafts were used for the target vessels with stenosis of 90% or more. Thus, it is difficult to make an accurate estimate about string sign preoperatively. However, the string sign due to competitive flow can be resolved. It is supposed that the ability to regulate blood flow according to flow demand still remains even when these arterial grafts are used as a free graft. Since blood flow through branch conduits with the string sign may increase over time as the native coronary artery stenosis progresses, it may be feasible to observe and follow patients with branch conduits exhibiting the string sign in the absence of ischemia.

The patency of in-situ LITA was excellent in this present study. Only one in-situ LITA exhibited string sign in this study. This string sign was observed only in the distal side of in-situ LITA after anastomotic site with the composite RAG in sequential grafting. Some authors reported the steal phenomenon caused by an undivided large branch of in-situ ITA.[19] According to this report, the in-situ ITA became thinned after bifurcation of the large branch with a large flow demand. Since composite branch RAG conduit, in sequential grafting, may have a high flow demand, it can function in the same way as an undivided large branch.

In summary, the early clinical and angiographical results of CABG using composite grafts as branches of the in-situ LITA were good. Branch conduits should be used for target vessels that are completely occluded or are severely stenotic with a low coronary resistance in order to avoid the development of the string sign. Since the string sign in the branch conduits can resolve over time as the proximal stenosis increases in severity, it is feasible to observe and follow the patients in the absence of ischemia.

References

1. Acar C, Jebara V, Portoghese M, et al. Revival of the radial artery for coronary artery bypass grafting. *Ann Thorac Surg* 1992; **54**: 652–60.
2. Puig LB, Ciongolli W, Cividanes GV, et al. Inferior epigastric artery as a free graft for myocardial revascularization. *J Thorac Cardiovasc Surg* 1990; **99**: 251–5.
3. Pym J, Brown PM, Charrette EJ, Parker JO, West RO. Gastroepiploic-coronary anastomosis: a viable alternative bypass graft. *J Thorac Cardiovasc Surg* 1987; **94**: 256–9.
4. Calafiore AM, Di Giammarco G, Luciani N, Maddestra N, Di Nardo E, Angelini R. Composite arterial conduits for a wider arterial myocardial revascularization. *Ann Thorac Surg* 1994; **58**: 185–90.
5. Tector AJ, Amundsen S, Schmahl TM, Kress DC, Peter M. Total revascularization with T grafts. *Ann Thorac Surg* 1994; **57**: 33–9.
6. Barner HB, Naunheim KS, Fiore AC, Fischer VW, Harris HH. Use of the inferior epigastric artery as a free graft for myocardial revascularization. *Ann Thorac Surg* 1991; **52**: 429–37.
7. Puskas JD, Wright CE, Ronson RS, Brown WM III, Gott JP, Guyton RA. Off-pump multivessel coronary bypass via sternotomy is safe and effective. *Ann Thorac Surg* 1998; **66**: 1068–72.
8. Calafiore AM, Teodori G, Di Giammarco G, et al. Multiple arterial conduits without cardiopulmonary bypass: early angiographic results. *Ann Thorac Surg* 1999; **67**: 450–6.
9. Tatoulis J, Buxton BF, Fuller JA. Results of 1,454 free right internal thoracic artery-to-coronary artery grafts. *Ann Thorac Surg* 1997; **64**: 1263–9.
10. Dincer B, Barner HB. The “occluded” internal mammary artery graft: restoration of patency after apparent occlusion associated with progression of coronary disease. *J Thorac Cardiovasc Surg* 1983; **85**: 318–20.
11. Kitamura S, Kawachi K, Seki T, Sawabata N, Morita R, Kawata T. Angiographic demonstration of no-flow anatomical patency of internal thoracic-coronary ar-

tery bypass grafts. *Ann Thorac Surg* 1992; **53**: 156–9.
12. Aris A, Borrás X, Ramió J. Patency of internal mammary artery grafts in no-flow situations. *J Thorac Cardiovasc Surg* 1987; **93**: 62–4.
13. Cosgrove DM, Loop FD, Saunders CL, Lytle BW, Kramer JR. Should coronary arteries with less than fifty percent stenosis be bypassed? *J Thorac Cardiovasc Surg* 1981; **82**: 520–30.
14. Tector AJ, Schmahl TM, Janson B, Kallies JR, Johnson G. The internal mammary artery graft: its longevity after coronary bypass. *JAMA* 1981; **246**: 2181–3.
15. Calafiore AM. Use of the inferior epigastric artery for coronary revascularization. In: Cox JL, Sundt TM III, eds.; Operative Techniques in Cardiac & Thoracic Surgery 1. Philadelphia: W. B. Saunders Company, 1996; pp 147–59.
16. van Son JA, Smedts F. Histology of the internal mammary artery versus the inferior epigastric artery. *Ann Thorac Surg* 1992; **53**: 1147–9.
17. van Son JA, Smedts F, Vincent JG, van Lier HJ, Kubat K. Comparative anatomic studies of various arterial conduits for myocardial revascularization. *J Thorac Cardiovasc Surg* 1990; **99**: 703–7.
18. He GW. Arterial grafts for coronary artery bypass grafting: biological characteristics, functional classification, and clinical choice. *Ann Thorac Surg* 1999; **67**: 277–84.
19. Gaudino M, Serricchio M, Glieca F, et al. Steal phenomenon from mammary side branches: when does it occur? *Ann Thorac Surg* 1998; **66**: 2056–62.