Original Article

A Modified Infarct Exclusion Technique for a Post-infarction Ventricular Septal Defect

Takashi Hirotani, MD, and Tsukasa Nakamichi, MD

Background: Operative mortality for a post-infarction ventricular septal defect (VSD) remains high. The infarct exclusion technique has been producing a favorable outcome for repairing this serious defect. However, there is the technical weakness, namely running suture along the base of the necrotic septum. We sutured a pericardial patch using multiple interrupted mattress sutures in such a manner as to exclude the infarct and VSD.
Methods: Over the past seven years, nine consecutive patients with a post-infarction VSD underwent an early repair in the same manner. The VSD was anterior in eight patients and posterior in one. We sutured a xenopericardial patch to the healthy myocardium around the infarct using interrupted mattress sutures instead of running sutures as the infarct exclusion technique. In addition, on the postero-inferior margin of the patch, one or two mattress sutures passing through the full thickness of the anterior papillary muscle were used.
Results: Only one patient died of pneumonia 50 days after surgery. The other eight patients were followed up and were functionally classified as NYHA class I or II.
Conclusions: These findings suggest that our modified infarct exclusion technique using multiple mattress sutures is an effective alternative surgical technique. (Ann Thorac Cardiovasc Surg 2002; 8: 281–5)

Key words: ventricular septal defect, acute myocardial infarction, infarctectomy, infarct exclusion technique

Introduction

Since Cooley and colleagues first successfully performed a surgical repair of a post-infarction ventricular septal defect (VSD),[1] steady progress has been made in the surgical management of this serious complication of an acute myocardial infarction, but the operative mortality for the early repair of post-infarction VSD remains unacceptably high. Some recent reports have indicated that preoperative right ventricular dysfunction was one of the most important risk factors for the surgical repair of a post-infarction VSD[2-4] and that surgical techniques with either no infarctectomy of the ventricular septum, or only a limited one, preserved the right ventricular function and led to a good survival[5-7]. The infarct exclusion technique, which was originally described by Komeda, Fremes and David,[8] also needed no infarctectomy, and its reported surgical results seemed better than those when more conventional techniques with a sufficient infarctectomy[9] were used. However, in the infarct exclusion technique, a running suture used for suturing a patch may tear especially along the base of the ventricular septum. These considerations led us to suture a patch to the healthy myocardium around the infarct using multiple interrupted mattress sutures with large pledgets. In addition, in the postero-inferior margin of the pericardial patch, one or two mattress sutures passing through the full thickness of the anterior papillary muscle were used to fasten this patch onto the ventricular septum. This article reports the results of nine consecutive patients with post-infarction VSD undergoing an early surgical repair using this technique.

From Department of Cardiovascular Surgery, Tokyo Saiseikai Central Hospital, Tokyo, Japan

Received July 8, 2002; accepted for publication July 25, 2002.
Address reprint requests to Takashi Hirotani, MD: Department of Cardiovascular Surgery, Tokyo Saiseikai Central Hospital, 1-4-17 Mita, Minato-ku, Tokyo 108-0073, Japan.

Materials and Methods

Patients

From September 1993 through May 2000, nine consecutive patients were referred to us for surgical treatment. No offers for surgery were rejected during this period. Patient data of these nine subjects were prospectively collected, and the current status of the survivors was ascertained by checking with the attendant cardiologists.

The subjects consisted of 5 men and 4 women ranging in age from 58 to 84 years (mean 73.8 years). The VSD was diagnosed by the detection of an additional systolic heart murmur from 1 to 12 days (mean 1.9 days) after occurrence of an acute myocardial infarction. The operation was performed from 1 to 10 days (mean 4.1 days) after the diagnosis of VSD and from 2 to 15 days (mean 7.6 days) after occurrence of an acute myocardial infarction. An anterior VSD was found in eight patients and a posterior VSD was observed in one. All patients were managed with an intra-aortic balloon pump (IABP) preoperatively. All but two patients also received some inotropic support to maintain adequate blood pressure. All patients were either oliguric or anuric, and one patient required peritoneal dialysis before undergoing surgery.

All patients underwent preoperative coronary angiography. Regarding the types of coronary artery disease, one patient had left main, one had three-vessel, one had two-vessel and six had one-vessel coronary artery disease. Five of these patients also underwent contrast left ventriculography preoperatively, which revealed the left ventricular ejection fraction to range from 26 to 60% (mean 43%). The findings of preoperative echocardiography revealed four patients with a severely impaired left ventricular function and two patients with a severely impaired right ventricular function. In all patients, the left-to-right shunt was measured by oximetry and the value ranged from 2.5 to 4.5 (mean 3.3). All but one patient was operated on urgently. One patient was operated on emergently because of cardiac arrest. He was resuscitated and placed on a cardiopulmonary bypass immediately in the operating room and subsequently underwent a surgical repair of VSD.

Surgical techniques

All operations were performed by one surgeon and the VSD was repaired in the same manner. Total cardiopulmonary bypass (CPB) was established with ascending aortic and bicaval cannulation in all cases. CPB was performed under moderate hypothermia (28°C) and the left ventricle was drained through the right superior pulmonary vein. Cardiac arrest was induced by antegrade crystalloid cardioplegia. In cases of anterior VSD, an incision was made in the apex of the left ventricle parallel to the anterior descending artery 1 cm from it. In one case of posterior VSD, the apex was lifted and an incision was made in the mid-portion of the inferior wall parallel to the posterior descending artery 5 mm from it. Through the left ventriculotomy, the VSD was closed using multiple monofilament interrupted mattress sutures with large pledgets of Teflon felt which were placed on the left ventricular side of the septum as far away from the rim of the infarcted area as possible. A double xenopericardial patch was used to cover the VSD and necrotic septum around the VSD. In the postero-inferior margin of the pericardial patch, one or two mattress sutures passing through the full thickness of the anterior papillary muscle were used. The ventriculotomy was closed with interrupted Teflon felt-reinforced mattress sutures. In one case of posterior VSD, the left ventricular free wall was reconstructed with a tailored Dacron prosthetic graft in cases of posterior VSD as described by Daggett et al.[9] The details of the technique are shown in Fig. 1. Myocardial revascularization was performed in six patients. The bypassed arteries were 2 left anterior descending arteries, 3 diagonal branches, 4 left circumflex arteries and 2 right coronary arteries. The internal thoracic arteries were unilaterally used in three patients and bilaterally in one, while in the remaining two patients, saphenous vein grafts alone were used. The mean number of distal anastomoses, expressed as the mean±standard deviation, was 1.2±1.0 (range, 1-3). In one patient with a posterior VSD, a mitral valve replacement was concomitantly performed because the infarct involved the posterior papillary muscle. The mean aortic cross-clamping time, expressed as the mean±standard deviation, was 137±28 minutes (range, 100-170 minutes).

Results

Operative mortality and morbidity

All patients showed an improved hemodynamic performance after completion of repairs of VSD and they were weaned from CPB without any great difficulty. No patients demonstrated any excessive bleeding from the left ventriculotomy site either during or after the operations. Although all patients required the support of IABP in the postoperative period, all but one could be weaned from it within 12 hours. Only one patient, who had a significant

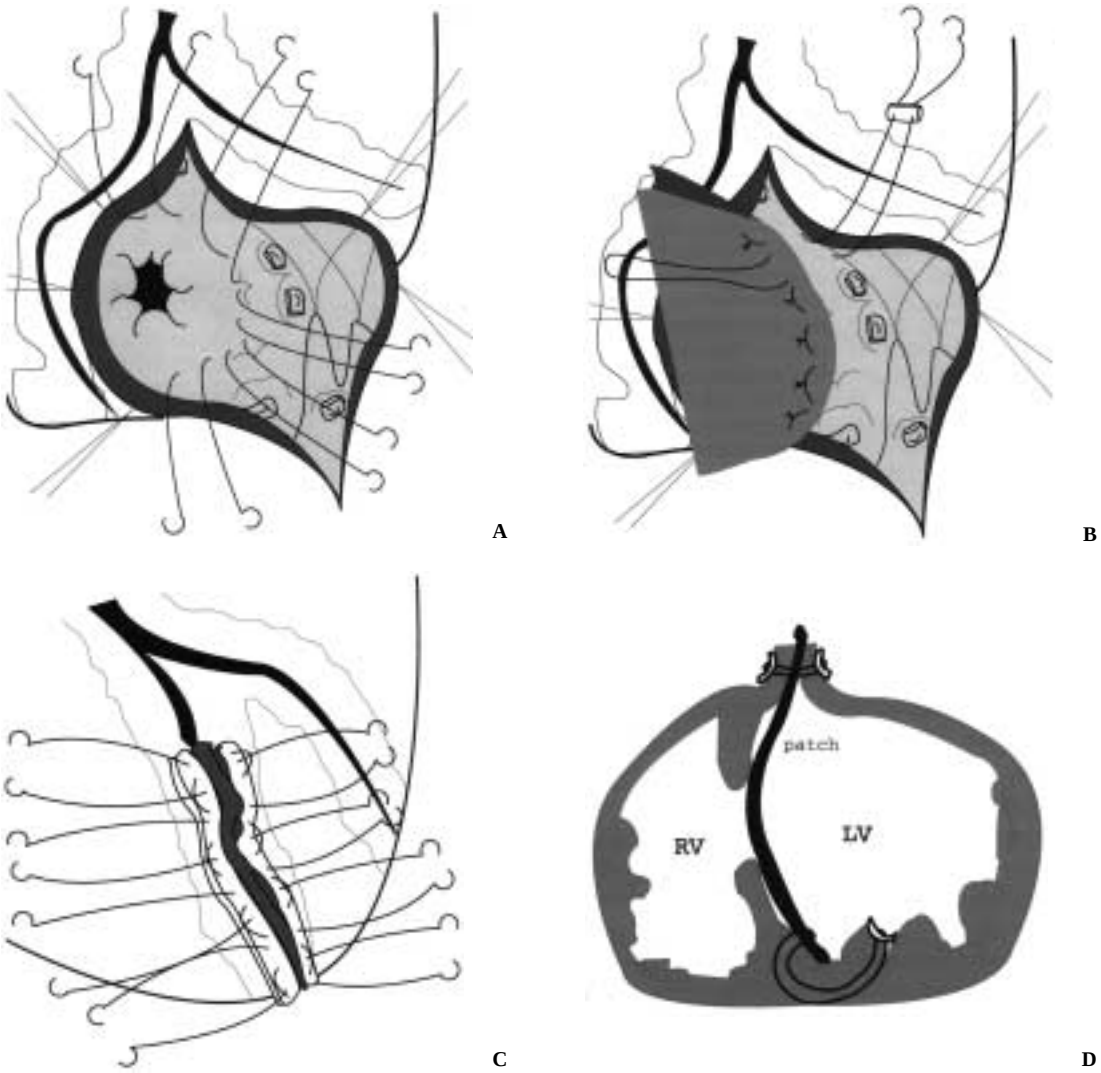

Fig. 1. Repair of an anterior VSD. A: Monofilament interrupted mattress sutures with wide bites are anchored as far away from the rim of the infarcted area as possible. B: A double xenopericardial patch is sutured to the ventricular septum. The base of the patch is sutured to the myocardium just below the mitral annulus, while the needles often have to be inserted from the patch side, namely the reverse direction to the other sutures. C: A left ventriculotomy in the infarcted myocardium is closed with interrupted Teflon felt-reinforced mattress sutures. The septal patch is incorporated in the repair in a sandwich fashion. D: A cross-section of the heart showing a complete repair of an anterior VSD.

residual VSD with a left-to-right shunt measuring 1.8 and who therefore underwent an urgent reoperation two days after the initial operation, continued to receive IABP support until the second operation.

No patients died within 30 days of operation. However, one 82-year-old patient, who underwent a reoperation for repairing a residual VSD died of pneumonia 50 days after the operation. The other eight patients were discharged without any deficit and were followed up postoperatively for an average of 4.8 years (range, 2 to 9 years). All patients were followed up monthly by the attendant cardiologists and none of these

patients had any cardiac events including additional myocardial infarction, congestive heart failure requiring hospitalization, coronary intervention and/or reoperation. All patients are functionally classified as New York Heart Association (NYHA) class I or II at the time of this report.

Postoperative complications were common. All patients required inotropic support for from 1 to 10 days (mean 4.2 days) after surgery. Five patients required assisted ventilation for more than 48 hours. One patient, who received peritoneal dialysis before surgery, also required it for seven days after surgery. One patient underwent an implantation of a permanent pacemaker because of an advanced AV block.

Discussion

Post-infarction VSD is a serious complication of an acute myocardial infarction. Many cardiovascular surgeons have contributed to the improvement of the surgical results, while the majority of reported operative mortalities has been high, ranging from 13 to 38%.[5,10-12] According to analyses of the operative risk factors, an early repair after infarction, cardiogenic shock and inferior VSD were usually indicated as predictors of mortality,[3,13,14] while in some reports, the importance of preserving the right ventricular function has also been indicated.[5] We paid special attention to the contribution of the ventricular septum to the right ventricular function and we tried to preserve the right ventricular function like the infarct exclusion technique by not resecting the infarcted ventricular septum and by not incising the right ventricle.

Skillington et al. performed a minimal debridement of the ventricular septum and reported good operative results with an operative mortality of 20.8%.[12] Da Silva et al. used a new repair technique which stressed that no part of the infarcted ventricular septum be resected, and they also reported that this technique was used for seven consecutive patients with an operative mortality of 14.3%.[6] Massetti et al. repaired VSD through the right atrial approach without either a right or left ventriculotomy in selected patients and their operative mortality was 25%.[7]

The infarct exclusion technique can also leave the right ventricle undisturbed, and according to the most recent report,[5] the operative mortality was only 13.4%. However, in this technique, there is the weak point along the base of the ventricular septum where a running suture used for suturing a patch may tear. It seems that this technique is rather technically demanding and the problem of residual shunt occurs with unacceptably high frequency such as reported by other authors[14] than by David et al. To overcome these weak points of the infarct exclusion technique, we used multiple interrupted mattress sutures, and in the postero-inferior margin of the pericardial patch, we utilized the anterior papillary muscle for suturing the patch firmly enough to the fragile septum.

There are limitations to our findings since no randomized prospective study was carried out, and the number of subjects was too small to make any definitive conclusions about this surgical method. In addition, our series included only one posterior VSD, which has been indicated as a risk factor for repairing post-infarction VSDs by many reports. So, our good survival rate may be attributed to the fact that our series was heavily weighted toward the anterior VSD. However, we thought that both preserving the right ventricular function by not resecting any part of the ventricular septum and securely closing the VSD by covering it tightly and strongly with a patch material using multiple interrupted mattress sutures, which were placed on the left ventricular side of the septum, are important determinants in the outcome of patients with post-infarction VSD.

Conclusion

The repair for a post-infarction VSD through the left ventriculotomy without a septal infarctectomy using multiple interrupted mattress sutures is considered to be an effective alternative technique.

References

1. Cooley DA, Belmonte BA, Zels LB, Schnur S. Surgical repair of ruptured interventricular septum following acute myocardial infarction. *Surgery* 1957; **41**: 930–7.
2. Fananapazir L, Bray CL, Dark JF, Moussalli H, Deiraniya AK, Lawson RAM. Right ventricular dysfunction and surgical outcome in postinfarction ventricular septal defect. *Eur Heart J* 1983; **4**: 155–67.
3. Cummings RG, Reimer KA, Califf R, Hackel D, Boswick J, Lowe JE. Quantitative analysis of right and left ventricular infarction in the presence of postinfarction ventricular septal defect. *Circulation* 1988; **77**: 33–42.
4. Angelini GD, Penny WJ, Ruttley MST, Butchart EG, West RR, Henderson AH. Post-infarction ventricular septal defect: the importance of right ventricular coronary perfusion in determining surgical outcome. *Eur J Cardiothorac Surg* 1989; **3**: 156–61.

5. David TE, Dale L, Sun Z. Postinfarction ventricular septal rupture: repair by endocardial patch with infarct exclusion. *J Thorac Cardiovasc Surg* 1995; **110**: 1315–22.
6. da Silva JP, Cascudo MM, Baumgratz JF, Vila JH, Macruz R. Postinfarction ventricular septal defect. An efficacious technique for early surgical repair. *J Thorac Cardiovasc Surg* 1989; **97**: 86–9.
7. Massetti M, Babatasi G, Page OL, Bhoyroo S, Saloux E, Khayat A. Postinfarction ventricular septal rupture: early repair through the right atrial approach. *J Thorac Cardiovasc Surg* 2000; **119**: 784–9.
8. Komeda M, Fremes SE, David TE. Surgical repair of postinfarction ventricular septal defect. *Circulation* 1990; **82** (Suppl IV): 243–7.
9. Daggett WM, Buckley MJ, Akins CW, et al. Improved results of surgical management of postinfarction ventricular septal rupture. *Ann Surg* 1982; **196**: 269–77.
10. Jones MT, Schofield PM, Dark JF, et al. Surgical repair of acquired ventricular septal defect. Determinants of early and late outcome. *J Thorac Cardiovasc Surg* 1987; **93**: 680–6.
11. Blanche C, Khan SS, Matloff JM, et al. Results of early repair of ventricular ventricular septal defect after an acute myocardial infarction. *J Thorac Cardiovasc Surg* 1992; **104**: 961–5.
12. Skillington PD, Davies RH, Luff AJ, et al. Surgical treatment for infarct-related ventricular septal defects. Improved early results combined with analysis of late functional status. *J Thorac Cardiovasc Surg* 1990; **99**: 798–808.
13. Loisance DY, Cachera JP, Poulain H, Aubry P, Juvin AM, Galey JJ. Ventricular septal defect after acute myocardial infarction: Early repair. *J Thorac Cardiovasc Surg* 1980; **80**: 61–7.
14. Ichihara T, Asakura T, Ishida H, Sakai Y, Yasuura K. The investigation of surgical procedures for post infarcted ventricular septal defects: a comparison between Daggett and David method. *Kyobu Geka* 1998; **51**: 1110–3. (in Japanese)