Case Report

New Surgical Technique of Left Ventricular Free Wall Rupture: Double Patch Sealing Method

Hideki Amano, MD, Kuniyoshi Ohara, MD, Masaki Nie, MD, Shinzo Torii, MD, Yutaka Miyoshi, MD, and Hirokuni Yoshimura, MD

We experienced two cases of left ventricular free wall rupture (LVFWR) following acute myocardial infarction (AMI). Case 1, with the blowout type of LVFWR was initially closed by direct suture, followed by hemostasis using a double patch sealing method (DPS) by which the tear was doubly sealed with large and small bovine pericardium patches to which GRF glue® was applied. Case 2 with the oozing type of LVFWR was treated only using DPS. Complete hemostasis was achieved in both cases, and aneurysmal dilatation or constrictive heart failure were not detected by postoperative left ventriculography. Therefore, DPS may be useful for treating LVFWR following AMI. (Ann Thorac Cardiovasc Surg 2002; 8: 389–92)

Key words: left ventricular free wall rupture, acute myocardial infarction, double patch sealing method, GRF glue®

Introduction

Left ventricular free wall rupture (LVFWR) is the most life-threatening complication in acute myocardial infarction (AMI). In particular, it is difficult to save the life of patients with the blowout type of LVFWR. Although various surgical techniques for LVFWR have been reported previously, we used the double patch sealing method (DPS) in two patients, resulting in complete hemostasis.

Case Report

Case 1

A 76-year-old woman with chest pain was admitted. The electrocardiogram (ECG) showed ST elevation in leads V2-5 and QS pattern in leads V1-3. Anterior myocardial infarction was diagnosed. Coronary angiography was performed and revealed total occlusion of the left anterior descending artery (LAD). On the day of admission, the patient suddenly fell into a state of electromechanical dissociation (EMD) during percutaneous transluminal coronary angioplasty (PTCA) for the LAD. Therefore, intraaortic balloon pumping (IABP) and percutaneous cardiopulmonary support (PCPS) were performed under cardiopulmonary resuscitation. Pericardial effusion was detected by echocardiography and diagnosed cardiac rupture.

When the pericardium was opened after median sternotomy, a tear 2 cm in diameter was observed in the center of the LV anterior wall 2 cm outside the LAD. Under cardiac arrest, the tear was doubly closed using a 4-0 polypropylene horizontal mattress and over and over suture before further hemostasis with large and small bovine pericardium patches (10.0×10.0, 6.0×4.0 cm) to which GRF glue® was applied (Fig. 1). After treatment, bleeding from the ruptured site was not observed. The hemodynamics gradually improved postoperatively. But the patient died of brain damage on the 11th postoperative day (POD), probably due to about a 10 minutes period of EMD before the start of PCPS.

Case 2

A 72-year-old man with chest pain was admitted. Although he took a sublingual nitroglycerin tablet, chest pain was not relieved. ECG showed abnormal Q wave in leads II, III, aVf, QS pattern in leads V1-4, and ST elevation in leads V2-5. Anterior and right inferior myocardial infarction was diagnosed. Coronary angiography was per-

From Department of Thoracic and Cardiovascular Surgery, Kitasato University School of Medicine, Kanagawa, Japan

Received January 10, 2002; accepted for publication September 8, 2002.
Address reprint requests to Kuniyoshi Ohara, MD: Department of Thoracic and Cardiovascular Surgery, Kitasato University School of Medicine, 1-15-1 Kitasato, Sagamihara, Kanagawa 228-8555, Japan.

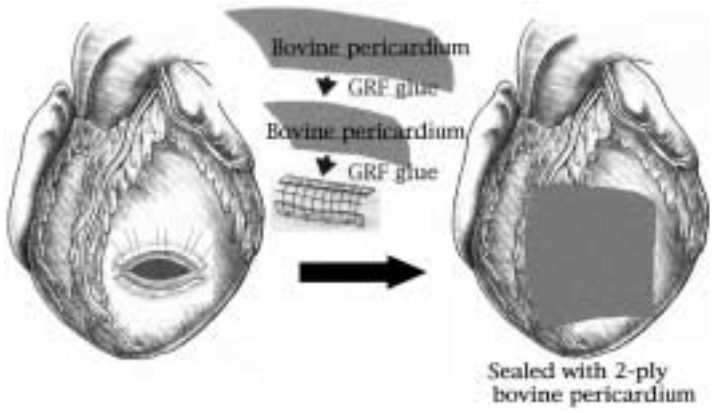

Fig. 1. Surgical technique used to treat the blow out type of LVFWR.
The tear measuring 2 cm in diameter was observed in the center of the LV anterior wall and 2 cm outside the LAD. The margin of the infarct myocardium was removed, and the tear was doubly closed using a 4-0 polypropylene horizontal mattress and over and over suture. Furthermore, hemostasis of the sutured site was secured by doubly attaching bovine pericardial patches to which GRF glue® was applied.

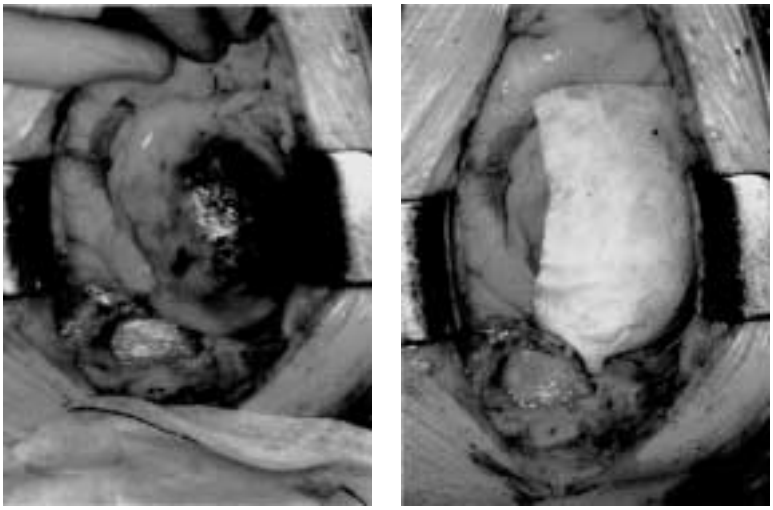

A | B

Fig. 2. Intraoperative findings.
Since broad myocardial infarction was observed in the anterior wall of the LV free wall, a diagnosis of oozing type cardiac rupture in the LAD was established (A). The tear was doubly closed with bovine pericardium to which GRF glue® was applied before the adhesion of autologous pericardium with GRF glue® (B).

formed and revealed total occlusion of the LAD and 75% stenosis of the right coronary artery. After PTCA, total occlusion of LAD was improved to 50% stenosis. Hypotension and tachycardia were observed early the next morning. In addition, pericardial effusion was detected by echocardiography and diagnosed cardiac rupture.

Operation was performed under partial extracorporeal circulation using PCPS. Fresh blood with coagulation was collected in the pericardium, and broad myocardial infarction was observed in the anterior wall of left ventricle. Therefore, the diagnosis of oozing type LVFWR was made, and closed with large and small bovine pericardium patches (10.0×10.0, 6.0×6.0 cm) to which GRF glue® was applied. Further hemostasis was performed by adhering autologous pericardia with GRF glue® over the bovine pericardium patches, resulting in complete hemostasis of the ruptured site (Fig. 2). The hemodynamics were stabilized postoperatively. Postoperative left ventriculography did not show any signs of aneurysmal dilatation (Fig. 3A, B). Left ventricular end diastolic pressure (LVEDP) was improved from 22 to 14 mmHg, and ejection fraction (EF) was improved from 37 to 41%. The patient was discharged on the 42nd POD.

Discussion

The mortality of patients with LVFWR after AMI is very high. LVFWR is roughly classified into the following three types: blowout type, oozing type, and pseudoaneurysm type.[1)] Differing from the oozing type, only a few cases of blowout type LVFWR have been treated successfully because of the brain damage caused by the state of shock

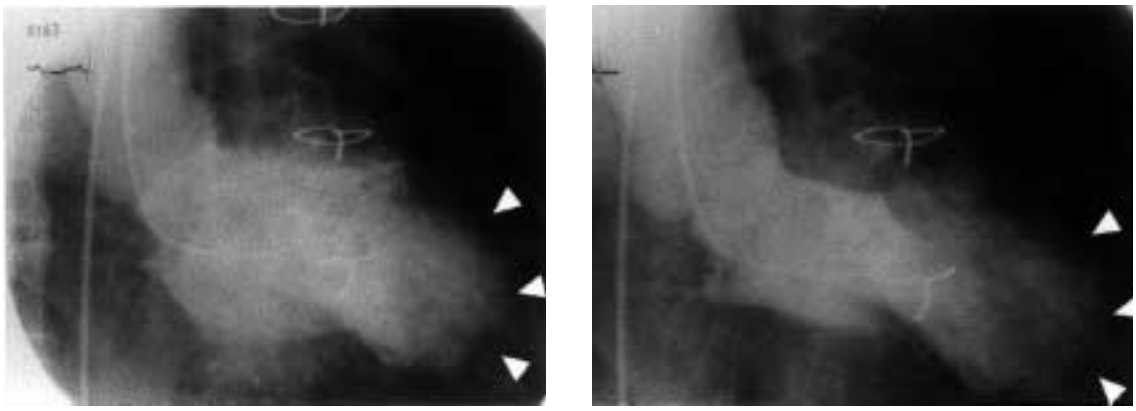

A B

Fig. 3. Postoperative left ventriculography after surgery.
A: diastolic phase, B: systolic phase. Neither aneurysmal dilatation nor diastolic failure of the left ventricle was noted.

and the difficulty in closing the tear with the fragile surrounding tissue. Before the development of PCPS, the hemodynamics in patients with LVFWR were maintained only by the use of artificial heart-lung machines. A few patients with the blowout type were saved previously when they were treated by the following procedures: emergency intercostal open-chest drainage on a bed followed by direct suturing of the tear or patch closure under extracorporeal circulation.[2] After the introduction of PCPS, the hemodynamics in patients with LVFWR can be easily and rapidly maintained. Therefore, many such patients who might be dead before being transferred to an operating room can be saved by emergency surgery.

Case 1 fell into a state of EMD without a heartbeat despite the use of PCPS and IABP. However, the hemodynamics were maintained in this patient by returning the fresh blood drained from the pericardial cavity to the PCPS. Though the tear was repaired successfully, the patient developed brain damage postoperatively due to the prolonged duration of cerebral ischemia for over 10 minutes before the start of PCPS.

In 1972, FitzGibbon et al. first reported a case of cardiac rupture successfully treated by suturing the myocardium using Teflon patches after the removal of the infarcted myocardium.[3] In addition, Cobbs et al. reported a case of LVFWR successfully saved by suturing the tear with Teflon patches without using extracorporeal circulation.[4] The other surgical techniques for LVFWR include the following procedures: closure of the tear with a felt sandwich; myocardial suture after the removal of the infarct myocardium; and suture of the tear continuously with the healthy myocardium after attaching a large patch to the outer wall of the infarct myocardium, including the tear. However, hemostasis is difficult to achieve because the infarcted myocardium should also be sutured to directly close the tear. In addition, closure of the tear after removing the infarct myocardium may decrease the LV volume. In 1983, Nunez et al. reported surgically treating four patients with subacute LVFWR by directly suturing Teflon patches to the tear on a beating heart under extracorporeal circulation.[5] Padro et al. reported surgically treating 13 patients with subacute LVFWR by adhering Teflon patches (8.0×5.0 cm) to the tear with buthyl-2-cyanoacrylate monomer (Histoacry blue), and reported that all of these patients were saved with favorable prognosis.[6] Noda et al. reported a histopathological examination of the repair of LVFWR using GRF glue®.[7] GRF glue® made a tight adhesion between the bovine pericardium patch and myocardium and endured cardiac pressure. They concluded that GRF glue® constitutes effective histocompatibility and hemostasis. Though GRF glue® has been used in the repair of acute aortic dissection we have never experienced problems postoperatively.

Though the patch size was different to the infarct size, the patch was applied to the extensive healthy myocardium, from the anterior wall to the apex in the center of the tear, to enhance complete adhesion. In case 1 with the blowout type, the tear was initially closed by direct suture, followed by double hemostasis by DPS using large and small bovine pericardium patches to which GRF glue®

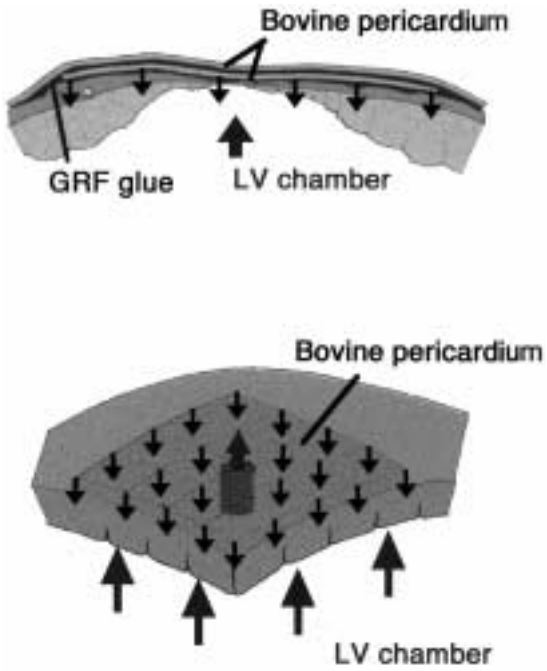

Fig. 4. Schema of the hemostatic mechanism of DPS (cited from Ref. 8).
The tear with the weak surrounding tissue was securely closed because the entire surface of these patches supported and distributed ventricular pressure focusing on the ruptured site alone.

was applied. In case 2 with the oozing type, the tear was initially closed using DPS. In both cases, complete hemostasis was achieved by DPS. The mechanism of hemostasis by DPS is to distribute ventricular pressure while the entire surface of these patches supported cardiac pressure focusing on the ruptured site alone (Fig. 4).[8] This hemostasis is much stronger than a sheet of patch. Compared with inframectomy and subsequent closure of the defect by suture, DPS is characterized by the following two advantages; 1. DPS does not decrease the LV volume, 2. DPS does not damage the myocardium and coronary artery.

There is no report about the risk of bovine spongiform encephalopathy (BSE) after using GRF glue®. If it is risky, we are going to use another material such as autologous pericardia or artificial pericardium.

Patients with LVFWR surgically treated by DPS may have the complication of a ventricular aneurysm postoperatively. From the perspective of a clinical diagnosis based on the results of left ventriculography, we defined that the LV aneurysm is an apparent bulging from the original LV shilhouette throughout the cardiac cycle. In case 2, apparent bulging of the LV wall was not observed, although asynergy was detected by postoperative left ventriculography during the systolic and diastolic phases. After surgery, LVEDP was improved from 22 to 14 mmHg, and EF was improved from 37 to 41%. The postoperative course of this patient will be necessary to follow up from now on.

Conclusion

We experienced two cases of LVFWR. Complete hemostasis was achieved in both cases by DPS, and no signs of aneurysmal dilation or constrictive heart failure of the left ventricle were detected by postoperative study. Therefore, this surgical technique may be useful for treating LVFWR following AMI.

References

1. Bashour T, Kabbani SS, Ellertson DG. Surgical salvage of heart rupture: report of two cases and review of the literature. *Ann Thorac Surg* 1983; **36**: 209–13.
2. Masai T, Sakakibara T, Watanabe S, et al. A case report of successful surgical treatment following the emergency circulatory assist by percutaneous cardiopulmonary support system for acute postinfarction left ventricular free wall rupture. *Nippon Kyobu Geka Gakkai Zasshi* 1992; **40**: 86–90. (in Japanese)
3. FitzGibbon GM, Hooper GD, Heggtveit HA. Successful surgical treatment of postinfarction external cardiac rupture. *J Thorac Cardiovasc Surg* 1972; **63**: 622–30.
4. Cobbs BW Jr, Hatcher CR Jr, Robinson PH. Cardiac rupture. Three operations with two long-term survivals. *JAMA* 1973; **223**: 532–5.
5. Nunez L, de la Llana R, Lopez Sendon J, Coma I, Aguado GM, Larrea JL. Diagnosis and treatment of subacute free wall rupture after infarction. *Ann Thorac Surg* 1983; **35**: 525–9.
6. Padro JM, Mesa JM, Silvestre J, et al. Subacute cardiac rupture: repair with sutureless technique. *Ann Thorac Surg* 1993; **55**: 20–4.
7. Noda H, Fujimura Y, Ikeda Y, et al. Repair of left ventricular free wall rupture with GRF glue associated with acute myocardial infarction: report of case. *Kyobu Geka* 1998; **51**: 67–71. (in Japanese)
8. Tsukui H, Ohara K, Akimoto T, et al. Case report of surgical repair of left ventricular free wall rupture using GRF glue and pericardial patch. *Jpn J Thorac Cardiovasc Surg* 1998; **46**: 898–901. (in Japanese)