Case Report

Clinical Features of Medical Pneumomediastinum

Hiroyuki Miura, MD, PhD,[1] Osamu Taira, MD, PhD,[1] Shunsuke Hiraguri, MD, PhD,[1] Keiji Ohtani,[1] and Harubumi Kato, MD, PhD,[2]

Purpose: The clinical features of pneumomediastinum are clarified.
Methods: Eight patients with pneumomediastinum, caused by other than trauma or operative, diagnostic, or therapeutic trouble (medical pneumomediastinum), were studied retrospectively.
Results: There were seven men and one woman with an average age of 17.5 years. The incidence was about 1:320 in thoracic surgical inpatients. The causes were bronchial asthma in three patients, physical exertion in one, and forced swallowing in one. There were three spontaneous cases. The chief complaints were dyspnea in five patients including three patients with bronchial asthma, chest pain in two, and pharyngeal pain in one. Subcutaneous emphysema was observed in all patients. Hamman's sign was audible in only one patient. Roentgenologically, subcutaneous emphysema was observed in all patients. Pneumomediastinum parallel to the heart was observed in five patients. The continuous diaphragm sign was detected in three patients. Five patients were prohibited from eating and drinking excluding those with pneumomediastinum due to bronchial asthma, considering the esophageal origin. Prophylactic antibiotics were prescribed for all patients. Pneumomediastinum improved within 7 days in all patients. The mean length of hospitalization was 7.8 days, ranging from 4 to 13 days.
Conclusion: In consideration of air of the esophageal origin, non per oral was prescribed. With the prevention of mediastinitis using antibiotics, all patients recovered. Emergency endoscopic examination was unnecessary. (Ann Thorac Cardiovasc Surg 2003; 9: 188–91)

Key words: medical pneumomediastinum, pneumomediastinum, bronchial asthma, subcutaneous emphysema, Hamman's sign

Introduction

Pneumomediastinum is defined as the migration of air into the mediastinum. Its causes include trauma, increase of intrapulmonary pressure, occurring at a time of straining with the glottis closed, and at a time of occlusion, partial or complete, of the trachea or bronchi, and spontaneous rupture of alveoli. In this report, we discuss medical pneumomediastinum,[1)] that is pneumomediastinum arising either spontaneously or due to some underlying disease, and clarify its clinical features.

From [1]Department of Thoracic Surgery, Hachioji Medical Center of Tokyo Medical University, Tokyo, and [2]Department of Surgery, Tokyo Medical University, Tokyo, Japan

Received November 12, 2002; accepted for publication January 15, 2003.
Address reprint requests to Hiroyuki Miura: Department of Thoracic Surgery, Hachioji Medical Center of Tokyo Medical University, 1163 Tate-machi, Hachioji-city, Tokyo 193-0998, Japan.

Materials and Methods

Between April 1993 and March 2001, eight patients with pneumomediastinum, caused by other than trauma or operative, diagnostic, or therapeutic trouble, were treated at our department. The clinical features and courses were studied retrospectively. A total of 2,573 patients were admitted to our department in the same period.

Results

All patients but one were men. The mean age of the eight

Table 1. Patients characteristics

No.	Age	Sex	Etiology	Symptom	Onset to hospitalization (day)	Subcutaneous emphysema	Hamman's sign	BMI
1	20	F	Bronchial asthma	Dyspnea	1	+	–	17.9
2	18	M	Bronchial asthma	Dyspnea	2	+	–	26.5
3	20	M	Bronchial asthma	Dyspnea	1	+	–	–
4	20	M	Spontaneous	Chest pain	1	+	–	–
5	16	M	Spontaneous	Dyspnea	1	+	+	18.6
6	16	M	Spontaneous	Dyspnea	0	+	–	–
7	15	M	Forced swallowing	Pharyngeal pain	0	+	–	–
8	15	M	Sports	Chest pain	1	+	–	15.8

BMI: body mass index.

Table 2. Examination and treatment of pneumomediastinum

No.	Leukocyte (/μ l)	CRP (mg/dl)	Chest X-ray			Chest CT		Treatment	Days in hospital
			Subcutaneous emphysema	Pneumomediastinum parallel to the cardiac shadow	Continuous diaphragm sign	Subcutaneous emphysema	Pneumomediastinum		
1	7,100	0.3	+	+	+	+	+	Antibiotics, bronchodilator	4
2	4,510	0.7	+	–	–	+	+	Antibiotics, bronchodilator	6
3	5,860	1.12	+	+	+	+	+	Antibiotics, bronchodilator	7
4	8,100	1.7	+	+	–	+	+	Antibiotics, non per oral	13
5	5,140	1.18	+	+	+	+	+	Antibiotics, non per oral	6
6	9,800	0.27	+	+	–	+	+	Antibiotics, non per oral	6
7	7,200	0.52	+	–	–	+	+	Antibiotics, non per oral	13
8	4,230	0.11	+	–	–	+	+	Antibiotics, non per oral	7

CRP: C-reactive protein.

patients with pneumomediastinum was 17.5 years, with a range of 15 to 20 years. The incidence of pneumomediastinum in our department was about 1:320. Predisposing factors were bronchial asthma in three patients, physical exertion in one, and forced swallowing in one. Three patients have no known causes. The chief complaints were dyspnea in five patients including three patients with bronchial asthma, chest pain in two, and pharyngeal pain in one. The mean length between the onset of the symptom and visiting the hospital was 0.88 days, with a maximum of 2 days. Subcutaneous emphysema was observed in all patients. Hamman's sign was audible in only one patient. The body mass indexes (BMIs) calculated in four patients varied from 15.8 to 26.5. The inflammatory findings were not prominent (Table 1). Leukocytosis was observed in only one patient. The highest score of C-reactive protein (CRP) was 1.7 mg/dl. Roentgenologically, subcutaneous emphysema was observed in all patients. Pneumomediastinum parallel to the cardiac shadow was observed in five patients. The continuous diaphragm sign was detected in three patients (Fig. 1). Chest computed tomography (CT) examination revealed the condition of subcutaneous emphysema and pneumomediastinum well. Especially, air space was observed around the left lower trunk of the pulmonary artery in case 3. That showed the air leakage originating from the bronchioles of the left lower lobe (Fig. 2).

Considering the esophageal origin, bed rest was ordered in five patients excluding those with pneumomediastinum due to bronchial asthma. Prophylactic antibiotics were prescribed for all patients. Upper gastrointestinal examination, gastric fiberoptic examination, and bronchofiberoptic examination were not performed except in case 7. Only upper gastrointestinal examination was performed in case 7 in order to rule out the presence of esophageal laceration. Pneumomediastinum improved within 7 days in all patients. The mean length of hospitalization was 7.8 days, ranging from 4 to 13 days. The hospital days were prolonged in two patients in order to verify that there was no change after eating (Table 2).

Discussion

Among the causes of pneumomediastinum, it is easy to clarify if air leakage originates from the intrathoracic organs with a lumen such as the trachea and esophagus. The origin of air leakage from the extrathoracic lesions such as the neck, oral cavity and abdomen[2] was also identifiable. The air from the alveoli was explained by the animal experiment of Macklin.[3] Namely, air may break through from the terminal alveoli as a result of increased alveolar pressure and enters the pulmonary interstitial spaces; then the air dissects along the pulmonary perivascular sheaths and moves to the mediastinum.

Since the age distribution of pneumomediastinum correlates well with that of pneumothorax clinically, the rupture of bleb growing adjacent to the perivascular sheath or congenital fragility of the alveolar wall is presumed. Although pneumomediastinum which is complicated with large breathing resulting from diabetic ketoacidosis,[4] or Valsalva-type maneuver, and that associated with anorexia nervosa[5] were reported, there are also spontaneous cases which have no known cause. Pneumomediastinum resulting from physical exertion or vocal exercise should not be included in idiopathic cases. From this point of view, there were only three spontaneous cases in our series. The frequency of pneumomediastinum is comparatively as rare as one person to 40,000[1]-7,115[6] inpatients. If restricted to pneumomediastinum resulting from asthma, the frequency is 26 out of 12,363 internal medicine patients (0.21%) and 60 out of 22,686 pediatric patients (0.26%).[7] At our department, the incidence was one person to 320 inpatients.

According to previous reports, pneumomediastinum was more frequent among youth and overwhelmingly more common in males.[1,8] The rupture of bleb is considered as one of the reasons occurring in the younger generation like pneumothorax occurring also in the young generation. Activities like sports or a performance of a musical instrument in the fashion of the younger generation are considered other causes. Our patients also ranged in age from 15-20 years and were all male except for one patient. The previous reports also said that pneumomediastinum was more frequent in thin patients. However, if pneumomediastinum of asthmatic origin is included, not all of our patients had a low BMI. On auscultation, although a precordial crunching sound is well known as Hamman's sign, it was audible in only one of our patients. There is a possibility that this low incidence was due to having not changed posture and having not auscultated enough, because this is the noise intensified in the left lateral position.[6,9,10]

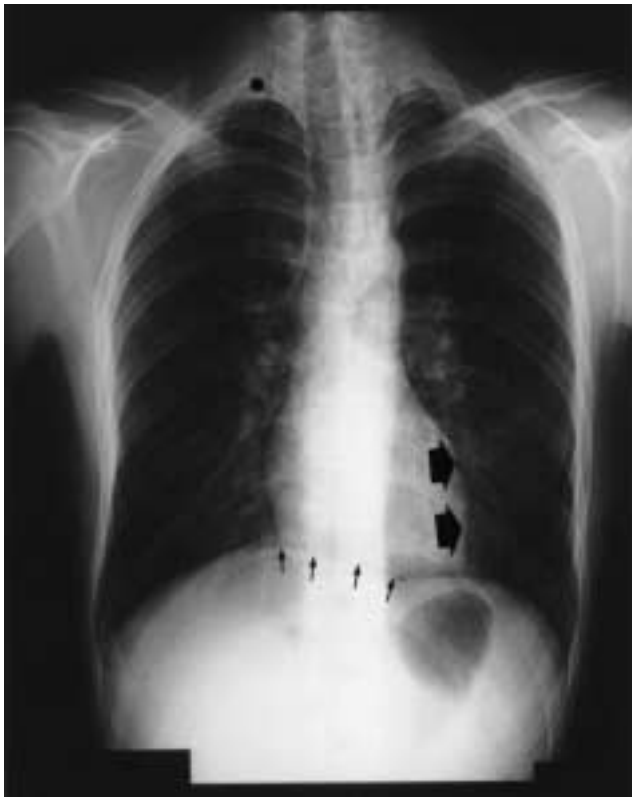

Fig. 1. Chest X-ray film of case 3 shows subcutaneous emphysema (*), pneumomediastinum parallel to the cardiac shadow (large arrow) and continuous diaphragm sign (small arrows).

The most common symptoms are chest pain, dyspnea, neck pain, and dysphagia.[6,8] Subcutaneous emphysema was reported to be observed in 80% or more of cases.[1] In all of our cases, subcutaneous emphysema was observed. Although there were no cases, which showed severe inflammatory findings, inflammatory reactions such as CRP and number of leukocytes need to be checked for the early detection of mediastinitis. Chest X-rays were useful for its diagnosis. Subcutaneous emphysema was observed in all cases. Pneumomediastinum was observed parallel to the cardiac shadow in five (62.5%) of our cases. The continuous diaphragm sign,[11] in which both the diaphragms were observed as a line due to air entering between the heart and diaphragm, was detected in three patients (37.5%). If a traumatic case or a rupture of the esophagus or duodenal ulcer can be ruled out, urgent gastrofiberscopic and bronchoscopic examinations are unnecessary, because the torn portion will be too small to detect. If anything, there is a risk of the wound being enlarged by endoscopic examination.

In patients with pneumomediastinum associated with

Fig. 2. Chest CT film of case 3 shows air space around the left lower trunk of the pulmonary artery (arrows).

bronchial asthma or complicated with infection, treatment for asthma or infection was necessary. The other patients improved with bed rest alone. Although the use of an antibiotic is controversial,[12] all patients were medicated with it to prevent mediastinitis. Using these medications, all patients were cured without mediastinitis.

Except for the asthmatic patients, the patients were prohibited from eating and drinking in consideration of the origin of the air leakage being the esophagus. A Nasogastric tube is unnecessary. Careful attention to the possible development of mediastinitis or tension pneumomediastinum is necessary. Therefore, inflammatory findings and worsened dyspnea should be checked. In order to have a sufficient observation period after meals were resumed, the hospital stay was as long as 7.8 days on average. However, especially for the patients whose origin of air leakage was the esophagus, these resting periods were extremely important to prevent expansion of the wound.

Conclusion

Pneumomediastinum was treatable without complications only by bed rest and antibiotics preventing mediastinitis. The treatments for original diseases such as bronchial asthma were necessary for symptomatic pneumomediastinum. If the origin is considered to be esophageal, prohibition of eating and drinking was required. Endoscopic examination is unnecessary at the acute stage because of the difficulty in detecting the damaged lesion and the danger of worsening the lesion.

References

1. Bodey GP. Medical mediastinal emphysema. *Ann Intern Med* 1961; **54**: 44–56.
2. Stahl JD, Goldman SM, Minkin SD, Diaconis JN. Perforated duodenal ulcer and pneumomediastinum. *Radiology* 1977; **124**: 23–5.
3. Macklin CC. Transport of air along sheaths of pulmonic vessels from alveoli to mediastinum. *Arch Intern Med* 1939; **64**: 913–26.
4. Weathers LS, Brooks WG, Declue TJ. Spontaneous pneumomediastinum in a patient with diabetic ketoacidosis: a potentially hidden complication. *South Med J* 1995; **88**: 483–4.
5. Rey C, Avin P, Pariente D, Cortecuisse V. Pneumomediastinum in a young girl with anorexia nervosa. *Arch Pediatr* 1994; **1**: 652–4.
6. Munsell CW. Pneumomediastinum. *JAMA* 1967; **202**: 689–93.
7. Kamoshita I, Kayama Y, Matsueda S, et al. A study of complicated mediastinal and subcutaneous emphysema in patients with bronchial asthma. *J Jpn Bronchoesophageal Soc* 1978; **29**: 284–90. (in Japanese with English abstract)
8. Abolnic I, Lossos IS, Breuer R. Spontaneous pneumomediastinum. *Chest* 1991; **100**: 93–5.
9. Gray JM, Hanson GC. Mediastinal emphysema: aetiology, diagnosis, and treatment. *Thorax* 1966; **21**: 325–32.
10. Hamman L. Mediastinal emphysema. *JAMA* 1945; **128**: 1–6.
11. Levin B. The continuous diaphragm sign. A newly recognized sign of pneumomediastinum. *Clin Radiol* 1973; **24**: 337–8.
12. Parker GS, Mosborg DA, Foley RW, Steinberg CM. Spontaneous cervical and mediastinal emphysema. *Laryngoscope* 1990; **100**: 938–40.