Original Article

Aortic Arch Replacement with Proximal First Technique

Yuji Miyamoto, MD, Kenji Onishi, MD, Masataka Mitsuno, MD, Koichi Toda, MD, Masao Yoshitatsu, MD, and Kazuo Abe, MD

Background: Deep hypothermic circulatory arrest (DHCA) without retrograde cerebral perfusion (RCP) has a strict time limit. We modified a surgical technique for anastomosis to shorten the period of DHCA and unilateral cerebral perfusion (UCP).

Methods: Between March 1993 and August 2001, retrospective analysis was done on 23 consecutive patients, who underwent aortic arch replacement with branches. The patients were divided into two groups: DHCA group and UCP group. The DHCA group, in which DHCA alone and without additional cerebral perfusion was performed, comprised of nine patients. Proximal aortic anastomosis was performed first during systemic cooling; then both the brachiocephalic artery and left carotid artery were reconstructed with the branches of the artificial graft during circulatory arrest; thereafter, cerebral and coronary perfusions were resumed. The UCP group, in which DHCA was not used but right hemisphere perfusion during deep hypothermia was performed when the origin of brachiocephalic artery was safely clamped, consisted of 14 patients.

Results: Mean time of DHCA was 18.8±4.2 minutes and that of right hemisphere perfusion time was 11.0±3.8 minutes, respectively. Twenty-one patients survived the surgery (91.3%), and two (8.7%) died during hospitalization. Transient cerebral complication occurred in four patients in the DHCA group and all recovered. Logistic regression analysis revealed that DHCA was the only parameter to significantly influence temporary neurological dysfunction. There was no other significant difference between the two groups.

Conclusion: With our modified and simple surgical technique for aortic arch repair, we were able to successfully shorten the DHCA time and right hemisphere perfusion time. However, because DHCA was the only parameter to significantly influence temporary neurological dysfunction, some form of continuous cerebral perfusion at deep hypothermia may be a safer method to preserve cerebral function. (Ann Thorac Cardiovasc Surg 2003; 9: 389–93)

Key words: aortic arch replacement, deep hypothermic circulatory arrest, unilateral cerebral perfusion, brain protection

Introduction

Currently, the most frequently used technique for cerebral protection during aortic arch surgery is deep hypothermic circulatory arrest (DHCA).[1,2] Selective cerebral perfusion (SCP) is also used for arch surgery because it has a much less time limitation.[3,4] SCP, however, needs complicated cannulation, and the deleterious effects of cannulation on the cerebral vessels are indicated. Moreover, to prolong the "safe" period during DHCA, retrograde cerebral perfusion (RCP) is also widely used.[5] However, RCP is not so reliable and its time limitation is not yet known. Also, a perfectly dry field cannot be achieved with RCP. Therefore, to simplify the operation, we used the proximal first technique and performed DHCA without RCP or right hemisphere perfusion (unilateral cerebral perfusion: UCP) for aortic arch surgery. We succeeded to shorten the DHCA and UCP time with some modification of the surgical technique and achieved relatively good results.

From Division of Cardiovascular Surgery and Anesthesiology, Sakurabashi-Watanabe Hospital, Osaka, Japan

Received October 11, 2002; accepted for publication April 21, 2003.
Address reprint requests to Yuji Miyamoto, MD: Division of Cardiovascular Surgery, Sakurabashi-Watanabe Hospital, 2-4-32 Umeda, Kita-ku, Osaka 530-0001, Japan.

Table 1. Operative specification

	DHCA (n=9)	UCP (n=14)	p value
Age (years)	63±12	58±11	ns
Emergent/elective	1/8	1/13	ns
Dissection/true	5/4	10/4	ns
Operation time (hours)	6.7±2.3	7.5±1.4	ns
CPB time (minutes)	143±62	169±48	ns

DHCA, deep hypothermic circulatory arrest; UCP, unilateral cerebral perfusion; CPB, cardiopulmonary bypass.

Patients and Methods

Patients

Since March 1993, 36 consecutive patients underwent aortic surgery involving the transverse arch. Arch replacement with two or three branches was performed in 23 patients (15 aortic dissections and 8 true aneurysms). The clinical records of the patients requiring arch replacement were retrospectively reviewed. Their ages ranged from 38 to 77 years with a mean age of 62±9 years. Eighty-three percent (n=19) were male and 17% (n=4) were female. Eight patients had chronic atherosclerotic lesions, 12 with Stanford type A dissection including two emergent cases, and three with Stanford type B dissection involving the transverse arch.

As shown in Table 1, the patients were divided into two groups: DHCA group and UCP group. The DHCA group, in which DHCA alone was performed, i.e., without any additional cerebral perfusion (SCP or RCP), comprised of nine patients. The UCP group, in which DHCA was not used but right hemisphere perfusion during deep hypothermia was performed when the origin of brachiocephalic artery was safely clamped, consisted of 14 patients. The lowest temperature (20°C) was the same in both groups. The indication of DHCA depended on the condition of the brachiocephalic artery. If the brachiocephalic artery had some abnormal change, i.e., dissection or atherosclerosis, DHCA was applied to avoid clamping injury of the brachiocephalic artery. If the origin of the brachiocephalic artery was intact and safely clamped, antegrade hemisphere perfusion (10 ml/kg/minute) was continued through the right brachial artery to avoid DHCA.

Although RCP was not used in the DHCA group, it was routinely carried out for a couple of minutes by elevating the central venous pressure, just long enough to flush the cerebral circulation and evacuate the air. To elevate the central venous pressure, the blood in the reservoir was infused into the right atrium through the venous cannula. Concomitant procedures included aortic root replacement (two cases), aortic valve replacement (one case), and coronary artery bypass grafting (one case). Graft replacements of the ascending aorta had been done in two cases preoperatively.

Surgical technique

All operations were performed through mediansternotomy. For the arch replacement with branches, the skin incision was extended to the left supraclavicular region. All patients were placed on cardiopulmonary bypass (CPB). The right arm was elevated and the brachial artery was approached through the underarm. An arterial cannula was inserted into the right brachial artery plus femoral artery in 17 patients, brachial artery alone in three and femoral artery alone in three. In the patients with aortic dissection, the femoral artery, which had a stronger pulsation, was cannulated for arterial access. Two-staged single venous cannula was used instead of bicaval cannulation. Myocardial protection was provided with a single-dose retrograde cold blood cardioplegia and continuous profound topical hypothermia in the pericardial well. Myocardial ischemic time was less than 40 minutes in our patients. The whole body was cooled to 20°C of the tympanic and bladder temperatures. To regulate the blood pH during CPB, the alpha-stat strategy was used. Electroencephalogram was not monitored. The head was packed in ice to prevent warming of the central nervous system during hypothermia. As brain protective agents, 5 mg/kg/hour of propofol was continuously infused during surgery. After the patients had been placed in the Trendelenburg position, the aortic arch was opened.

In the standard total arch replacement (Fig. 1), quadrifurcated collagen or a gelatin-impregnated woven Dacron graft was used. During systemic cooling, the ascending aorta was cross-clamped and the heart was arrested with cardioplegia. Proximal anastomosis between the ascending aorta and the graft was performed first. Then, DHCA was induced if necessary. UCP was continued

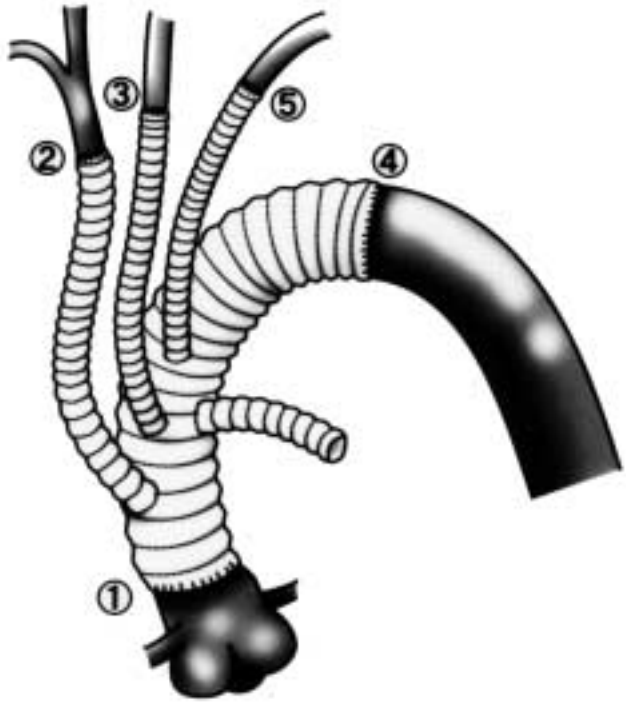

Fig. 1. Standard total arch replacement. Anastomosis was performed in a numerical sequence. Anastomoses 2 and 3 were performed during deep hypothermic circulatory arrest (DHCA) or unilateral cerebral perfusion (UCP).

if the origin of the brachiocephalic artery was safely clamped. During the reconstruction of brain perfusion, the descending aorta was left open and the lower body was not perfused in both groups. The following procedures were the same in both groups: the first and second branches of the graft were anastomosed to the brachiocephalic artery and the left common carotid artery, respectively. After completion of these anastomoses, antegrade cerebral and coronary perfusions were resumed through the fourth branch of the graft (800-1,000 ml/minute). A vent tube to the left ventricle through the right upper pulmonary vein was always inserted. Hypothermic ventricular fibrillation of the heart was maintained until rewarming. The left subclavian artery was clamped. Then the next anastomosis was the distal site between the graft and the descending aorta. The body temperature was kept at 20°C until open distal anastomosis was completed. Occlusion balloon into the descending aorta was not applied in the patients with aortic dissection. If the occlusion balloon into the descending aorta was successfully inserted in the patients with a true aneurysm, perfusion of the lower body was resumed and rewarming was started during distal anastomosis. To avoid kinking at the lesser curve of the single graft, a separate graft was sometimes used, which was anastomosed to the descending aorta and joined to the main graft in the middle. Finally, the third branch was anastomosed to the left subclavian artery.

Statistical analysis

Statistical analysis was done on the StatView software package, version 5.0 (Abacus Concepts, Berkeley, CA, USA). Quantitative variables that approximated a normal distribution were presented as the mean ± SD. Continuous variables were analyzed using unpaired Student's t test and nominal variables were analyzed non-parametrically using the chi-square test. The predictors of postoperative neurological complications were determined by the logistic regression analysis. A p value less than 0.05 was considered significant.

Results

DHCA time ranged from 14 to 25 minutes with an average of 18.8±4.2 minutes in arch replacement (n=9) for the reconstruction of two cerebral vessels, and the UCP time was 11.0±3.8 (range, 7-22) minutes for the reconstruction of one or two cerebral vessels (n=14).

In-hospital mortality: Of the 23 patients, 21 (91.3%) patients survived the surgery, and two (8.7%) died during hospitalization. Of the two deaths, one died of a problem with myocardial protection due to air embolism during surgery, and the other patient, although he was doing well without neurological complication, suddenly developed a new stroke two weeks after operation and died (Table 2).

In-hospital morbidity: Transient neurologic dysfunction with negative computed tomographic scanning results was observed in four patients (17.4%), in whom confusion and delirium occurred in three patients and convulsion occurred in one patient; however, all recovered completely before discharge. Transient neurological dysfunction occurred significantly in the DHCA group (Table 2). Logistic regression analysis revealed that DHCA was the only variable to significantly influence temporary neurologic dysfunction (Table 3). No permanent dysfunction directly originating from surgery was found in our patients.

Comment

There are three major brain protection methods during aortic arch surgery, i.e., DHCA alone, DHCA with RCP, and SCP. Each method has its own advantages. The use of DHCA during aortic arch reconstruction developed in the early 1970s.[6] DHCA was developed to increase the

Table 2. Morbidity and mortality

	DHCA (n=9)	UCP (n=14)	p value
Neurological complication			
Permanent	0	1*	ns
Transient	4	0	p=0.027
Tracheostomy	2	0	ns
Phrenic nerve palsy	1	1	ns
Mortality	0	2	ns

DHCA, deep hypothermic circulatory arrest; UCP, unilateral cerebral perfusion. * dead

tolerable ischemic period by slowing the basal neurologic metabolic rate as much as possible. Although DHCA with RCP and SCP are recently becoming popular, we prefer simple cannulation and used DHCA alone or right hemisphere perfusion (UCP).

The optimal core temperature for DHCA has not been agreed on. The electroencephalographic monitoring during DHCA is reported to be useful to determine the temperature. Coselli and associates[7] maintained systemic cooling until the electroencephalogram demonstrated electrical silence, and the cooling was continued for an additional three minutes. In their patients, core temperature usually ranged from 10°C to 15°C, and sometimes around 20°C. In our patients, cooling was instituted to reach a core temperature of 20°C. We were careful not to increase the operative risk due to hypothermia-induced coagulopathy.

The safe period of circulatory arrest is of particular interest. Anastomosis of the graft to the descending aorta is usually performed before anastomosis to the arch vessels. Median or mean circulatory time is reported to be from 25 to 40 minutes with this technique.[1,5] It is reported that the length of time of circulatory arrest was not an independent determinant of death or postoperative stroke.[1] This, however, does not mean that the length of circulatory arrest is not important. Ergin and colleagues[2] reported that the incidence of temporary neurologic dysfunction rose linearly in relation to the duration of DHCA.

To minimize the period of brain ischemia and reduce the potential for neurologic injury, we modified the surgical technique and successfully reduced the circulatory arrest time to a mean of 18.8 minutes and the UCP time to 11.0 minutes, with a maximum of 25 minutes. We changed the order of the anastomosis in arch replacement (proximal first technique). Proximal aortic anastomosis was accomplished first during the period of core cooling; then the brachiocephalic and left carotid arteries were reconstructed during DHCA or under UCP. Ten minutes are usually enough to complete one anastomosis of the vessels with an 8-10 mm diameter. Distal anastomosis is critical in arch replacement and SCP is suitable to perform distal anastomosis safely. Distal anastomosis may seem difficult after anastomosis of the proximal aorta and arch branches. To make distal anastomosis easy in the proximal first technique, it is important to make the graft branches to the brachiocephalic and carotid arteries a little longer (1 or 2 cm than usual). This modification affords more space and mobility for distal anastomosis.

The basic concept of our technique for total arch replacement may resemble the “arch-first” technique.[8,9] In the latter technique, arch vessels are reconstructed first and antegrade cerebral perfusion is immediately resumed. Then distal anastomosis is performed, and the last anastomosis is the proximal site. Whereas, in our technique the proximal anastomosis is performed first during core cooling.

UCP through brachiocephalic artery was reported to be safe for the majority of patients with aortic arch aneurysm.[10,11] Use of UCP technique raises concerns about the adequacy of perfusion to the contra-lateral hemisphere. It depends on the condition of the circle of Willis. A study of collateral variations in the circle of Willis reported that the anterior collateral pathway was nearly always functional and the posterior collateral pathway was non-functional in almost half of the total number of hemispheres.[12] We suppose UCP within 30 minutes under deep hypothermia is quite safe.

As for neurological complications, Svensson and associates[1] reported that the safe period of DHCA for strokes not to develop appeared to be limited to approximately 40 minutes, and Ergin and associates[2] reported that DHCA affords adequate cerebral protection if the arrest period is kept at less than 60 minutes. In our series, the temporary deficit occurred in four patients of the DHCA group. No temporary deficit was seen in the UCP group and DHCA was the only significant variable to influence its occurrence. Therefore, DHCA per se may have some deleterious effects on the brain even if it were within

Table 3. Logistic regression analysis for possible factors affecting postoperative transient neurological dysfunction

		p value
Age (years)	60>, 60<	0.306
Sex	male, female	0.051
Emergent, elective		0.306
Dissection, true		0.999
Operation time (hours)	7>, 7<	0.999
DHCA	yes, no	<0.001
CPB time (minutes)	180>, 180<	0.051

DHCA, deep hypothermic circulatory arrest; CPB, cardiopulmonary bypass.

25 minutes. UCP through the right brachial artery was safe and easy to perform. DHCA can be avoided in the selected cases if the origin of brachiocephalic artery can be occluded safely. From our experience, continuing the UCP at deep hypothermia may be safer than DHCA alone.

Recent studies have demonstrated that RCP associated with DHCA decreases the rate of neurologic complication. The main advantages of this technique include cerebral cooling, washing out of the metabolites that accumulate as a result of ischemia, and back washing of potential emboli. The safe period of DHCA was reported to be prolonged by this technique.[5)]

Although we do not use RCP during anastomosis because the duration of DHCA is short in our series and we prefer a completely dry operative field, we do always use RCP for a couple of minutes at the end of DHCA to wash out the potential emboli and the air. Okita and associates[13)] reported that the prevalence of transient brain dysfunction was significantly higher in patients with RCP than in patients with SCP. Excellent results of SCP have been lately reported.[4,13)] The advantage of SCP is that time limitation is almost not necessary. However, selective cannulation to the atherosclerotic brain vessels per se may have some risk of stroke. Their hospital mortality ranged from 2% to 6.6%, the incidence of stroke 4% to 6.6%, and the incidence of transient brain dysfunction 4% to 13.3%. In our series, hospital mortality was 8.7%, stroke occurred in 4.3%, and transient brain dysfunction occurred in 17.4%.

In conclusion, from the results of our current study, our modified surgical technique was simple and afforded compatible results to those of SCP or DHCA with RCP. We believe that the continuous use of our proximal first technique can be justified. However, because DHCA was the only parameter to significantly influence temporary neurological dysfunction, some form of continuous cerebral perfusion at deep hypothermia may be a safer method to preserve cerebral function.

References

1. Svensson LG, Crawford ES, Hess KR, et al. Deep hypothermia with circulatory arrest. Determinants of stroke and early mortality in 656 patients. *J Thorac Cardiovasc Surg* 1993; **106**: 19–28.
2. Ergin MA, Galla JD, Lansman L, Quintana C, Bodian C, Griepp RB. Hypothermic circulatory arrest in operations on the thoracic aorta. Determinants of operative mortality and neurologic outcome. *J Thorac Cardiovasc Surg* 1994; **107**: 788–99.
3. Bachet J, Goudot B, Dreyfus G, et al. How do we protect the brain? Antegrade selective cerebral perfusion with cold blood during aortic arch surgery. *J Card Surg* 1997; **12** (Suppl): 193–200.
4. Kazui T, Washiyama N, Muhammad BAH, Terada H, Yamashita K, Takinami M. Improved results of atherosclerotic arch aneurysm operations with a refined technique. *J Thorac Cardiovasc Surg* 2001; **121**: 491–9.
5. Coselli JS, Buket S, Djukanovic B. Aortic arch operation: current treatment and results. *Ann Thorac Surg* 1995; **59**: 19–27.
6. Livesay JJ, Cooley DA, Reul GJ, et al. Resection of aortic arch aneurysms: a comparison of hypothermic techniques in 60 patients. *Ann Thorac Surg* 1983; **36**: 19–28.
7. Coselli JS, Crawford ES, Beall AC, Mizrahi EM, Hess KR, Patel VM. Determination of brain temperatures for safe circulatory arrest during cardiovascular operation. *Ann Thorac Surg* 1988; **45**: 638–42.
8. Rokkas CK, Kouchoukos NT. Single-stage extensive replacement of the thoracic aorta: the arch-first technique. *J Thorac Cardiovasc Surg* 1999; **117**: 99–105.
9. Hagl C, Ergin MA, Galla JD, et al. Neurologic outcome after ascending aorta-aortic arch operations: effect of brain protection technique in high-risk patients. *J Thorac Cardiovasc Surg* 2001; **121**: 1107–21.
10. Frist WH, Baldwin JC, Starnes VA, et al. A reconsideration of cerebral perfusion in aortic arch replacement. *Ann Thorac Surg* 1986; **42**: 273–81.
11. Tasdemir O, Saritas A, Kucuker S, Ozatik MA, Sener E. Aortic arch repair with right brachial artery perfusion. *Ann Thorac Surg* 2002; **72**: 1837–42.
12. Hoksbergen AWJ, Legemate DA, Ubbink DT, Jacobs MJHM. Collateral variations in circle of Willis in atherosclerotic population assessed by means of transcranial color-coded duplex ultrasonography. *Stroke* 2000; **31**: 1656–60.
13. Okita Y, Minatoya K, Tagusari O, Ando M, Nagatsuka K, Kitamura S. Prospective comparative study of brain protection in total aortic arch replacement: deep hypothermic circulatory arrest with retrograde cerebral perfusion or selective antegrade cerebral perfusion. *Ann Thorac Surg* 2001; **72**: 72–9.