Case Report

Inflammatory Aortic Arch Aneurysm with Total Occlusion of Cervical Branches

Kazuhiro Kochi, MD, and Taijiro Sueda, MD

We surgically replaced the aortic root and the complex arch in a patient with aortitis syndrome with total occlusion of the cervical branches. Cerebral perfusion was being maintained through the reversed flow of the vertebral artery from the bilateral mammary arteries. Though cerebral perfusion was continued through the prosthetic grafts attached to the subclavian arteries during the procedure, bilateral watershed cerebral infarction corresponding to the most distal part of the anterior- and middle cerebral arterial system developed. With regard to the near infrared spectroscopy as a brain monitoring method, we sought to discuss the limitations. (Ann Thorac Cardiovasc Surg 2004; 10: 51–3)

Key words: aortitis, stroke, near infrared spectroscopy

Introduction

Though inflammatory thoracic aneurysm in patients with aortitis syndrome is not rare, aortic arch aneurysms with lesions of the cervical vessels presents a challenge to surgeons.[1-3] We surgically replaced the aortic root and the complex arch in a patient with aortitis syndrome with total occlusion of the cervical branches.

Case Report

A 72-year-old male with aortitis syndrome, without a history of stroke, was admitted for surgery following the diagnosis of an aortic root dilation of more than 8 cm in diameter, severe aortic regurgitation and an arch aneurysm 6 cm in diameter. Angiography showed 1) total occlusion of the cervical branches, 2) marked disease of the bilateral vertebral arteries without total occlusion, 3) patent distal subclavian arteries from the level of the vertebral branches, and 4) reversed flow from the collateral mammary arteries. Thus, cerebral perfusion was being maintained by the reversed flow of the vertebral artery from bilateral mammary arteries (Fig. 1). Magnetic resonance angiography revealed total occlusion of the bilateral internal carotid arteries, but Willis' ring was found to be patent receiving its supply from the vertebrobasilar system. Single photon emission computed tomography (SPECT) showed that cerebral malperfusion was not detected both at rest and on acetazolamide administration. However, maximal brain protection was required to surgically replace the aortic root and the arch, and to reconstruct the cervical branches. During this procedure, the bilateral subclavian arteries were exposed, and a PTFE prosthetic graft, 8 mm in diameter, was attached. Following median sternotomy, the pericardium was opened, revealing that the inflammatory aneurysm ran from the ascending aorta to the aortic arch at the level of the left carotid artery. Venous drainage was from the right atrium, and arterial return was via the femoral artery and those two grafts. After the establishment of the cardiopulmonary bypass, the nasopharingeal temperature was reduced to 25°C. Regional tissue oxygen saturation (rSO_2) of the frontal lobe was continuously monitored by near infrared spectroscopy (NIRS) because temporal arterial pressure could not be available. Central retinal artery color Doppler that is one of the methods of transcranial Doppler was intermittently monitored to estimate the internal carotid artery blood flow.[4] Regulation of the arterial infusion was maintained, with the aim of keeping the rSO_2

From Department of Surgery, Graduate School of Biomedical Sciences, Hiroshima University, Hiroshima, Japan

Received March 26, 2003; accepted for publication July 14, 2003.
Address reprint requests to Kazuhiro Kochi, MD: Department of Surgery, Graduate School of Biomedical Sciences, Hiroshima University, 1-2-3 Kasumi, Minami-ku, Hiroshima 734-8551, Japan.

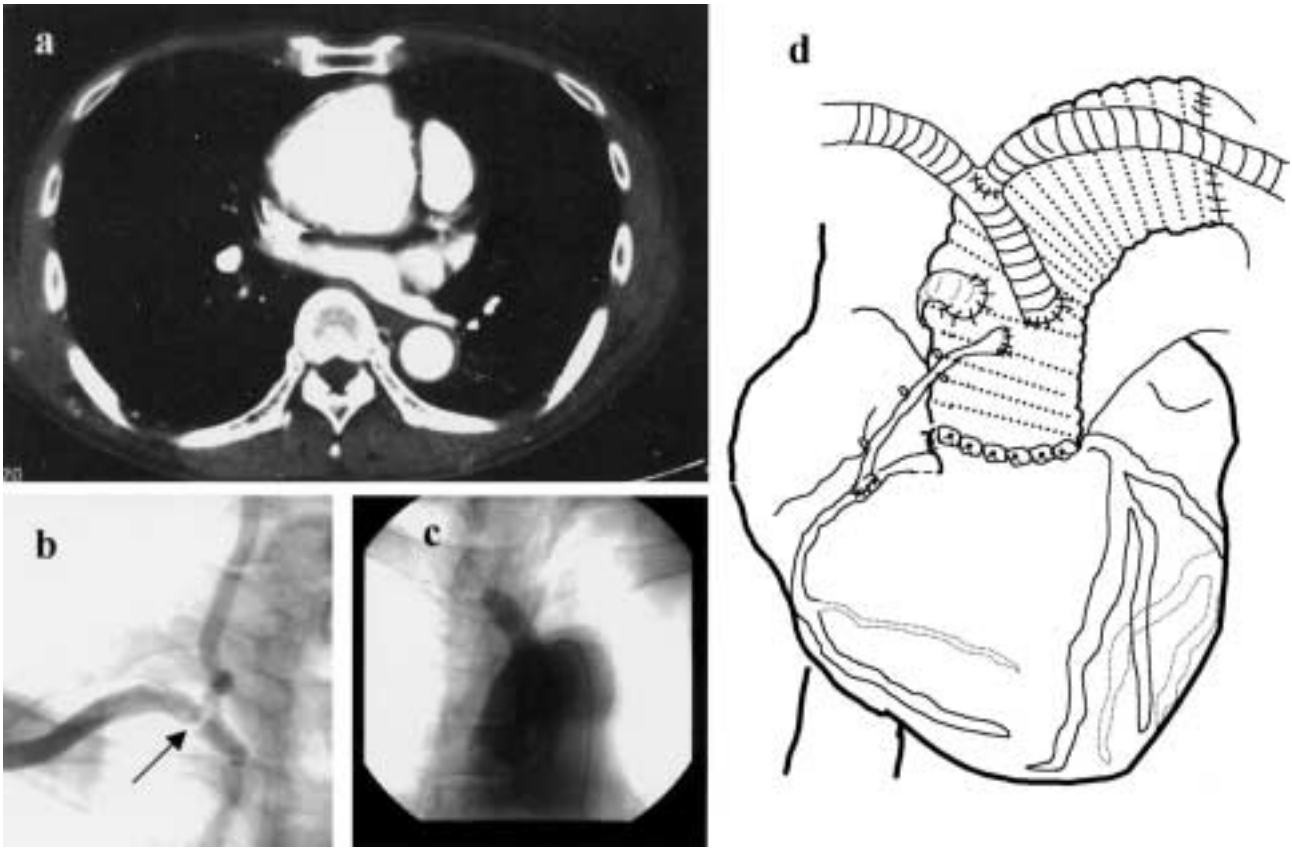

Fig. 1. Preoperative images and operative schema.
a: An inflammatory aneurysm on computed tomography.
b: Reversal flow of the internal mammary artery (arrow).
c: Total occlusion of the cervical branches.
d: An operative schema.

above 60% (more than 2.4 L/min/m^2).[4] An aortic clamp was made at the level of the occluded left subclavian artery. The aorta was opened and the minimum nasopharingeal temperature was spontaneously reduced to 20°C. All the cervical branches were occluded. The right coronary orifice was found to be occluded and the left coronary orifice was severely calcified. Coronary artery bypass grafting to the right coronary artery was performed using a vein graft. A Dacron graft (8 mm in diameter) was attached to the left coronary orifice to interpose the coronary blood flow. Aortic root replacement using a 24 mm composite Dacron graft with a 21 mm mechanical valve was performed in the usual manner. After distal anastomosis, the aortic clamp was released and systemic rewarming was started. After reconstruction of coronary perfusion, the tube grafts were guided through the thoracic space to reconstruct the subclavian arteries. Reconstruction of subclavian arteries was made with cerebral perfusion through the grafts except for the final few sutures (Fig. 1). When the patient was extubated the next day, paralysis of the bilateral extremities was evident. Magnetic resonance imaging revealed bilateral watershed cerebral infarction corresponding to the most distal part of the anterior- and middle cerebral arterial system. However, in spite of this, the patient responded well to physical rehabilitation, and was without disability one year after surgery.

Discussion

The difficulty of this case lies in the protection of brain during surgery, and in the reconstruction of the cervical branches. An aortic root replacement only without cervical reconstruction might be one of the choices, but we expected to prevent a stroke not only in the perioperative stage but also in his future life by adding the reconstruc-

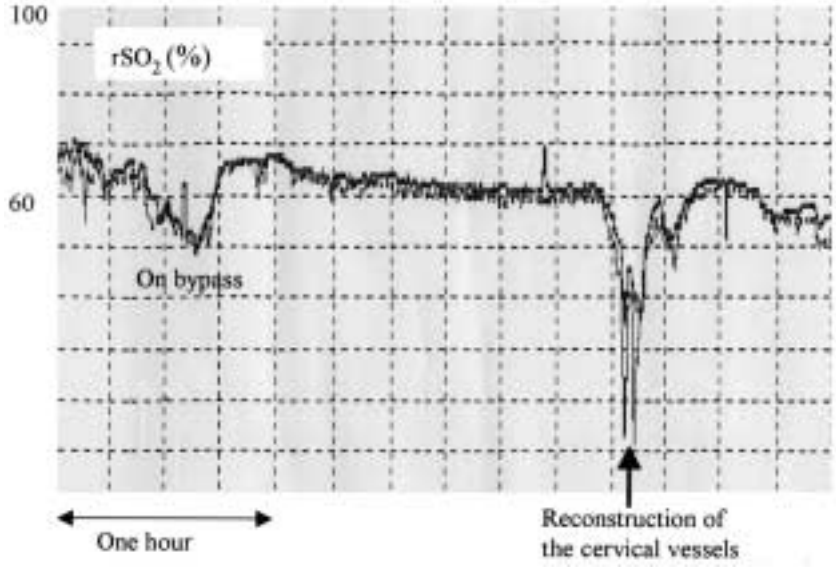

Fig. 2. Regional tissue oxygen-saturation which was measured at the frontal lobe by near infrared spectroscopy, decreased when a stroke event is suspected.

tion of the cervical branches. The following strategy was made for brain protection: (1) in addition to the systemic perfusion to maintain the reversal flow of the vertebral arteries through internal mammary arteries, selective cerebral perfusion using grafts connected to the subclavian arteries were established; (2) with regard to monitoring, NIRS for the frontal lobes and central retinal artery Doppler for the internal carotid artery blood flow were performed; (3) though systemic cooling was aimed to 25°C, nasopharingeal temperature was spontaneously reduced to 20°C for 70 minutes among 130 minutes of total bypass time. However, the patient developed cerebral infarction, with the infarct area located in the distal region of the vertebrobasilar system. We speculate that this event occurred when the final anastomosis of the subclavian grafts was made because rSO_2 was maintained above 60% except for during this procedure. A sudden drop of the rSO_2 corresponding to the period of the final procedure was evident in Fig. 2. In this period, central retinal artery blood flow could be detected and systemic perfusion flow was 2.6 L/min/m^2. The cause of stroke may be explained only by the increased temperature of 33°C due to rewarmed systemic perfusion when the cervical reconstruction was made.

We chose NIRS to monitor the cerebrovascular system.[5] Though the level of rSO_2 was mostly maintained above 60%, stroke could not be prevented. This may be explained as follows: 1) the location of cerebral ischemia cannot be detected except for in anterior lobe because only a probe for the forehead is presently available; 2) real time information is not provided because of the time delay of the monitoring system; 3) the relationship between the detected values and the neurological outcome is unknown; 4) monitoring of the vertebrobasilar system is not able to be performed during surgery even if a transcranial Doppler device is concomitantly used. Thus, neither the critical value, which indicates the potential for stroke development, nor the critical duration, when the rSO_2 decreases is provided. Further study is required to clarify the clinical efficacy of NIRS, because this monitoring method is noninvasive, reproducible and very simple.

References

1. Lagneau P, Michel JB, Vuong PN. Surgical treatment of Takayasu's disease. *Ann Surg* 1987; **205**: 157–66.
2. Harada H, Honma Y, Hachiro Y, Mawatari T, Abe T. Composite graft replacement after aortic valvuloplasty in Takayasu arteritis. *Ann Thorac Surg* 2002; **73**: 644–7.
3. Crawford ES, Svensson LG, Coselli JS, Safi HJ, Hess KR. Surgical treatment of aneurysm and/or dissection of the ascending aorta, transverse aortic arch, and ascending aorta and transverse aortic arch. Factors influencing survival in 717 patients. *J Thorac Cardiovasc Surg* 1989; **98**: 659–73; discussion 673–4.
4. Kochi K, Orihashi K, Sueda T. Comparative study of noninvasive cerebrovascular monitoring methods in cardiac surgery. *Hiroshima J Med Sci* 2002; **51**: 49–54.
5. Katoh T, Esato K, Gohra H, et al. Evaluation of brain oxygenation during selective cerebral perfusion by near-infrared spectroscopy. *Ann Thorac Surg* 1997; **64**: 432–6.