Case Report

Delayed Chronic Type A Dissection with a Functional Midline Crossing Right Internal Thoracic Artery after CABG: Surgical Approach to an Ascending Aorta without Dissecting the Midline Crossing Internal Thoracic Artery

Takashi Yamauchi, MD, Yuji Miyamoto, MD, Hiroshi Takano, MD, Yoshiki Sawa, MD, Goro Matsumiya, MD, Masayuki Sakaki, MD, and Hikaru Matsuda, MD

We successfully treated chronic type A dissection and coronary artery disease with a functional midline crossing right internal thoracic artery (RITA) after coronary artery bypass grafting (CABG). A 68-year-old man was incidentally diagnosed as chronic type A dissection by follow-up cardiac catheterization after CABG, with 90% stenosis in the right coronary artery (RCA) #2. The dissecting aneurysm (max. 6 cm in diameter) was localized at the right portion of the ascending aorta with a functional RITA to the left anterior descending coronary artery. The dissecting aneurysm was treated with patch closure and the RCA was revascularized with a right gastroepiploic artery and saphenous vein composite graft through combined right antero-axillar thoracotomy and lower mini-sternotomy without RITA dissection. Treatment of chronic type A dissection following CABG becomes more challenging with a functional midline crossing RITA. It is important that a safe and less invasive surgical strategy be implemented for such complicated case. (Ann Thorac Cardiovasc Surg 2004; 10: 57–60)

Key words: chronic type A dissection, right internal thoracic artery

Introduction

Delayed chronic type A dissection after cardiac surgery is difficult to treat, especially in patients who have previously undergone coronary artery bypass grafting (CABG). In the presence of a midline-crossed internal thoracic artery graft, a median sternotomy might jeopardize the graft and compromise hemodynamics. We report a successful patch closure of a dissecting aneurysm localized in the ascending aorta and CABG to the right coronary artery (RCA) through combined right antero-axillar thoracotomy and lower mini-sternotomy without the functional graft being dissected.

From Department of Surgery, Course of Interventional Medicine (E1), Osaka University Graduate School of Medicine, Osaka, Japan

Received August 4, 2003; accepted for publication October 2, 2003.
Address reprint requests to Takashi Yamauchi, MD: Department of Surgery, Course of Interventional Medicine (E1), Osaka University Graduate School of Medicine, 2-2 Yamadaoka, Suita, Osaka 565-0871, Japan.

Case

A 68-year-old man underwent cardiac catheterization after CABG because his exercise tolerant electrocardiogram showed ischemia in the inferior wall. The patient had undergone CABG (right internal thoracic artery [RITA] to the left anterior descending coronary artery [LAD], left internal thoracic artery to the posterior-lateral branch) in 1994. Coronary angiography showed 90% stenosis in #2 in the RCA. Both grafts were patent with the RITA crossing midline (Fig. 1). Aortography showed a dissecting aneurysm in the ascending aorta. Computed tomography (CT) revealed that the dissection was localized at the right side of the ascending aorta and the maximum diameter was 6 cm, and seemed moderately adherent to the sternum (Fig. 2).

The patient underwent an operation on April 3, 2003. He was placed in the anterolateral right decubitus position at 30°. Because of adhesion between the ascending aorta and the sternum, a fourth intercostal right anterior-axillar thoracotomy was first made (Fig. 3a); thereafter

Fig. 1. Coronary angiography shows a functional right internal thoracic artery, crossing over the sternum, to the left anterior descending artery.

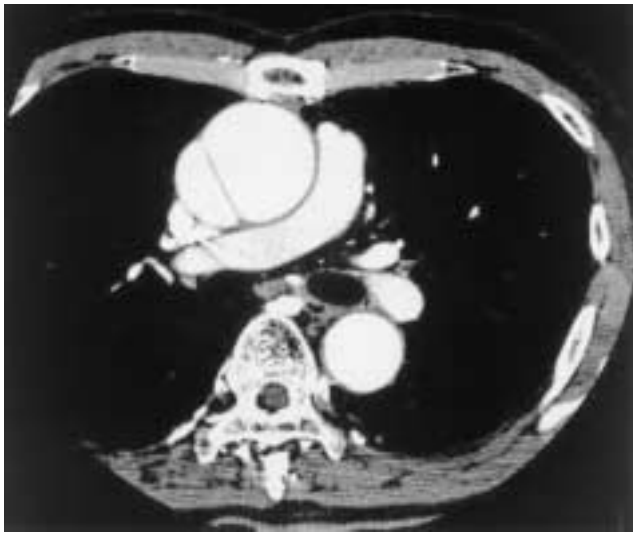

Fig. 2. CT shows chronic type A dissection localized to the right side of the ascending aorta, which is moderately adherent to the sternum.

dissection of the adhesion was performed. A lower half mini-sternotomy was then added and the target vessel (RCA #3) became easily visible. We could accomplish sternal reentry without injury to the ascending aorta. Extracorporeal circulation was established with arterial cannulation from the right femoral and brachial arteries, and venous drainage from the right atrium. The whole temperature was cooled to 20°C of tympanic temperature. The ascending aorta was not completely dissected and was not cross-clamped. No cardioplegia was administered, and no vent was used during hypothermic ventricular fibrillation because the aortic valve was competent. The localized dissecting aneurysm (Fig. 3b) was opened and a 15×15 mm entry observed. The intimal flap was removed completely, and the defect was covered with a trimmed Hemashield vascular graft with 3-0 prolene continuous sutures (Fig. 3c). Circulatory arrest time was 28 min. After deairing by retrograde systemic perfusion, antegrade systemic perfusion and rewarming were begun. The Hemashield patch was wrapped with the incised adventitia. As for CABG, the ascending aorta seemed inappropriate as a proximal anastomosis site because of the thinness of its wall. The right gastroepiploic artery (GEA) was then harvested, but it was too small to anastomose at the distal end. Therefore a composite graft with a saphenous vein was made and grafted to the RCA #3 (Fig. 3d).

The postoperative course was uneventful. Postoperative CT showed a patent GEA-saphenous vein graft (SVG) composite graft and no aneurysm.

Discussion

Delayed ascending aortic dissection after cardiac surgery is difficult to treat, especially in cases with functional midline-crossing RITA to the LAD. In such complicated cases, a safe and less invasive surgical strategy should be considered to diminish surgical morbidity and mortality.

Chronic postoperative dissecting aneurysm and pseudoaneurysm of the ascending aorta after cardiac surgery are relatively rare but potentially serious complications of various cardiac procedures.[1,2] Cause and etiology are difficult to be identified; though Orszulak et al. commented that delayed aortic dissection after cardiac surgery was not related to technical operative errors or clamp injury, but to cystic medial necrosis or hypertension.[1] With respect to delayed aortic dissection following CABG, Hagl et al. reported that an intimal tear most often appears at the partial occlusion site.[2] The cause of localized dissection was uncertain in our case. The ascending aorta was cross-clamped, however, partial aortic clamping had not been applied during the previous surgery.

Surgical treatment of delayed aortic dissection depends on the extent of dissection and the entry site. The surgical procedure is closed aortic plication repair, patch closure or the pericardium and graft replacement of the ascending aorta.[3] In our case, the dissection was localized to the right side of the ascending aorta and patch closure seemed reasonable.

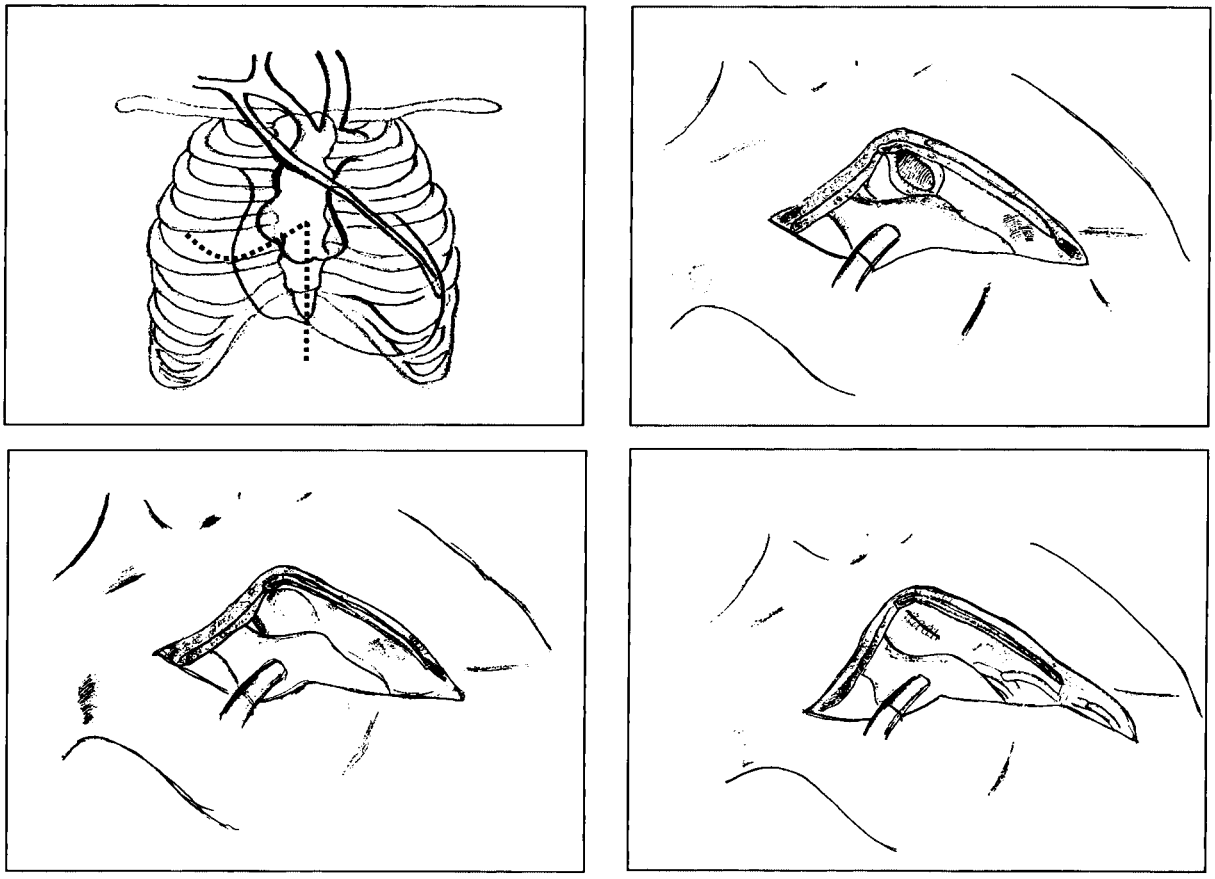

Fig. 3. The operative schema.
a: Skin incision line.
b: A fourth right antero-axillar thoracotomy combined with lower half sternotomy reveals the right side of the ascending aorta, the right atrium and the RCA. The shaded zone is an aneurysm.
c: After opening the aneurysm and removal of the intima, patch closure is performed with a Hemashield patch.
d: CABG to RCA #3 with a right gastroepiploic artery and saphenous vein composite graft.

a	**b**
c	**d**

Redo CABG causes greater mortality and morbidity than the primary operation. Thus, less invasive approaches such as "no touching of any previous patent graft" seems desirable, especially in a case such as ours with a functional RITA to LAD.[4] In the presence of a midline-crossing ITA graft, a median sternotomy may jeopardize the graft and compromise hemodynamics. There are an increasing number of reports about minimally invasive CABG after the widespread use of off-pump coronary artery bypass grafting (OPCAB).[5,6] Several approaches to the RCA have been reported in minimally invasive OPCAB.[7] In our case, RCA was well visualized by lower half sternal splitting combined with right thoracotomy, without "touching" the functional RITA.

Risks of cardiac injury and catastrophic hemorrhage are associated with a resternotomy, involving subsequent elevated morbidity and mortality. Special care must be taken especially in cases where dense adhesions between the aorta and sternum exist. There are some reports describing safe sternal reentry in redo cardiac surgery.[8] In the present case, the ascending aneurysm was dissected apart from the sternum from a fourth right intercostal thoracotomy combined with a lower half sternotomy. This technique provides direct vision between the aorta and sternum, and makes a safe sternal reentry possible.

We successfully treated delayed chronic type A dissection following CABG with a functional midline crossing RITA. Treatment of delayed type A dissections tends to be complicated and more challenging with a functional graft after CABG. Safe and less invasive surgical strate-

gies should be considered and implemented in such complicated cases.

References

1. Orszulak TA, Pluth JR, Schaff HV, Piehler JM, Smith HC, McGoon DC. Results of surgical treatment of ascending aortic dissections occurring late after cardiac operation. *J Thorac Cardiovasc Surg* 1982; **83**: 538–45.
2. Hagl C, Ergin MA, Galla JD, et al. Delayed chronic type A dissection following CABG: implications for evolving techniques of revascularization. *J Card Surg* 2000; **15**: 362–7.
3. Gott JP, Cohen CL, Jones EL. Management of ascending aortic dissections and aneurysms early and late following cardiac operations. *J Card Surg* 1990; **5**: 2–13.
4. Naito H, Kawata T, Mizuguchi K, et al. Re-coronary artery bypass grafting using a MIDCAB technique in a patient with a patent RITA-LAD graft. *Kyobu Geka* 1999; **52**: 1025–8. (in Japanese)
5. Subramanian VA. Clinical experience with minimally invasive reoperative coronary bypass surgery. *Eur J Cardiothorac Surg* 1996; **10**: 1058–62.
6. Niinami H, Takeuchi Y, Higashita R, Suda Y, Ogasawara H. Lower-end sternal splitting (LESS) approach as a new strategy for minimally invasive off-pump CABG. *Kyobu Geka* 2001; **54**: 283–7. (in Japanese)
7. Troise G, Brunelli F, Cirillo M, et al. Ministernotomy in myocardial revascularization without cardiopulmonary bypass: technical aspects and early results. *Heart Surg Forum* 2002; **5**: 168–72.
8. O'Brien MF, Harrocks S, Clarke A, Garlick B, Barnett AG. How to do safe sternal reentry and the risk factors of redo cardiac surgery: a 21-year review with zero major cardiac injury. *J Card Surg* 2002; **17**: 4–13.