Case Report

The Distal Perfusion First Technique for Complicated Stanford Type B Aortic Dissection

Kenji Okada, MD, Taijiro Sueda, MD, Kazumasa Orihashi, MD, Katsuhiko Imai, MD, Kazuhiro Kochi, MD, and Yuji Sugawara, MD

We present a new technique, which is the distal perfusion first technique, for chronic dissection with dilatation of the aorta. Using a "side-ways-τ shaped" incision, this technique allows single-staged repair, full-time antegrade perfusion, less possibility of mesenteric malperfusion and cerebral embolism. (Ann Thorac Cardiovasc Surg 2004; 10: 61–3)

Key words: aortic dissection, malperfusion, descending aortic aneurysm

Introduction

Although graft replacement with a left thoracotomy using femoral cannulation is suitable for repair of type B dissection, mesenteric malperfusion may cause severe complications. In chronic dissection with dilatation of the aorta, two-stage surgery is mandatory, involving aortic fenestration with graft replacement of the abdominal aorta, followed by graft replacement of the diseased aorta. We report a safe and effective procedure, the distal perfusion first technique which enables one-stage surgery, and which avoids mesenteric malperfusion in type B dissection.

Case Report

A 72-year-old male was diagnosed with an aneurysm of the descending aorta with type B dissection and subsequently admitted to our hospital.

Angiography and computed tomography (CT) revealed a type B dissection starting 3 cm below the left subclavian artery and continuing down to both common iliac arteries. The descending aorta was dilated to 7 cm in diameter, though the abdominal aorta was almost normal in size. Between the celiac artery and the left renal artery, the abdominal aorta was dissected into three lumens. The dissection extended to involve the celiac and the supra mesenteric artery. Both the renal arteries were perfused from only the false lumen. (Fig. 1A). Echocardiography demonstrated aortic valve regurgitation (II), thus graft replacement of the descending aorta was performed.

The right axillary artery was dissected and clamped. An expanded polytetrafluoroethylene (ePTFE) prosthesis (8 mm in diameter, Gore-Tex™, W.L. Gore & Associates, Inc., Flagstaff, AL) was anastomosed in an end-to-side fashion to the artery. A left submammary anterior thoracotomy incision was made with the left incision extending laterally to the mid-axillary line and a central incision extending along the lower part of the sternum (Fig. 2) was made. The thoracic cavity was entered through the fourth intercostal space, and the left lower part of the sternum was divided vertically. The left lung was then deflated and retracted cephalad. The pericardium was opened. The anterior mediastinal structures were exposed sufficiently to allow venous cannulation. Cardiopulmonary bypass (CPB) was established with right atrial vein drainage and through a right axillary arterial cannula via the conduit. After a left ventricular vent was placed into the right superior pulmonary vein, perfusion cooling was initiated to a rectal temperature of 20°C and exposure of the ascending aorta, the arch and the descending aorta was obtained. As soon as the rectal temperature reached 25°C, the aneurysm was clamped in the mid portion of the descending aorta and the lower body was put into circulatory arrest. The distal site of the aneurysm was then opened. All lumbar arteries were sacrificed immediately, because the amplitude of motor evoked potential (MEP)

From Department of Cardiovascular Surgery, Graduate School of Biomedical Sciences, Hiroshima University, Hiroshima, Japan

Received April 30, 2003; accepted for publication September 9, 2003.
Address reprint requests to Kenji Okada, MD: Department of Cardiovascular Surgery, Graduate School of Biomedical Sciences, Hiroshima University, 1-2-3 Kasumi, Minami-ku, Hiroshima 734-8551, Japan.

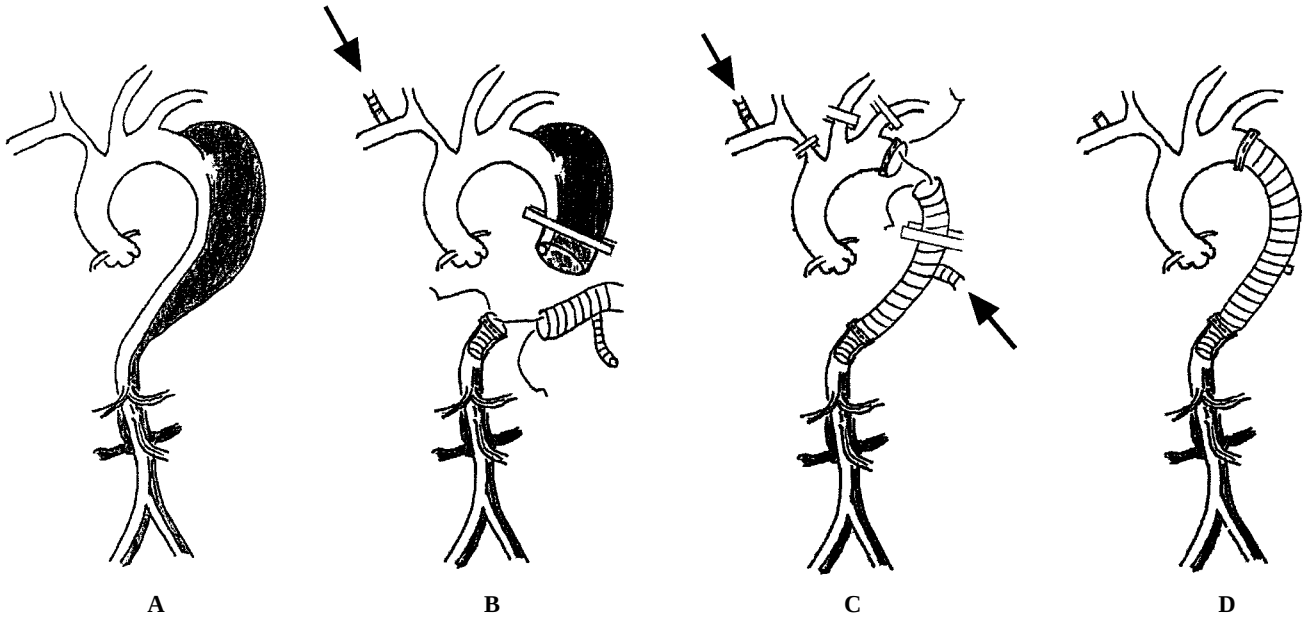

Fig. 1. Schema of distal perfusion first technique. Arrows showed perfusion sites.
A: Preoperative condition. The descending aorta was dilated aneurysmally for a distance of 7 cm diameter, thought the abdominal aorta was almost normal in size. The dissection extended into the celiac and supra mesenteric arteries. Both renal arteries were perfused from only the false lumen.
B: The aneurysm was clamped in the mid portion of the descending aorta. The upper body was circulated via the right axillary artery. Under circulatory arrest in the lower body, a fenestration was made and then open distal anastomosis with an elephant trunk was performed.
C: During open proximal anastomosis, the distal and cerebral perfusion was maintained via the branch conduit and the right axillary artery respectively.
D: Postoperative condition.

was not changed at all. The aorta was tailored, by isolating a thumb-sized flap to make a palliative fenestration to permit perfusion of both lumens. Then an elephant trunk was placed in the aorta, and a 24-mm diameter prosthesis with one branch (Hemashield Gold™, Meadox Medicals Inc., Oakland, NJ) was anastomosed to the edge of the aorta (Fig. 1B). As soon as possible after anastomosis, the prosthesis was clamped and distal perfusion via the branch conduit was reestablished. Cooling was continued until 20°C via the right axillary artery and the branch respectively. At 20°C the ascending aorta was clamped and antegrade cardioplegia was administered, achieving cardiac arrest. The proximal sites of the three cervical vessels were then clamped and cerebral perfusion (800 ml/min) via the right axillary artery was established. Open proximal anastomosis was then performed. During open proximal anastomosis, distal perfusion was maintained via the branch conduit (Fig. 1C). After completion of the proximal anastomosis, all clamps on the ascending aorta and the cervical vessels were removed, and systemic rewarming perfusion was established through the right axillary artery (Fig. 1D). The body was rewarmed and the heart began to pulsate spontaneously. Weaning of CPB was uneventful. CPB time was 316 min and circulatory arrest time was 76 min. The postoperative course was uneventful.

Discussion

In chronic dissection with dilatation of the aorta, rerouting blood into the true lumen after aortic repair can have unpredictable effects on visceral and lower-extremity perfusion. Moreover, during thoracic aortic repair, retrograde perfusion of the aorta from the femoral cannula may not permit perfusion of vital organs, especially the heart and brain. Preceeding aortic fenestration with graft replacement of the abdominal aorta in patients with a diseased aorta provides a secure CPB even with retrograde perfusion via femoral arterial cannulation, and results obtained with this two-stage surgery have been satisfac-

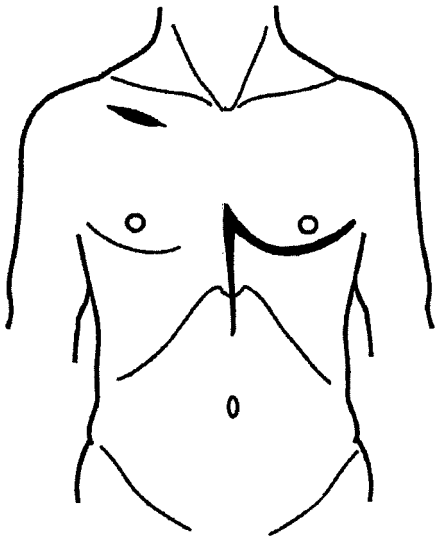

Fig. 2. A "side-ways-τ shaped" incision was utilized, involving a left submammary anterior thoracotomy incision and a central incision along the lower part of the sternum.

tory.[1] Although, with a second operation, malperfusion of the bowels can be avoided, the risk of cerebral embolism or maldistribution of flow still remain.

This technique permits single-stage repair of chronic dissection with dilatation of the aorta, and has minimal risk of malperfusion and stroke because both the upper and the lower part of the body always enable antegrade systemic blood flow perfusion intraoperatively. This method constitutes a unique and useful procedure, which permits repair with a single surgery.

Westaby et al. demonstrated thoracotomy transversely across the sternum to expose the entire thoracic aorta.[2] This "side-ways-τ shaped" incision provides a large operative field encompassing the cervical vessels and the whole thoracic aorta. This incision in combined with the right axillary cannulation, antegrade systemic perfusion, left ventricular venting, antegrade cardioplegia and selective cerebral perfusion can be done simply. Selective cerebral perfusion through the three cervical vessels can be done with ease, although in this patient the period of proximal anastomosis was sufficiently short so that right axillary perfusion was adequate.

Rokkas and Kouchoukos[3] first reported "the arch-first technique" for single-stage extensive replacement of the thoracic aorta. They demonstrated a very useful technique, which enabled a single-stage repair in cases of extended disease, although retrograde systemic perfusion using femoral arterial cannulation was mandatory. Compared with their method, our method has the additional advantage of requiring less time, because the distal anastomosis can be performed during the cooling perfusion period.

This procedure is an alternative method for repair of a descending aortic aneurysm with chronic dissection, which allows single-staged repair, full-time antegrade perfusion, and which reduces the possibility of malperfusion and cerebral embolism.

References

1. Okita Y, Takamoto S, Ando M, Morota T, Kawashima Y. Surgical strategies in managing organ malperfusion as a complication of aortic dissection. *Eur J Cardiothorac Surg* 1995; **9**: 242–7.
2. Westaby S, Katsumata T. Proximal aortic perfusion for complex arch and descending aortic disease. *J Thorac Cardiovasc Surg* 1998; **115**: 162–7.
3. Rokkas CK, Kouchoukos NT. Single-stage extensive replacement of the thoracic aorta: the arch-first technique. *J Thorac Cardiovasc Surg* 1999; **117**: 99–105.