Case Report

Dissection of Intima on Atrial Septum Patch after Mitral Valve Replacement in a Patient with Infective Endocarditis after Incomplete Atrio-ventricular Septal Defect Repair: Report of a Case

Hisayoshi Osawa, Tatsuya Saitoh, Satoru Sugimoto, Nobuyuki Takagi, and Tomio Abe

We encountered a very rare lesion, which included a dissection between a prosthetic patch for repair of an incomplete atrio-ventricular septal defect (AVSD) and a pseudo-intima which had developed. This is the first report of a dissection between an atrial septum patch and pseudo-intima after mitral valve replacement (MVR) in a patient with infective endocarditis following an incomplete AVSD repair. Dissection of the left atrial wall or atrial septum after MVR is extremely rare although some case reports have been published. (Ann Thorac Cardiovasc Surg 2004; 10: 124–5)

Key words: incomplete atrio-ventricular septal defect, dissection of atrial septum patch, mitral valve replacement

Introduction

Mitral valve replacement (MVR) after repair of an atrio-ventricular septal defect (AVSD) is sometimes accompanied with some technical problems including a partial defect of mitral valve annular ring and poor inferior view of the heart because of the scooped out inlet ventricular septum.[1] These circumstances can be serious especially when the mitral procedure is performed in a patient with severe endocarditis, since the mitral leaflet cannot be used for fixation of a prosthetic valve. We encountered a dissection between an atrial patch and the pseudo-intima which had developed following MVR in a patient with infective endocarditis. The patient had previously undergone an incomplete AVSD repair. In our report, we discuss the possible mechanism of the dissection and prevention of such a condition.

Case Report

A 24-year-old male consulted our clinic because of a chilly fever lasting for one month and general malaise on April 21st 1999. The patient had undergone a prosthetic patch closure concomitantly with mitral valve cleft repair for an incomplete AVSD at the age of 4. Subsequently, a moist rale at the bilateral lower lung field and systolic regurgitant murmur at the apex were audible. An echocardiogram revealed vegetation attached to the anterior mitral leaflet and the posterior wall of the left atrium. These findings led to a diagnosis of infective endocarditis of the mitral valve following AVSD repair. Deteriorated hemodynamics indicated urgent surgery.

MVR was performed via a re-median sternotomy. After the left atrium was opened just posteriorly to the right interatrial groove, multifocal vegetation was identified on the left atrial inner surface. The posterior mitral leaflet also had severe inflammatory edematous change. The leaflets were completely resected and the annulus and the intra-atrial infectious tissue were aggressively debrided. Everted mattress sutures of pledgetted 2-0 polyester sutures were placed for the MVR. We completed the surgical procedure of MVR with a 27 M St. Jude Medics (St. Jude Medical, Inc., AZ, USA).

The inflammatory signs were dramatically reduced, however, an echocardiogram at the 7th postoperative day demonstrated a small amount of perivalvular leakage. We were concerned that the leakage might be a sign of detachment of the prosthesis resulting from revived inflammation. The cardiac condition was evaluated with a transesophageal

From Department of Thoracic and Cardiovascular Surgery, Sapporo Medical University School of Medicine, Sapporo, Japan

Received September 1, 2003; accepted for publication October 3, 2003.
Address reprint requests to Hisayoshi Osawa: Department of Thoracic and Cardiovascular Surgery, Sapporo Medical University School of Medicine, South-1, West-16, Chuo-ku, Sapporo 060-8556, Japan.

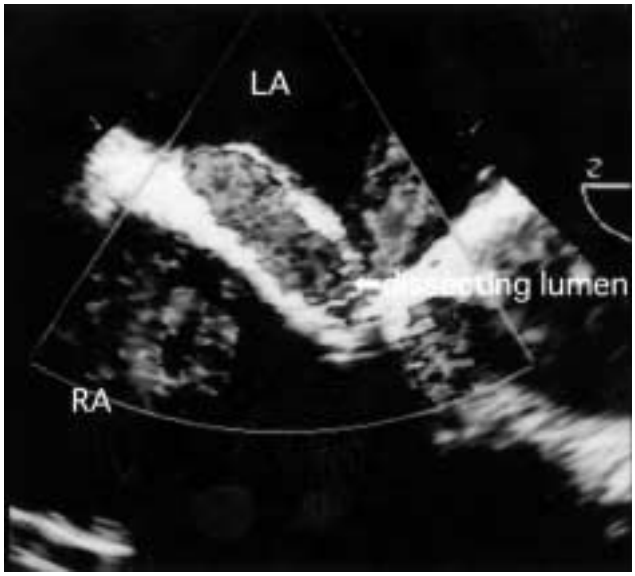

Fig. 1. Transesophageal echocardiography revealed an abnormal cavity between the atrial patch of a previous operation and a pseudo-intima. It is a dissection of the intima on the atrial septum patch. LA, left atrium; RA, right atrium.

echocardiography, which revealed an eccentric mitral regurgitant flow, entering the interatrial septum at the anterior annulus, then to the inner-atrial septum and exiting from the septum to the left atrial cavity (Fig. 1). We suspected that the intra-mural abnormal flow existed between the patch and the pseudo-intima on the patch, since the septum consisted almost fully of the prosthetic patch made of a very firm fabric polytetrafluoroethylene (W.L. Gore & Associates, Inc., Flagstaff, AZ, USA).

The patient has been very well for 30 months postoperatively without any abnormal symptoms. A transesophageal echocardiogram shows no change of the atrial septum dissection.

Discussion

To the best of our knowledge, reports of a left atrial dissection are limited to only six publications,[2-7] which had occurred mainly after mitral valve operation. Although the mechanism of this condition is still unclear, injury of the annular tissue was presumably caused during surgery.[2,4,5] Annular injury occurs in cases of excessive resection of the mural leaflet or calcified annular tissues. These are possible complications in a patient undergoing a mitral valve operation. Our patient, however, had a peculiar problem in that it occurred after repair of an incomplete AVSD. An AVSD is characterized with a scooped out inlet ventricular septum and no normal annular tissues between the mitral and the tricuspid valve.[1] This should be reconstructed using a patch, and it can cause deeply sought mitral valve annulus abutting the atrial septum toward the cardiac apex and a somewhat fragile annulus to fix a valve prosthesis. For these reasons, a surgeon sometimes has difficulty in performing a mitral valve operation in a patient with a repaired AVSD. We also had serious difficulty in our case when placing buttressed stitches for fixation of the prosthetic valve. A needle could easily tear a part of the pseudo-intima on the patch, and this tear could result in a pathway of abnormal blood flow from the ventricle to the dissected space, even if the stitch was placed correctly on the annulus which had been previously reconstructed with a synthetic patch.

So, MVR in a patient with repaired AVSD could be better treated in some cases via a superior septal approach to get a clearer operative interior view.[8] This is especially true in the reconstructed valve annulus and aggressive resection of a pseudo-intima which might be an intra-atrial flap resulting from dissection after mitral valve operation.

References

1. Pillai R, Yen Ho S, Anderson RH, Lincoln C. Ostium primum atrioventricular septal defect. *Ann Thorac Surg* 1986; **41**: 458–61.
2. Maeda K, Yamashita C, Shiba T, Okada M, Nakamura K. Successful surgical treatment of dissecting left atrial aneurysm after mitral valve replacement. *Ann Thorac Surg* 1985; **39**: 382–4.
3. Li Mandri G, Schwartz A, Rose EA, et al. Atrial septal dissection after mitral valve replacement demonstrated by transesophageal echocardiography. *Am Heart J* 1994; **127**: 219–21.
4. Goda T, Ishii K, Shiiya N, Oba J, Matsui Y, Yasuda K. Acute dissection of the interatrial septum after re-replacement of the mitral valve: a case report. *Nippon Kyobu Geka Gakkai Zasshi* 1994; **42**: 1092–5. (in Japanese)
5. Sekino Y, Sadahiro S, Tabayashi K. Successful surgical repair of left atrial dissection after mitral valve replacement. *Ann Thorac Surg* 1996; **61**: 1528–30.
6. Genoni M, Jenni R, Schmid ER, Vogt PR, Turina MI. Treatment of left atrial dissection after mitral repair: internal drainage. *Ann Thorac Surg* 1999; **68**: 1394–6.
7. Gregorio OD, Nardi C, Milano A, Carlo MD, Grana M, Bortolotti U. Dissection of atrial septum after mitral valve replacement. *Ann Thorac Surg* 2001; **71**: 1670–2.
8. Berreklouw E, Ercan H, Schonberger JP. Combined superior-transseptal approach to the left atrium. *Ann Thorac Surg* 1991; **51**: 293–5.