Case Report

Blunt Injury of Proximal Innominate Artery

Hitoshi Hirose, MD, FACS, and Inderjit S. Gill, MD, FACS

Innominate artery injury after blunt trauma is uncommon. We present a case of innominate artery injury, successfully treated with aorto-innominate bypass. (Ann Thorac Cardiovasc Surg 2004; 10: 130–2)

Key words: blunt trauma, innominate artery, chest injury

Introduction

Innominate artery injury is an uncommon vascular injury after blunt chest trauma. Our previous study in 1997 showed that blunt innominate artery injury was found in 60 case reports and a total of 117 patients in the English literature.[1] Since then, only a few case reports of blunt innominate artery injury have been published.[2-5] Here, we present another case of innominate artery injury, which was successfully treated with aorto-innominate bypass.

Case Presentations

A 46-year-old male was transferred from another hospital after involvement in a motor vehicle accident. The patient was intubated and a chest tube was placed in the left chest, but he was fully awake and followed commands. Blood pressure discrepancy between the arms was noted (159/97 mmHg on the left arm, 110/50 mmHg on the right arm). Chest X-ray showed widening mediastinum (Fig. 1) and CT scan demonstrated mediastinal hematoma surrounding the innominate artery (Fig. 2). Angiography revealed proximal innominate artery injury (Fig. 3).

He was emergently taken to an operating room. Prior skin incision, bronchoscopy and esophagoscopy was performed to rule out tear in the bronchial tree or in the esophagus. Both of these were negative. Then, a median sternotomy was performed. The innominate vein was taped and retracted away. The strap muscles were divided, and the innominate artery was traced up to its bifurcation. There was an adventitial hematoma that extended the entire length of the innominate artery. The innominate artery was carefully immobilized in its entire length. The pericardium was opened and the ascending aorta was exposed. No hemopericardium was noted and the ascending aorta was intact. The patient was given 5,000 units of heparin. A partial occluding clamp was applied onto the ascending aorta, and a 10 mm Dacron graft was sutured with 4-0 prolene. A healthy part of the distal innominate artery just below the bifurcation was transected under proximal and distal control of the right common carotid, right subclavian artery and innominate artery. The graft was passed under the innominate vein. Then, distal anastomosis to the innominate artery was performed in an end-to-end fashion with 5-0 prolene. After completion of the distal anastomosis, the distal occlusion clamps were removed. The temporary occlusion time of the innominate artery was approximately 15 minutes. The origin of the innominate artery at the arch was then fully exposed and it was oversewn with multiple pledgeted 3-0 prolene sutures. The sternum was closed after adequate hemostasis. Postoperative course was steady and uncomplicated.

Discussion

The majority of innominate artery injury by blunt trauma occurs at its origin,[1] as we reported here. Anatomically, the innominate artery is tightly fixed onto the aortic arch while the distal part is relatively mobile and flexible. Abrupt deceleration causes simultaneous hyperextension

From Department of Thoracic and Cardiovascular Surgery, The Cleveland Clinic Foundation, Ohio, USA

Received September 1, 2003; accepted for publication September 30, 2003.
Address reprint requests to Hitoshi Hirose, MD, FICS: Department of Thoracic and Cardiovascular Surgery, The Cleveland Clinic Foundation, 2500 Metrohealth Drive, 3rd Floor, Cleveland, OH 44109, USA.

Fig. 1. Chest X-ray shows mediastinum widening. A chest tube was inserted due to pneumothorax.

Fig. 2. CT scan of the chest shows mediastinal hematoma and flap at the base of the innominate artery.

of the neck and rotation of the head, which create great tension to the bases of aortic branches. Chest concussion causes sudden increase of intra-mediastinal pressure, which may travel through the upper mediastinum to the neck. This may result in further stretching of the aortic branches. Both mechanisms combined to import maximum shear stress at the origin of the innominate artery, and cause proximal injury.[6)]

Innominate artery injury can be suspected by chest X-ray revaling widening of the mediastinum or blood pressure discrepancy between left and right arms. Free bleeding and hemorrhagic shock is rare in blunt innominate artery injury and hematoma is usually contained in the upper mediastinum. Small mediastinal hematoma may not be detected by chest X-ray but can be detected by CT scan.[2)] All patients with suspicious mediastinal hematoma require angiography to rule out great vessel injury.[1)]

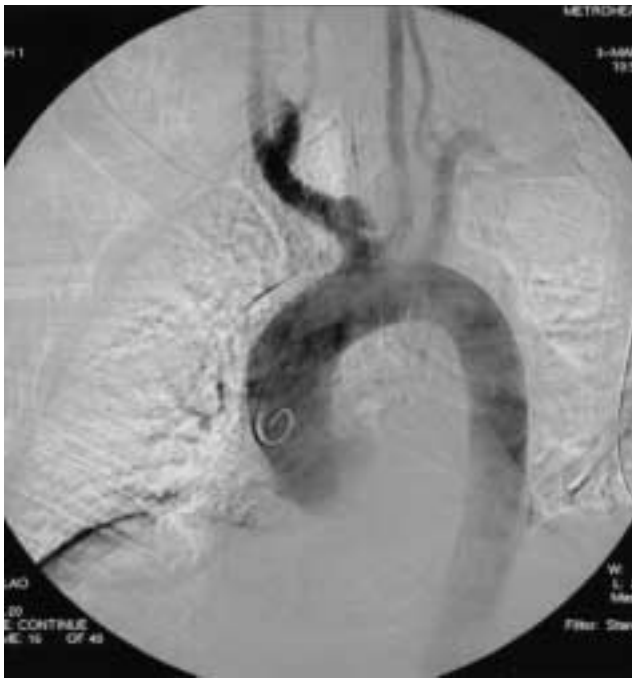

Fig. 3. Angiography of the aortic arch and great vessels of the patient. Intimal flap and a pseudoaneurysm is observed at the origin of the innominate artery.

Surgical approach to the innominate artery is usually by median sternotomy with extension of the right neck, which can provide sufficient exposure for the aorta and entire course of the innominate artery.[1)] Cerebral protection, cardiopulmonary bypass, retrograde perfusion, electroencephalogram monitoring, cardiopulmonary bypass, hypothermia, carotid shunting or back pressure monitoring should be used for the patients with neurological abnormalities on admission, or suspected bilateral carotid artery involvement.[1)] Healthy young individuals usually can tolerate temporary occlusion of the innominate artery because of sufficient collateral flow from the contralateral carotid and vertebral arteries. Either primary repair or aorto-innominate bypass has been performed for reconstruction of the innominate artery.[1)] The reported long-term patency rates of aorto-innominate artery bypass are greater than 96% at 10 years.[7)]

Conclusion

In summary, innominate artery injury can be suspected by physical exams, chest X-ray or CT scan and diagnosed by angiogram. Primary repair or aorto-innominate bypass is the treatment of choice.

References

1. Hirose H, Moore E. Delayed presentation and rupture of a posttraumatic innominate artery aneurysm: case report and review of the literature. *J Trauma* 1997; **42**: 1187–95.
2. Kalangos A, Panos A, Dechamboux R, Faidutti B. Disruption of the aortic arch convexity containing the innominate and left common carotid artery origins resulting from blunt trauma. *J Thorac Cardiovasc Surg* 1997; **114**: 129–31.
3. Weiman DS, McCoy DW, Haan CK, Pate JW, Fabian TC. Blunt injuries of the brachiocephalic artery. *Am Surg* 1998; **64**: 383–7.
4. Stover S, Holtzman RB, Lottenberg L, Bass TL. Blunt innominate artery injury. *Am Surg* 2001; **67**: 757–9.
5. Anastasiadis K, Channon KM, Ratnatunga C. Traumatic innominate artery transection. *J Cardiovasc Surg (Torino)* 2002; **43**: 697–700.
6. Feliciano DV. Trauma to the aorta and major vessels. *Chest Surg Clin N Am* 1997; **7**: 305–23.
7. Kieffer E, Sabatier J, Koskas F, Bahnini A. Atherosclerotic innominate artery occlusive disease: early and long-term results of surgical reconstruction. *J Vasc Surg* 1995; **21**: 326–37.