Original Article

Abdominal Surgery Following Coronary Artery Bypass Grafting Using an in situ Right Gastroepiploic Artery Graft

Keiju Kotoh, MD, Kazuaki Fukahara, MD, Motoharu Tsuda, MD, Kazuhiro Tukada, MD, and Takuro Misaki, MD

Objective: The usefulness of the gastroepiploic artery (GEA) as arterial grafts in coronary artery bypass grafting (CABG) has been studied extensively. We report our experience performing abdominal surgery after CABG using in-situ GEA.
Methods: The subjects were eight patients who underwent abdominal surgery after CABG with an in situ GEA graft. The surgical indications were malignant tumors in five patients, an infrarenal abdominal aortic aneurysm in two patients and a diaphragmatic hernia in one patient. The interval from the CABG to the abdominal surgery ranged from 3 to 19 months.
Results: Operations included distal gastrectomy in two cases, total gastrectomy in one case, local excision of the stomach in one case, and excision of the transverse colon in one case. Aortobiiliac artery bypass was performed in two cases, and the diaphragmatic hernia was reconstructed using standard techniques. When the skeletonization method has been used to harvest the GEA, GEA grafts were easily identified during a laparotomy, and the abdominal procedure was performed using routine methods. One patient died of cancer, and the other patients are alive 1 year 2 months to 4 years 5 months after surgery. No patient reported recurrence of angina.
Conclusion: The risk of abdominal reoperations should be considered when using the in situ right GEA for CABG. We recommend the skeletonization method for GEA harvest to decrease the difficulty during second abdominal operations. (Ann Thorac Cardiovasc Surg 2004; 10: 97–100)

Key words: right gastroepiploic artery graft, coronary artery bypass grafting, gastric cancer, abdominal aortic aneurysm

Introduction

The usefulness of gastroepiploic artery (GEA) for arterial grafts in coronary artery bypass grafting (CABG) has been extensively studied,[1] and some reports have focused on gastric cancer in combination with the use of GEA.[2,3] We report eight patients who underwent abdominal surgery after CABG using a GEA, the effectiveness of GEA as well as a method for harvesting these during reoperation is discussed.

From Department of Surgery, Toyama Medical and Pharmaceutical University, Toyama, Japan

Received October 9, 2003; accepted for publication November 12, 2003.
Address reprint requests to Keiju Kotoh, MD: Department of Surgery, Toyama Medical and Pharmaceutical University, 2630 Sugitani, Toyama 930-0194, Japan.

Patients and Methods

Eight patients (seven men and one woman, mean age 69.5 years, range 59 to 79 years) who underwent abdominal surgery after CABG with in situ GEA graft (Table 1). Seven patients had received a right coronary artery GEA bypass graft, and one patient had received a sequential bypass graft to the right coronary artery and circumflex artery by extending the GEA with the radial artery. GEA were collected by the pedicle method in one case and by the skeletonization method[4,5] in seven cases. In all cases, we employed the antegastric route for a GEA graft.

The indication for abdominal surgery was malignant tumors in five patients (one with advanced gastric cancer, three with early gastric cancer, and one with advanced transverse colon cancer), two patients had infrarenal abdominal aortic aneurysms, and one patient had a diaphrag-

Table 1. Operative data of the first CABG

	Patient 1	Patient 2	Patient 3	Patient 4	Patient 5	Patient 6	Patient 7	Patient 8
Age at CABG (y)	79	64	59	72	75	70	72	61
Gender	F	M	M	M	M	M	M	M
Method	Off-pump sternotomy	Off-pump sternotomy	Off-pump thoracotomy	Off-pump sternotomy	On-pump sternotomy	Off-pump thoracotomy	Off-pump sternotomy	Off-pump sternotomy
No. of grafts	3	3	4	3	4	2	3	3
Arterial grafts	LITA, GEA, RA	LITA, GEA	LITA, GEA, RA, IEA	LITA, GEA, RA	LITA, GEA, RA, IEA	LITA, GEA	LITA, RITA, GEA	LITA, RITA, GEA
Distal anastomoses	LAD, OM, PD	LAD, OM, RCA	LAD, OM, Cx, PD	LAD, OM, PD	LAD, D, OM, RCA	LAD, PD	LAD, OM, PL	LAD, OM, PD

CABG, coronary artery bypass grafting; LITA, left internal thoracic artery; GEA, gastroepiploic artery; RA, radial artery; LAD, left anterior descending artery; OM, obtuse marginal branch; PD, posterior descending artery; RCA, right coronary artery; IEA, inferior epigastric artery; Cx, circumflexus artery; D, diagonal branch; RITA, right internal thoracic artery; PL, posterior lateral artery.

Table 2. Outcome of patients undergoing abdominal surgery after gastroepiploic coronary artery bypass graft

	Patient 1	Patient 2	Patient 3	Patient 4	Patient 5	Patient 6	Patient 7	Patient 8
Diagnosis	Early GC	Early GC	Early GC	Advanced GC	Advanced CC	AAA (5 cm)	AAA (6 cm)	Diaphragmatic hernia
Interval of operations (y/mo)	10 mo	1 y 7 mo	1 y 5 mo	1 y 2 mo	3 mo	3 mo	4 mo	1 y 1 mo
Abdominal operation	Local excision	Distal gastrectomy	Distal gastrectomy	Total gastrectomy	Excision of the colon	Y-graft	Y-graft	Patch plasty
GEA graft harvest	Skeletonized	Skeletonized	Skeletonized	Skeletonized	Pedicle	Skeletonized	Skeletonized	Skeletonized
Distal anastomoses of GEA graft	PD	RCA	PD, Cx	PD	RCA	PD	PL	PD
Identification of GEA graft	Easy	Easy	Easy	Easy	Difficult	Easy	Easy	Easy
GEA graft injury	No	No	No	No	Yes/reanastomosis	No	No	No
Cardiac event	No	No	No	No	No	No	No	No
Follow-up (y/mo)	Alive (2 y 6 mo)	Alive (1 y 4 mo)	Alive (3 y 8 mo)	Alive (3 y 5 mo)	Died of cancer (11 mo)	Alive (4 y 5 mo)	Alive (2 y 2 mo)	Alive (1 y 2 mo)

GEA, gastroepiploic artery; GC, gastric cancer; CC, colon cancer; AAA, infrarenal abdominal aortic aneurysm; PD, posterior descending artery; RCA, right coronary artery; Cx, circumflexus artery; PL, posterior lateral artery.

matic hernia. The interval from the CABG to the abdominal surgery ranged from 3 to 19 months. Moreover, none of the patients with cancer had the tumor prior to the CABG. In six cases, celiac angiography was performed prior to abdominal surgery to confirm GEA graft patency.

Results

Two patients underwent a distal gastrectomy (Billroth-I reconstruction) for gastric cancer. A total gastrectomy, local excision proximal to the pylorus and excision of the transverse colon was performed in one patient each. In one case, local gastric excision was performed because the patient had liver cirrhosis with poor hepatic reserve and was felt to be unable to tolerate a more extensive resection. In the two patients with an abdominal aortic aneurysm, aortobiiliac artery bypass was performed with Y-graft. Abdominal aortic surgery was carried out 3 and 4 months after CABG as elected by the patients. In the case of diaphragmatic hernia, the transverse colon and omentum were found in the pericardial sac. The hernia appeared to have enlarged from the diaphragmatic incision to accommodate the GEA graft. The pulsations of the GEA graft were good and the hernia was repaired using a nonresoluble surgical patch (Table 2).

When the skeletonization method had been used, the GEA grafts were identified on the upper surface of the left lateral segment of the liver, and adhesions to the liver and the gastric serosa were very mild (Fig. 1). However, when the pedicle method had been used, the GEA graft could not be identified and the GEA was injured during dissection, requiring re-anastomosis to the middle colic artery.

In four cases of gastric cancer in which we had employed the skeletonization method, the pyloric branch of the GEA was completely cut-off, and vascular dissection to the bifurcation of the gastroduodenal artery was easy to perform. Standard methods (Table 3) were used for the surgical manipulation of gastric cancer, except when the GEA root was not cut-off (Fig. 2).

The patient with advanced transverse colon cancer died of cancer 11 months after surgery. The other patients are

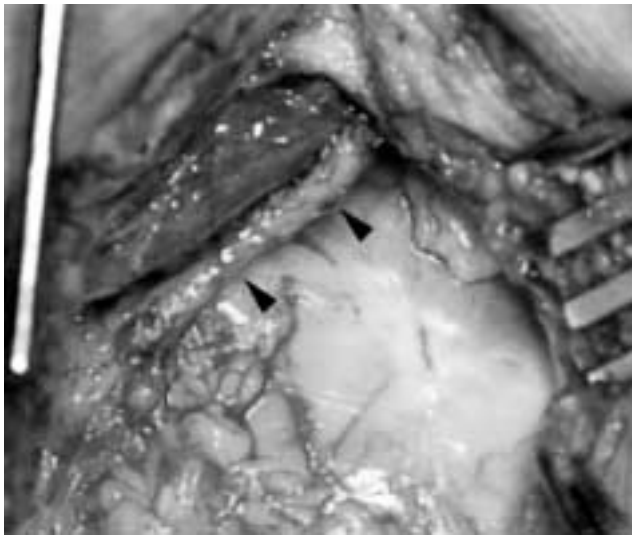

Fig. 1. Skeletonized GEA graft was shown on the left lateral segment of the liver.

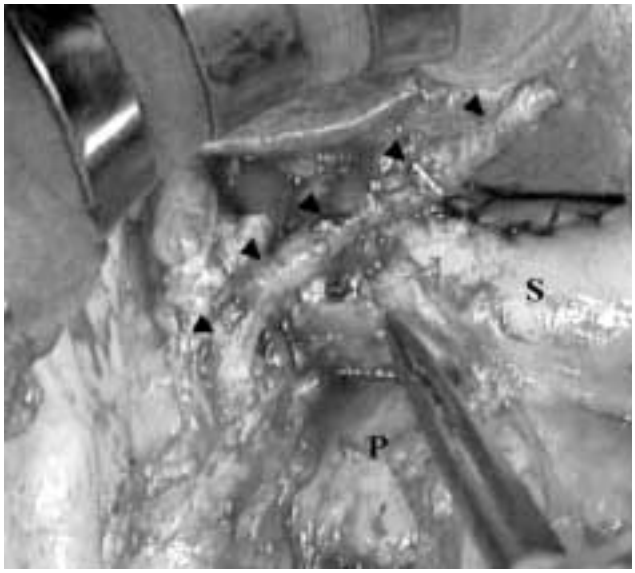

Fig. 2. Dissected GEA graft was shown after a distal gastrectomy (Billroth-I reconstruction). The arrows show the right GEA graft. The point of the forceps is the anastomosis part. The graft is located above the anastomosis. S, stomach; P, pancreas.

alive 1 year 2 months to 4 years 5 months after surgery. No patient reported recurrence of angina.

Discussion

In the present study, we found that the GEA grafts were easily identified as an intraperitoneal vessel during abdominal reoperation when the GEA had been harvested by the skeletonization method. When the vessels were covered with a large amount of fat, it was difficult to discriminate between the falciform ligament and the GEA graft, which might have led to inadvertent injury to the GEA graft during dissection.[6)]

Taking the individual presentation of the gastric cancer into account, it is important to isolate the GEA by completely dividing the pyloric branch during CABG. When the GEA is isolated to the level of the pyloric branch, detachment from the greater curvature was not required during the surgery for gastric cancer and decreased the risk of inadvertent injury. Moreover, the incidence of lymph node metastasis in the distribution of the GEA should decline when lymph flow from the stomach is cut-off.

In summary, we believe that the skeletonization method for harvesting the GEA for CABG decreases the difficulty of performing a second abdominal operation. This is an important consideration as life expectancy increases following CABG.

Table 3. Data of gastric cancer operations

	Patient 1	Patient 2	Patient 3	Patient 4
Diagnosis	Early GC	Early GC	Early GC	Advanced GC
Location of tumor	M, less	L, less	L, ant	M, U, less
Method of operation	Local excision	Distal gastrectomy	Distal gastrectomy	Total gastrectomy
Separated vessels	No	RGA, LGA, CV	RGA, LGA, CV	RGA, LGA, CV
Preserved vessels	RGA, LGA, CV, GEA	GEA	GEA	GEA
Reconstruction	Direct suture	Billroth-I	Billroth-I	Roux-Y
Location of GEA graft	On the antrum	On the anastomosis	On the anastomosis	On the bulbus
Postoperative stage of GC	Stage IA	Stage IA	Stage IA	Stage IB

GEA, gastroepiploic artery; GC, gastric cancer; RGA, right gastric artery; LGA, left gastric artery; CV, coronary vein.

References

1. Suma H, Isomura T, Horii T, Sato T. Late angiographic result of using the right gastroepiploic artery as a graft. *J Thorac Cardiovasc Surg* 2000; **120**: 496–8.
2. Perrault LP, Rheault MJ, Carrier M. Total gastrectomy in a patient with an in situ right gastroepiploic artery graft. *Ann Thorac Surg* 1994; **57**: 751–2.
3. Hayashi S, Kawaue Y, Sueshiro M, Kado S, Ono Y. A case of gastric cancer occurred after coronary artery bypass grafting using the right gastroepiploic artery. *Nippon Kyobu Geka Gakkai Zasshi* 1994; **42**: 105–9. (in Japanese)
4. Gagliardotto P, Coste P, Lazreg M, Dor V. Skeletonized right gastroepiploic artery used for coronary artery bypass grafting. *Ann Thorac Surg* 1998; **66**: 240–2.
5. Asai T, Tabata S. Skeletonization of the right gastroepiploic artery using an ultrasonic scalpel. *Ann Thorac Surg* 2002; **74**: 1715–7.
6. Dietl CA, Deitrick JE, West JC, Pagana TJ. Laparotomy after using the gastroepiploic artery graft: retrogastric versus antegastric route. *Ann Thorac Surg* 1995; **60**: 382–5.