Original Article

Diaphragmatic Plication in Adult Patients with Diaphragm Paralysis after Cardiac Surgery

Yukio Kuniyoshi, MD, PhD, Satoshi Yamashiro, MD, PhD, Kazufumi Miyagi, MD, Toru Uezu, MD, Katsuya Arakaki, MD, and Kageharu Koja, MD, PhD

Objective: We investigated the benefit of diaphragmatic plication for weaning from mechanical ventilation in these adult patients.

Patients and Methods: Four patients underwent diaphragmatic plication for difficulty of weaning from mechanical ventilation due to diaphragmatic paralysis. They were all men with an average age of 70.5±6.3 years. Three of the patients had undergone cardiac surgeries for coronary artery bypass grafting and one patient ascending aortic replacement for pseudoaneurysm after coronary revascularization. Right diaphragmatic plication (muscle sparing procedure) was performed between 30 to 61 days after cardiac surgery.

Results: The mean forced tidal volume improved dramatically from 216 to 415 ml after plication in all patients, and it was possible to discontinue mechanical ventilation from 2 to 12 days after plication. One patient with obstructive respiratory dysfunction died from aspiration pneumonia 15 days after plication. However, postoperative tidal volume in this patient improved to 420 ml and he was able to be weaned from ventilatory support five days after plication. The other three patients were discharged between 26 to 58 days after plication and continue to do well without symptoms.

Conclusion: Diaphragmatic plication is a useful procedure for treatment of diaphragmatic paralysis in adults as well in children. (Ann Thorac Cardiovasc Surg 2004; 10: 160–6)

Key words: diaphragmatic paralysis, cardiac surgery, weaning from mechanical ventilation, diaphragmatic plication, adult

Introduction

Diaphragmatic paralysis (DP) often leads to a delay or prevention of weaning from ventilatory support and is obviously deleterious in children, especially in neonates.[1-5] In adults, however, because respiration is not as totally dependent on diaphragmatic breathing, the difficulty is not as notable as in children. There have been reports addressing the relationship of the use of the internal thoracic artery (ITA) in coronary artery bypass grafting (CABG) and postoperative diaphragmatic injury.[6-8] The incidence of DP after CABG ranged from 10% to 60%.[6,7,9-13] Although DP following cardiac surgery is not uncommon, many researchers have noted that it is transient and of no clinical significance.[1,9,13] However, we encountered four adult patients who were difficult to wean from ventilatory support due to DP after cardiac surgery. They underwent diaphragmatic plication with good results. We investigated the benefit of the diaphragmatic plication for weaning from mechanical ventilation in adult patients.

From Second Department of Surgery, School of Medicine, Faculty of Medicine, University of Ryukyus, Okinawa, Japan

Received October 22, 2003; accepted for publication January 12, 2004.
Address reprint requests to Yukio Kuniyoshi, MD, PhD: Second Department of Surgery, School of Medicine, Faculty of Medicine, University of Ryukyus, 207 Uehara, Nishihara, Okinawa 903-0215, Japan.

Patients and Methods

Between July 2001 and August 2002, four patients (2.4% of all our patients with cardiac surgeries in this period) underwent diaphragmatic plication for difficulty of weaning from ventilatory support due to DP following cardiac surgery. There were all men with an average age of 70.5±6.3 years (range 64 to 81 years). The cardiac surgeries were CABG in three patients and ascending aortic

Table 1. Preoperative clinical profile

Patient No.	1	2	3	4	Mean
Age (years)	64	69	81	68	70.5±6.3
Gender	M	M	M	M	
Diagnosis	AP	AP	AP	Pseud aneurysm of Asc Ao	
Risk					
OMI	–	+	+	–	(2)
DM	+	–	–	–	(1)
HL	–	–	–	–	(0)
HT	+	+	+	+	(4)
Other	PSVT	–	COPD (asthma)	–	
Coronary lesion	3 VD	LMT + 3 VD	3 VD	Post CABG (4 vessels)	
Surgical category	OPCABG	On-pump CABG	OPCABG	Asc Ao replacement	
CABG number	3	3	3	–	3.0±0.0
Used graft	BITA, RA, RGEA	BITA, RGEA	BITA, RA		
Respiratory function					
VC (ml)	2,570	1,800	2,000	2,500	2,217.5±326.2
%VC (%)	87.4	60.1	75.3	72.5	73.8±9.7
$FEV_{1.0}$ (ml)	2,300	1,250	980	1,500	1,507.5±493.1
$FEV_{1.0\%}$ (%)	89.5	76.7	56.8	78.0	75.3±11.8
PaO_2 (mmHg)	90.3	83.8	51.9	70.5	74.1±5.6
$PaCO_2$ (mmHg)	40.5	41.1	49.7	42.5	43.5±3.9

AP, angina pectoris; Asc Ao, ascending aorta; OMI, old myocardial infarction; DM, diabetes mellitus; HL, hyperlipidemia; HT, hypertension; PSVT, paroxysmal supraventricular tachycardia; COPD, chronic obstructive pulmonary disease; 3 VD, three vessels disease; LMT, left main trunk lesion; CABG, coronary artery bypass grafting; OPCABG, off-pump CABG; BITA, bilateral internal thoracic artery; RA, radial artery; RGEA, right gastroepiploic artery; VC, vital capacity; $FEV_{1.0}$, forced expiratory volume in one second.

replacement for pseudoaneurysm after coronary revascularization in one. Preoperative clinical profiles are shown in Table 1. In all patients bilateral ITA was used and each patient underwent three grafting procedures. Off-pump CABG was performed in two patients and on-pump CABG in one. Patients requiring CABG after 1999 were operated on off-pump. In case 2 the patient's coronary artery was very small. We suspected migration and undertook an on-pump CABG. Complications consisted of constrictive respiratory dysfunction for bronchial asthma in one patient and obstructive respiratory dysfunction in another. The patients who underwent ascending aortic replacement suffered a pseudoaneurysm formation at the ascending aortic cannulation site five years after CABG. Bilateral DP occurred in one patient and right DP in three. Although three of the four patients were weaned from mechanical ventilation on postoperative day one, respiratory difficulties were experienced leading to atelectasis due to difficulty of excretion of the sputum and re-ventilation support was needed. The fourth patient was not able to wean from mechanical ventilation because of marked hypoxemia after releasing from positive pressure respiration and extremely low tidal volume. Tracheostomy was performed between 4 to 31 days (mean, 16±11.7 days) after cardiac surgery for exclusion of the dead space and suction of the sputum. However, as the respiratory dysfunction could not be improved, right diaphragmatic plication was performed from 30 to 61 days (mean, 46±11.9 days) after cardiac surgery or from 21 to 36 days (mean, 28±5.6 days) after tracheostomy in all patients.

Surgical procedure

Muscle sparing posterolateral thoracotomy was made in the sixth intercostal space as described by Bethencourt et al.[14] The latissimus dorsi and serratus anterior muscles were spared. The right diaphragm was plicated by a longitudinal U suture with 2-0 polypropylene threads placed in a posterior to anterior direction and reinforced at both ends over a Teflon buttress. The diaphragm was plicated until it became taut.

In the procedure, the diaphragm was plicated upwards, therefore, the diaphragm was strained into a horizontal form.

Results

Postoperative results of cardiac surgery are shown in Table 2. The forced tidal volume before diaphragmatic plication was lower and ranged from 180 to 284 ml (mean, 216±40.1 ml). The forced tidal volume improved dramati-

Table 2. Postoperative results

Patient No.	1	2	3	4	Mean
Complication	DP	DP, pneumonia	DP, ARF	DP, mediastinitis	
DP	Bilateral	Right	Right	Right	
Tracheostomy (POD)	24	5	4	31	16.0±11.7
FEV at time (ml)	284	200	200	180	216.0±40.1
Plication (POD)	53	30	40	61	46.0±11.9
Respirator off (POD) (after plication)	12	5	12	2	7.8±4.3
FEV at time after plication (ml)	460	420	380	400	415.0±29.6
O_2 off (after plication)	14	–	18	20	17.3±2.5
Discharge (after plication)	31	–	26	58	38.3±14.1
Prognosis	Survive	Death	Survive	Survive	(1 death)
Respiratory function					
VC (ml)	1,800	–	1,500	1,500	1,600.0±141.4*
%VC (%)	60.8	–	52.0	54.8	55.9±3.76*
$FEV_{1.0}$ (ml)	1,600	–	880	1,200	1226.7±294.5
$FEV_{1.0\%}$ (%)	88.5	–	58.7	70.0	72.4±12.3
PaO_2 (mmHg)	80.3	–	50.9	68.5	66.6±12.1
$PaCO_2$ (mmHg)	42.5	–	50.8	43.5	45.6±3.7
Follow-up (months)	8		20	17	14.7±5.6

DP, diaphragmatic paralysis; ARF, acute renal failure; POD, postoperative days; FEV at time, forced expiratory volume in one breath; respirator off, mean recovery from ventilator support; O_2 off, mean recovery from oxygen therapy. *$p<0.05$ vs. preoperative value.

cally ranging from 380 to 460 ml (mean, 415±29.6 ml) after diaphragmatic plication in all patients. All patients were able to be weaned from mechanical ventilation from 2 to 12 days (mean, 7.8±4.3 days) after plication. Unfortunately, one patient with obstructive respiratory dysfunction died from aspiration pneumonia 15 days after diaphragmatic plication. However, postoperative tidal volume in this patient improved to 420 ml and he was able to be weaned from ventilatory support five days after plication. The other three patients recovered from oxygen therapy 14 to 20 days after plication (mean, 17.3±2.5 days), and were discharged 26 to 58 days (mean, 38.3±14.1 days) following the procedure. The change of respiratory function and arterial blood gas analysis before cardiac surgery and after plication are shown in Fig. 1. Although forced vital capacity (VC) and %VC were significantly lower after plication than that before cardiac surgery, forced expiratory volume in one second ($FEV_{1.0}$) and % of $FEV_{1.0}$ of forced VC ($FEV_{1.0\%}$) after plication returned to preoperative levels. The pressure of oxygen in blood (PaO_2) and the pressure of carbon dioxide in blood ($PaCO_2$) were not significantly different comparing their values before cardiac surgery and after plication, respectively. Figure 2 shows the change in the chest x-ray image after bilateral DP in one patient (case 1). There was a remarkable bilateral elevation in the diaphragm 24 days after cardiac surgery (Fig. 2B). Although the right diaphragm was markedly pulled down just after diaphragmatic plication (53 days after cardiac surgery) (Fig. 2C), it returned to a satisfactory position at discharge from the hospital (81 days after cardiac surgery). Furthermore, the left diaphragm also moved to a good position because of strong traction to the right side. Presently, one year after surgery, this patient continues to do well (Fig. 2D). The improvement of the bilateral diaphragm movement has been confirmed by fluoroscopy in this patient. The other two patients also continue to do well and are without symptoms.

Discussion

The diaphragm is the major muscle involved in ventilation. There are many reports[1-5] concerning DP because of phrenic nerve injury in children. Especially in infants, DP often leads to a delay or prevention of weaning from mechanical ventilation and is obviously deleterious. Conversely, because respiration in adults is not as totally dependent on diaphragmatic breathing, the difficulty is not as notable as in children. In normal adults, diaphragmatic excursion may contribute 30% to 60% of total tidal volume. With unilateral DP, there is a decrease of 20% to 30% of VC and maximum voluntary ventilation, and a 20% decrease in oxygen uptake on the involved side.[15] Consequently, even if adult patients undergo DP, they can generally be weaned from mechanical ventilation because of the compensation of the intercostal muscles or the res-

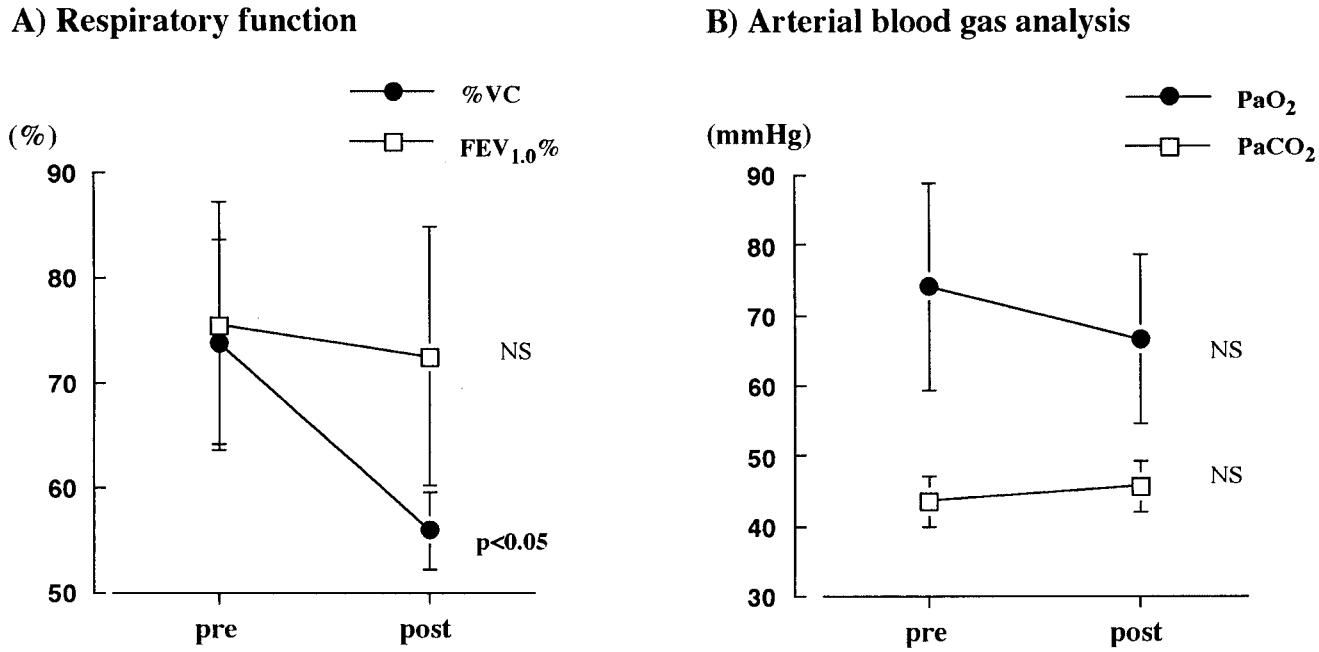

Fig. 1. Comparison of respiratory function (A) and arterial blood gas analysis (B) before cardiac surgery vs after diaphragmatic plication. Pre, pre cardiac surgery (at the admission); post, post diaphragmatic plication. Percentage of $FEV_{1.0}$ of forced VC ($FEV_{1.0\%}$) after plication returned to preoperative levels. The pressure of oxygen in blood (PaO_2) and the pressure of carbon dioxide in blood ($PaCO_2$) were not significantly different comparing their values before cardiac surgery and after plication.

piratory support muscles. The incidence of DP in adult patients after cardiac surgery has been increased and the main cause of this is attributed to topical cooling.[6-8,10,11,16] Other causes were cutting, detrition, traction and thermal burn from the electric knife. Some reports have explained the relationship of the use of ITA and postoperative phrenic nerve dysfunction in the patients with CABG.[6-8,12] The phrenic nerve crosses the ITA in many places. The bilateral phrenic nerves cross the ITAs anteriorly (chest wall side) in 54% of cases and posteriorly in 14%.[17] The pericardiacophrenic artery originated from the ITA in 89% of cases examined.[17] If the pericardiacophrenic artery was injured without direct injury of the phrenic nerve, the DP should be performed for the ischemia of phrenic nerve. In the patients with bilateral DP in this study, although the phrenic nerve was confirmed to cross the ITA anteriorly, and was preserved clearly during surgery, bilateral DP was performed. There was a possibility that the phrenic nerve ischemia was due to injury of the pericardiacophrenic artery and not due to direct injury. The incidence of phrenic nerve dysfunction after CABG ranged from 10% to 60%.[6,7,9-13] Although DP after cardiac surgery was not uncommon, many researchers have noted that this was transient and of no clinical significance.[1,9,13] Phrenic nerve regeneration is estimated at a rate of 1 mm/day.[12] Cohen et al. noted that phrenic nerve recovery occurs at least partially in 75% to 90% of patients with such an injury.[8] However, there were some adult patients who needed continuous ventilatory support, or were severely limited in activity after DP. We have experienced many patients who have no symptoms and are able to be weaned from mechanical ventilation easily, although left DP was suspected postoperatively. All four patients in this study had right DP and one had bilateral DP. The DP was considered a significant cause of postoperative respiratory dysfunction because hyperventilation and respiratory difficulties occurred due to progression of the atelectasis of the right lung resulting from elevation of the right diaphragm.

DP is usually suspected when diaphragmatic elevation is seen on the chest x-rays. However, in the postoperative patient in the supine position and on ventilatory support, DP may not be easily detected because positive-pressure ventilation tends to mask abnormal findings. Furthermore, in the spontaneously breathing patients, left pleural effusion, lower lobe atelectasis, and elevation of the left hemidiaphragm are, unfortunately, common sequelae of cardiac surgery and mask phrenic nerve injury.[18] Previous studies have shown that in patients undergoing CABG, the $FEV_{1.0}$ is reduced to two thirds of its previous value.[19-21]

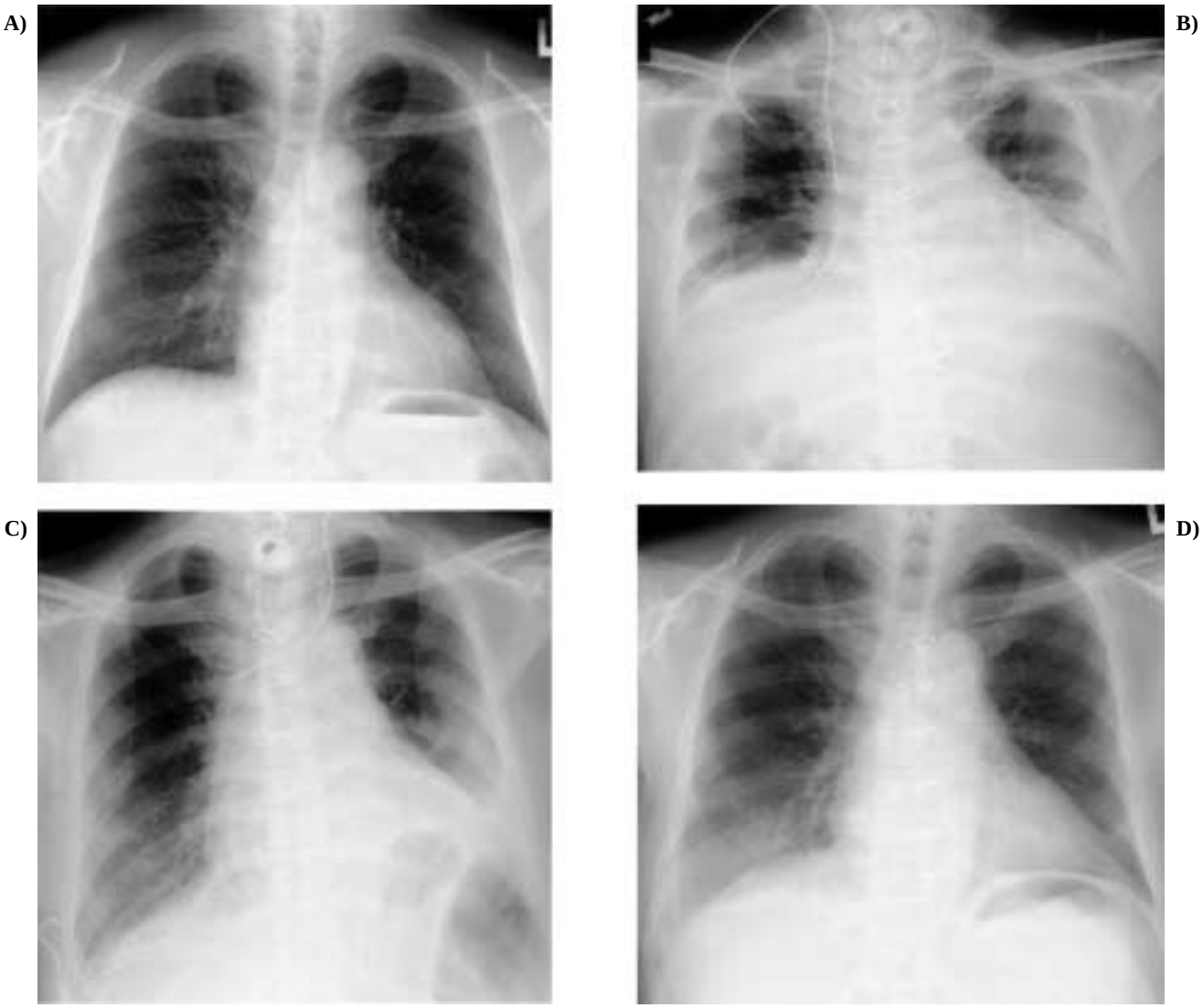

Fig. 2. Change in the chest x-ray image of case 1. A) pre-cardiac surgery, B) 24 days after cardiac surgery, C) just after diaphragmatic plication (53 days after cardiac surgery), D) one year after surgery.

Therefore, hypoxemia may be expected to occur after cardiac surgery. DP is confirmed by esophageal and gastric pressure measurements, fluoroscopy, ultrasonography and electroneuromyography. In the latter procedure, an electrical stimulus is applied over the phrenic nerve in the neck and a diaphragmatic electromyogram from the seventh and the eighth intercostal spaces is displayed on a storage oscilloscope.[8,12,16,17] In our patients the recovery from ventilatory support was difficult, and the tidal volume was insufficient (mean, 216±40.1 ml). Even though efforts were made to prevent or minimize the effects of the influence of consciousness disorder, threatening, wound pain, and infection, spontaneous respiration was not achieved. Although we made efforts to suction the sputum after the tracheostomy and prescribed enteral nutrition or total parenteral nutrition for the improvement of nourishment, hyperventilation, aterectasis, pneumonia, continuous respiratory distress and CO_2 retention worsened when spontaneous respiration resumed. Paradoxical movement of the affected diaphragm and deviation of the mediastinum were confirmed by fluoroscopy and ultrasonography. Electroneuromyography was performed in three of four patients and was useful as a decision-making tool in the indication of diaphragmatic plication because it was negative at the affected side in all three patients. However, this was difficult to judge because both sides were negative in the patient with bilateral DP. Consequently, we propose that the diagnosis of

DP should be made on the basis of the results of multiple examinations including the symptoms.

The aim of diaphragmatic plication is to decrease lung compression, stabilize the thoracic cage and mediastinum, and strengthen the respiratory action of intercostal and abdominal muscles. More effective recovery of the diaphragm is likely by increasing the diaphragm strength and maximal voluntary ventilation.[1] It is noteworthy that the beneficial effect of diaphragmatic plication does not interfere with the return of normal diaphragm function which may occur spontaneously within 18 months.[1] Many reports have shown that in children unilateral diaphragmatic plication improves the diseased condition of the DP and makes it possible to recover quickly from ventilatory support.[1-5,15] It was concluded that early diaphragmatic plication in properly selected ventilated infants with DP offers immediate benefits and excellent results and prevents the complication of prolonged mechanical ventilation. Although the effectiveness of plication is not clear, satisfactory results of the diaphragmatic plication after phrenic nerve injury caused by cardiac surgery or lobectomy of the lung in the adults were found in some cases.[1,3,22,23] Wright et al. reported that PaO_2 and all lung volumes except residual volume were significantly increased after diaphragmatic plication in seven adult patients with dyspnea resulting from unilateral DP.[22] They concluded that plication is a safe and effective procedure for adult patients. Ribet and Linder also reported good results in 11 adult patients who were followed up for a mean period of 8.5 years after plication.[3] Although chronic symptoms such as respiratory distress and breathlessness are indications for plication, it has been suggested that the good results obtained with children relative to weaning from mechanical ventilator may not be applicable to adults.[1,3] We also tried other approaches such as treating the symptoms including exclusion of the dead space and suction of the sputum through tracheostomy and improvement of nutritional state as much as possible. However, as the respiratory dysfunction did not improve, the plication was performed 46±11.9 days after cardiac surgery (28±5.6 days after tracheostomy) to avoid the complications of prolonged mechanical ventilation. Right diaphragmatic plication was performed in all patients and all patients could be weaned from mechanical ventilation 7.8±4.3 days after plication in our study. There was a dramatic improvement in the tidal volume increasing to 415±29.6 ml. Unfortunately, one patient died from aspiration pneumonia 15 days after plication, although he also was weaned from mechanical ventilation five days after the surgery. The other three patients recovered from oxygen therapy at 17.3±2.5 days and were discharged 38.3±14.1 days after plication. Although VC and %VC were lower after plication than before cardiac surgery, the improvement of $FEV_{1.0}$ and $FEV_{1.0\%}$ after plication were satisfactory. In this study the reasons for obtaining satisfactory results from diaphragmatic plication performed for the purpose of recovery from ventilatory support may be that the cause of the decreasing of tidal volume was right DP (bilateral in one), in which the right lung was compressed. Moreover, the muscle sparing procedure was likely to have been useful for decreasing the pain during respiration just after surgery and the preservation of respiratory support muscles.

At present, all three patients continue to do well without respiratory difficulties and have a mean follow-up of 14.7±5.6 months after surgery. Although satisfactory results were obtained in our study for plication, the clinician must be very careful before recommending plication for respiratory or digestive symptoms thought to be related to elevation of the diaphragm because the indication for this type of surgery in adults is uncommon.[3] Although the respiratory difficulties ceased just after surgery, the chest compression during deep breathing remained for about six months after surgery. It was possible that the diaphragmatic fixing due to excessive plication may have limited the movement of the thoracic cage and the mediastinum. Nonetheless, the diaphragmatic plication appears to be satisfactory and effective in the improvement of chronic respiratory difficulties and weaning from mechanical ventilation in properly selected adult patients. However, as plication is a symptomatic treatment, it is most important that steps should be taken to prevent the occurrence of the DP. When ITA grafts are used, excessive movement of the artery should be avoided to prevent ischemic or proximity injury to the phrenic nerve. Previously, the ITA was mobilized away from the chest wall within its pedicle placed distal to the fifth intercostal space and proximally to the subclavian vein. We harvested ITA on full-skeletonization to avoid excessive movement of the artery after 2001. Fortunately, DP after cardiac surgery did not occur thereafter.

Conclusion

Diaphragmatic plication was performed in four adult patients with respiratory dysfunction due to paralysis of the diaphragm after cardiac surgery. The respiratory dysfunction was improved postoperatively in all four patients and

they could be weaned from mechanical ventilation. Diaphragmatic plication is a useful procedure for treatment of diaphragm paralysis in adults.

References

1. Simansky DA, Paley M, Refaely Y, Yellin A. Diaphragm plication following phrenic nerve injury: a comparison of paediatric and adult patients. *Thorax* 2002; **57**: 613–6.
2. Schwartz MZ, Filler RM. Plication of the diaphragm for symptomatic phrenic nerve paralysis. *J Pediatr Surg* 1978; **13**: 259–63.
3. Ribet M, Linder JL. Plication of the diaphragm for unilateral elevation or paralysis. *Eur J Cardiothorac Surg* 1992; **6**: 357–60.
4. Yellin A, Lieberman Y, Barzilay Z. Postoperative unilateral diaphragmatic paralysis in children: a plea for early plication. *Thorac Cardiovasc Surg* 1991; **39**: 221–3.
5. van Onna IE, Metz R, Jekel L, Woolley SR, van de Wal HJ. Post cardiac surgery phrenic nerve palsy: value of plication and potential for recovery. *Eur J Cardiothorac Surg* 1998; **14**: 179–84.
6. Tripp HF, Major DWS, Lisagor PG, Cohen DJ. Is phrenic nerve dysfunction after cardiac surgery related to internal mammary harvesting? *J Card Surg* 2001; **16**: 228–31.
7. Curtis JJ, Nawarawong W, Walls JT, et al. Elevated hemidiaphragm after cardiac operations: incidence, prognosis, and relationship to the use of topical ice slush. *Ann Thorac Surg* 1989; **48**: 764–8.
8. Cohen AJ, Katz MG, Katz R, Mayerfeld D, Hauptman E, Schachner A. Phrenic nerve injury after coronary artery grafting: is it always benign? *Ann Thorac Surg* 1997; **64**: 148–53.
9. Esposito RA, Spencer FC. The effect of pericardial insulation on hypothermic phrenic nerve injury during open-heart surgery. *Ann Thorac Surg* 1987; **43**: 303–8.
10. Maccherini M, Davoli G, Sani G, et al. Warm heart surgery eliminates diaphragmatic paralysis. *J Card Surg* 1995; **10**: 257–61.
11. Efthiminou J, Butler J, Woodham C, Benson MK, Westaby S. Diaphragm paralysis following cardiac surgery: role of phrenic nerve cold injury. *Ann Thorac Surg* 1991; **52**: 1005–8.
12. O'Brien JW, Johnson SH, VanSteyn SJ, et al. Effects of internal mammary artery dissection on phrenic nerve perfusion and function. *Ann Thorac Surg* 1991; **52**: 182–8.
13. Wilcox PG, Pare PD, Pardy RL. Recovery after unilateral phrenic injury associated with coronary artery revascularization. *Chest* 1990; **98**: 661–6.
14. Bethencourt DM, Holmes EC. Muscle-sparing posterolateral thoracotomy. *Ann Thorac Surg* 1988; **45**: 337–9.
15. Zhao HX, D'Agostino RS, Pitlick PT, Shumway NE, Miller DC. Phrenic nerve injury complicating closed cardiovascular surgical procedures for congenital heart disease. *Ann Thorac Surg* 1985; **39**: 445–9.
16. Diehl JL, Lofaso F, Deleuze P, Similowski T, Lemaire F, Brochard L. Clinically relevant diaphragmatic dysfunction after cardiac operations. *J Thorac Cardiovasc Surg* 1994; **107**: 487–98.
17. Henriquez-Pino JA, Gomes WJ, Prates JC, Buffolo E. Surgical anatomy of the internal thoracic artery. *Ann Thorac Surg* 1997; **64**: 1041–5.
18. Russel RI, Mulvey D, Laroche C, Shinebourne EA, Green M. Bedside assessment of phrenic nerve function in infants and children. *J Thorac Cardiovasc Surg* 1991; **101**: 143–7.
19. Cain HD, Stevens PM, Adaniya R. Preoperative pulmonary function and complications after cardiovascular surgery. *Chest* 1979; **76**: 130–5.
20. Cohen AJ, Moore P, Jones C, et al. Effect of internal mammary harvest on postoperative pain and pulmonary function. *Ann Thorac Surg* 1993; **56**: 1107–9.
21. Jackson CV. Preoperative pulmonary function evaluation. *Arch Intern Med* 1988; **148**: 2120–7.
22. Wright CD, Williams JG, Ogilvie CM, Donnelly RJ. Results of diaphragmatic plication for unilateral diaphragmatic paralysis. *J Thorac Cardiovasc Surg* 1985; **90**: 195–8.
23. Glassman LR, Spencer FC, Beumann FG, Adams FV, Colvin SB. Successful plication for postoperative diaphragmatic paralysis in an adult. *Ann Thorac Surg* 1994; **58**: 1754–5.