Case Report

Active Distal Coronary Perfusion to Prevent Regional Myocardial Ischemia in Off-pump Coronary Artery Bypass Grafting

Hankei Shin, MD,[1] Kiyoshi Koizumi, MD,[1] Toru Matayoshi, CCP,[2] and Ryohei Yozu, MD[1]

Regional myocardial ischemia during anastomosis in off-pump coronary artery bypass (OPCAB) can occasionally cause hemodynamic instability. To prevent regional myocardial ischemia and stabilize the hemodynamics during the procedure, perfusion of the distal coronary artery to the anastomotic site is necessary as the only reliable method. We have applied an active coronary perfusion method using a servo-controlled pump in selected patients in place of conventional passive perfusion methods (intraluminal shunt and external shunt). We present a case in which the active perfusion method proved useful in avoiding regional myocardial ischemia. A 74-year-old male patient with triple-vessel coronary disease underwent OPCAB for unstable angina. During revascularization of the main right coronary artery, the hemodynamics collapsed due to regional myocardial ischemia. As soon as the distal coronary artery was perfused at a high flow rate around 80 ml/min, the hemodynamics stabilized and the operation was completed successfully. This active coronary perfusion method in OPCAB is particularly useful in cases in which regional myocardial ischemia cause hemodynamic instability. (Ann Thorac Cardiovasc Surg 2004; 10: 198–201)

Key words: off-pump coronary artery bypass (OPCAB), active distal coronary perfusion, servo-controlled pump

Introduction

With the development of suction-type mechanical stabilizers and positioners, off-pump coronary artery bypass (OPCAB) is increasing in popularity. Currently the procedure is indicated even for patients with multivessel coronary artery disease or poor ventricular function.[1-3] For successful OPCAB in these cases it is important to avoid regional myocardial ischemia during coronary artery occlusion, which can cause hemodynamic deterioration.[4] Perfusion of the distal coronary artery to the anastomotic site is the only reliable way to prevent regional myocardial ischemia. For this purpose we have adopted an active coronary perfusion method. We present here a case in which the active distal coronary perfusion method proved highly effective against regional myocardial ischemia in OPCAB.

From [1]Division of Cardiovascular Surgery, Department of Surgery, and [2]Medical Engineering Center, Keio University School of Medicine, Tokyo, Japan

Received March 31, 2003; accepted for publication January 8, 2004.
Address reprint requests to Hankei Shin, MD: Division of Cardiovascular Surgery, Keio University School of Medicine, 35 Shinanomachi, Shinjuku-ku, Tokyo 160-8582, Japan.

Technique of Active Distal Coronary Perfusion

A target coronary artery was exposed, and a pair of sutures were passed around the target coronary artery proximally and distally to the anastomotic site. The proximal suture is used for coronary occlusion, and the distal suture for snaring around a coronary perfusion cannula. A servo-controlled pump (MPS, Myocardial Protection System, Quest Medical, Inc., Allen, TX, USA) was used to perfuse arterial blood actively into the distal coronary artery (Fig. 1). A 10 Fr cannula was inserted percutaneously into the femoral artery for inflow of the pump circuit, and a coronary perfusion cannula (Coronary perfusion catheter, Sumitomo Bakelite Co., Ltd., Tokyo, Japan, or Elongated arteriotomy cannula, Medtronic DLP,

Fig. 1. Servo-controlled pump used for active distal coronary perfusion during coronary occlusion in off-pump coronary artery bypass.

Fig. 2. Intraoperative findings. A coronary perfusion cannula connected for outflow of the perfusion circuit is being inserted into the distal left anterior descending artery. The perfusion pressure is monitored directly.

Grand Rapids, MI, USA) was connected for outflow (Fig. 2). This MPS pump monitors the delivery line pressure and the delivery flow rate. We also monitored and displayed the perfusion pressure of the coronary perfusion cannula. The pump is servo-controlled and has a mode that maintains a desired perfusion pressure. Since the pressure is constant, the delivery flow becomes predominantly diastolic. The pump incorporates a chamber which usually contains isosorbide nitrate solution, so that intracoronary medication delivery is possible. A heat exchanger is also incorporated, and it is possible to keep the delivered blood temperature constant. We maintain the delivery blood temperature at 38°C.

Case Report

A 74-year-old male patient was admitted to our hospital for surgery for unstable angina. Anginal pain was due to proximal 99% stenosis of the large right coronary artery (RCA). The left anterior descending artery (LAD) was totally blocked and the left circumflex artery (LCx) was 75% stenotic. OPCAB was performed for revascularization of the three coronary arteries. The chest was opened through a median sternotomy. Heparin was given, and the activated clotting time was kept above 400 seconds. The RCA was bypassed first with the right internal thoracic artery. A pair of elastic sutures was passed round the main RCA, proximally and distally to the anastomotic site. The heart was stabilized mechanically with a suction type stabilizer (Octopus 3, Medtronic, Inc., Minneapolis, MN, USA). Remarkable elevation of the ST-segment was observed on the monitor immediately after the RCA was occluded, and distal active coronary perfusion was immediately started. The initial perfusion pressure was 60 mmHg, with a delivery flow rate around 20 ml/min; the ST-segment did not subside and the systemic arterial pressure continued to decline. We therefore suspected that a greater delivery flow was necessary to improve the myocardial ischemia, and we increased the flow rate to around 80 ml/min; the required perfusion pressure proved to be 120 mmHg. Soon after this increase in flow rate, the ST-segment returned to the baseline and systemic arterial pressure stabilized (Fig. 3). The perfusion pressure was then maintained at 80 mmHg (corresponding to a delivery flow rate around 40 ml/min), and the anastomosis was completed with no myocardial ischemic changes. Next, the LAD was grafted with the left internal thoracic artery, with the assistance of active coronary perfusion at approximately 80 mmHg. Finally, a saphenous vein graft was placed onto the obtuse marginal branch of the LCx, and the proximal end was anastomosed to the aorta.

The creatine kinase-MB value on the first postoperative day was 10 IU/L, and the postoperative course was uneventful. Prior to discharge from the hospital, coronary angiography showed that all grafts were widely patent.

Discussion

Major issues when the OPCAB procedure was revived were how to obtain good visualization of target vessels, and how to prevent regional cardiac motion. Suction-type

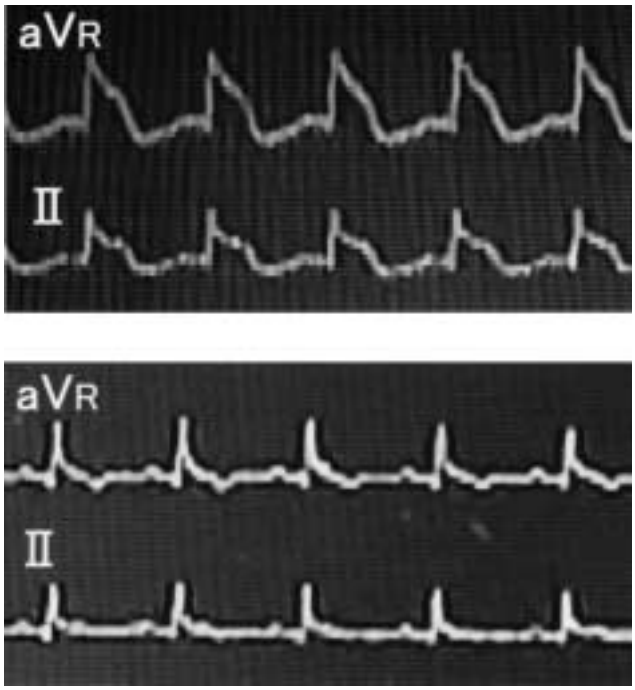

Fig. 3. Monitoring of electrocardiography during the anastomosis, showing remarkable elevation of the ST-segment due to coronary occlusion (above) and return to the baseline following active distal coronary perfusion at a high flow rate (below).

stabilizers allowed effective immobilization of the anastomotic site. Suction-type heart positioners have recently been developed that allow the posterolateral or inferior part of the heart to be exposed without compressing the heart.[5] Given good visualization and stabilization, further issues are how to maintain cardiac function during the procedure and how to protect the myocardium, since OPCAB has been indicated for patients with multivessel disease or cardiac dysfunction.[1-3] Myocardial ischemia due to coronary occlusion during the anastomosis may lead to hemodynamic collapse.[4] As in the present case, occlusion of the main RCA frequently causes abrupt hemodynamic deterioration and bradycardiac arrhythmias such as atrioventricular block. When a large coronary artery that supplies collateral blood flow to other blocked arteries is occluded, the heart may be intolerant to myocardial ischemia. If the hemodynamics becomes unstable during the procedure as a result of myocardial ischemia, the surgeon must work quickly or revise the operative strategy in real time, tending to cause poor quality anastomoses or incomplete revascularization. Perfusion of the coronary artery distal to the anastomotic site then becomes a reliable method.

Distal coronary perfusion using an intraluminal cannula or external shunt catheter is now used to prevent myocardial ischemia and to maintain cardiac function during the procedure.[6-10] Here, both shunts depend on passive flow. When there is severe stenosis at the proximal site of the coronary artery, the blood flow through the intraluminal shunt cannula may be inadequate. In an external shunt with a relatively long catheter, the shunt flow may be restricted. Whatever type of shunt is applied, the arterial pressure remains the driving force for the shunt flow. Displacement of the heart due to exposure of a target vessel may cause hypotension. Once the systemic arterial pressure drops–especially the diastolic pressure–the shunt flow decreases and becomes inadequate. This may then cause myocardial dysfunction and further systemic hypotension, resulting in a downward spiral of the hemodynamics.

Although the simpler flow delivery methods currently available usually overcome the ischemic problems arising due to coronary occlusion in OPCAB, active perfusion into the distal coronary artery has great advantage over passive perfusion. Muraki and associates found experimentally that an intraluminal shunt caused regional myocardial ischemia during systemic hypotension, but that active coronary perfusion with the same servo-controlled pump used here provided adequate oxygen supply whatever the systemic blood pressure.[11] Kamiya and associates developed an active coronary perfusion system for OPCAB and found experimentally that active coronary perfusion during coronary occlusion helped prevent myocardial ischemia.[12] Vassiliades and colleagues used the same servo-controlled pump as here for active coronary perfusion in a clinical setting, and confirmed its superiority in myocardial protection and performance during OPCAB.[13] Though it is not always easy to determine which coronary arteries should be perfused actively instead of passively, we believe that active perfusion of the main RCA and large LAD is beneficial, particularly when these supply collateral blood flow to other coronary arteries. We have performed active coronary perfusion with the servo pump in 16 cases and consistently find that the pump provides precise control of distal coronary perfusion without direct influence on the systemic hemodynamics.

The present case shows that coronary occlusion during OPCAB can cause abrupt hemodynamic deterioration due to regional myocardial ischemia. The active coronary perfusion system described here is a useful system for achieving sufficient distal coronary perfusion to prevent regional myocardial ischemia.

References

1. Meharwal ZS, Mishra YK, Kohli V, Bapna R, Singh S, Trehan N. Off-pump multivessel coronary artery surgery in high-risk patients. *Ann Thorac Surg* 2002; **74**: S1353–7.
2. Shennib H, Endo M, Benhamed O, Morin JF. Surgical revascularization in patients with poor left ventricular function: on- or off-pump?. *Ann Thorac Surg* 2002; **74**: S1344–7.
3. D'Ancona G, Karamanoukian H, Kawaguchi AT, Ricci M, Salerno TA, Bergsland J. Myocardial revascularization of the beating heart in high-risk patients. *J Card Surg* 2001; **16**: 132–9.
4. Vassiliades TA Jr, Nielsen JL, Lonquist JL. Hemodynamic collapse during off-pump coronary artery bypass grafting. *Ann Thorac Surg* 2001; **73**: 1874–9.
5. Niinami H, Takeuchi Y, Ichikawa S, et al. Multivessel off-pump coronary aortic bypass grafting with an impaired and severely dilated left ventricle using the Starfish heart positioner. *Kyobu Geka* 2002; **55**: 773–7. (in Japanese)
6. Lucchetti V, Capasso F, Caputo M, et al. Intracoronary shunt prevents left ventricular function impairment during beating heart coronary revascularization. *Eur J Cardiothorac Surg* 1999; **15**: 255–9.
7. Yeatman M, Caputo M, Narayan P, et al. Intracoronary shunts reduce transient intraoperative myocardial dysfunction during off-pump coronary operations. *Ann Thorac Surg* 2002; **73**: 1411–7.
8. Menon AK, Albes JM, Oberhoff M, Karsch KR, Ziemer G. Occlusion versus shunting during MIDCAB: effects on left ventricular function and quality of anastomosis. *Ann Thorac Surg* 2002; **73**: 1418–23.
9. Borges MF, Spohn PK, Coulson AS. Arrhythmia/ischemia management during minimally invasive cardiac operation. *Ann Thorac Surg* 1997; **64**: 843–4.
10. Arai H, Yoshida T, Izumi H, Sunamori M. External shunt for off-pump coronary artery bypass grafting: distal coronary perfusion catheter. *Ann Thorac Surg* 2000; **70**: 681–2.
11. Muraki S, Morris CD, Budde JM, et al. Preserved myocardial blood flow and oxygen supply-demand balance with active coronary perfusion during simulated off-pump coronary artery bypass grafting. *J Thorac Cardiovasc Surg* 2002; **123**: 53–62.
12. Kamiya H, Watanabe G, Doi T, et al. Coronary active perfusion system can maintain myocardial blood flow and tissue oxygenation. *Eur J Cardiothorac Surg* 2002; **22**: 410–4.
13. Vassiliades TA Jr, Nielsen JL, Lonquist JL. Coronary perfusion methods during off-pump coronary artery bypass: results of a randomized clinical trial. *Ann Thorac Surg* 2002; **74**: S1383–9.