Original Article

Surgical Treatment of Lung Cancer with Vertebral Invasion

Kiyoshi Koizumi, MD, Shuji Haraguchi, MD, Tomomi Hirata, MD, Kyoji Hirai, MD, Iwao Mikami, MD, Shigeki Yamagishi, MD, Daisuke Okada, MD, Hiroyasu Kinoshita, MD, Yutaka Enomoto, MD, Yuki Nakajima, MD, and Kazuo Shimizu, MD, FACS

Vertebral body invasion by lung cancer has been problematic due to uncertainty regarding a clear surgical resection margin. Therefore, additional chemoradiotherapy has been performed to assist clearance of the surgical margin. We reviewed our experience of surgical treatment for lung cancer patients with vertebral invasion. Between 1982 and 2003, 1,070 patients underwent lung cancer surgery at the Nippon Medical School Hospital. Eight patients (0.74%) of this group underwent a combined vertebral body and chemoradiotherapy. Seven lobectomies and one pneumonectomy with mediastinal lymphadenectomy were performed. All patients underwent partial vertebrectomy. The percentage with vertebral tumor involvement was 15%. A defect of vertebral cortical bone was reinforced with implantation of rib in one patient. There was no postoperative mortality. Postoperative complications were pneumonia and arrhythmia. The median follow-up period was 19 months (range from 4 to 69.7 months). The overall actuarial survivals at 1-year, 3-year and 5-year were 68.6%, 22.9% and 22.9%. Local recurrence occurred in three patients and distant metastasis was evident in five. Even though the number of patients was small, partial vertebrectomy with chemoradiotherapy offer reduction of severe pain and an improved prognosis. However, a patient with further progressive disease should be treated with a multidisciplinary approach. (Ann Thorac Cardiovasc Surg 2004; 10: 229–34)

Key words: lung cancer, superior sulcus tumor, vertebral invasion, vertebrectomy

Introduction

Surgical treatment of lung cancer with direct invasion to the vertebral body and surrounding tissue has been problematic due to local regional recurrence with a poor prognosis, particularly in patients with superior sulcus tumors.[1-4] Ginsberg et al.[4] emphasized that a complete resection must be carried out to achieve long-term survival in patients with vertebral column invasion. Vertebrectomy followed by reconstruction and a multidisciplinary approach was reported to offer an improved prognosis.[5-11] Although a multidisciplinary approach may be needed to control surgical margin, the thoracic surgeon must decide if total vertebrectomy should be done if direct invasion involves 30% or less of vertebral cortical bone. According to prior studies, preoperative and postoperative concurrent chemoradiotherapy has been recommended to avoid local recurrence.[12-17] We have treated lung cancer with 30% or less of vertebral column invasion with preoperative and/or postoperative chemoradiotherapy. We report clinical outcomes of patients who underwent surgical treatment of lung cancer with invasion to the thoracic vertebrae.

From Division of Thoracic Surgery, Department of Surgery II, Nippon Medical School, Tokyo, Japan

Received February 5, 2004; accepted for publication March 12, 2004.
Address reprint requests to Kiyoshi Koizumi, MD: Division of Thoracic Surgery, Department of Surgery II, Nippon Medical School, 1-1-5 Sendagi, Bunkyo-ku, Tokyo 113-8603, Japan.

Material and Methods

Between July 1982 and July 2003, 1,070 patients underwent surgical treatment for primary lung caner at Nippon Medical School Hospital. One hundred and ninety-one

Table 1. Characteristics of lung cancer patients who underwent combined resection of thoracic vertebral column

Case	Age (year)	Gender	Histology	p-TNM	Size (mm)	Involved ribs and vertebrae	Chemotherapy	Radiotherapy	Radiation (Ef)
1	61	Male	Sq	t4n1m0	60	1st, 2nd, 3rd rib 2nd, 3rd, 4th vertebral body	Post	Pre and Post 20 Gy and 40 Gy	0
2	52	Male	Ad	t3n2m0	50	1st, 2nd, 3rd rib 1st, 2nd vertebral body	Post	Pre and Post 30 Gy and 40 Gy	1
3	46	Male	Sq	t4n0m0	60	1st, 2nd, 3rd rib 2nd, 3rd, 4th vertebral body	Post	Post 60 Gy	None
4	48	Male	Ad	t4n3m0	100	1st, 2nd rib 1st, 2nd vertebral body	Pre and Post	Pre 68 Gy	1
5	54	Male	Ad	t4n2m0	60	1st, 2nd, 3rd, 4th rib 1st, 2nd vertebral body	Post	Post 60 Gy	None
6	70	Male	Ad	t4n2m0	80	1st, 2nd rib 1st, 2nd vertebral body	Post	Pre and Post 32 Gy and 30 Gy	2
7	55	Male	Sq	t4n0m0	90	1st, 2nd, 3rd, 4th rib 1st, 2nd, 3rd vertebral body	Post	Pre and Post 40 Gy + 30 Gy	3
8	73	Male	Ad	t3n2m0	60	2nd, 3rd, 4th rib 2nd, 3rd, 4th vertebral body	None	Pre 30 Gy	2

Sq, squamous cell carcinoma; Ad, adenocarcinoma.

patients (17.9%) underwent combined resection of adjacent organs included eight partial vertebrectomy (0.74%) between 1988 and 2003 (Table 1). Preoperative conditions reviewed were age, gender, symptoms, and smoking index. Tumor location, size and spread of tumor was evaluated by chest roentgenogram, chest computed tomography (CT) scan and magnetic resonance imaging, and if necessary, angiography. Histological diagnosis was obtained by trans-bronchial lung biopsy or CT guided needle lung biopsy. Vertebral invasion was confirmed at surgery and postoperative pathological examination in all patients. The percentage of vertebra involvement with tumor was calculated by NIH image. Surgically related factors reviewed were duration of surgery, blood loss, and technical details. Preoperative radiation therapy was scheduled as a dose of 30 Gy for three weeks. CDDP+UFT were employed as a radiosensitizer in patients who underwent concurrent chemoradiotherapy. Postoperative radiotherapy was performed a few weeks after surgery. The patients studied were followed up at the out-patient clinic of the Division of Thoracic Surgery, Nippon Medical School Hospital. Survival curve was calculated by the Kaplan-Meier method.

Results

Eight patients underwent surgery for primary lung cancer with vertebral column invasion (Table 1). All patients were male with a median age of 57 years (range 46 to 73 years). There were adenocarcinoma (n=5) and squamous cell carcinoma (n=3). The average tumor size was 71 mm (range 50 to 100 mm). The clinical diagnosis of vertebral invasion (T4) was made on chest X-ray, chest CT scan, and magnetic resonance imaging. After surgery, pathological T factor was T3 in two patient and T4 in six patients. Pathological T3 shown in two patients revealed grade 1 and 3 of radiation effect (Ef). Vertebral invasion involved two vertebral bodies on average (range 1 to 3 vertebral bodies). Periosteal or neural foramina involvement was found in all patients. Two of eight patients were node negative (N0, n=2), but the remaining six were node positive (N1, n=1; N2, n=4; N3, n=1). All patients required medication for severe pain. Preoperative concomitant diseases were diabetes mellitus in another patient, brain infarction in another and postoperative status distant organ cancer in a third patient.

Adjuvant chemoradiotherapy

All patients underwent adjuvant therapy as shown in Table 1. Four patients underwent pre- and postoperative radiotherapy, two preoperatively, and two postoperatively. Six patients had postoperative concurrent chemotherapy and one patient underwent pre- and postoperative concurrent chemoradiotherapy. After resection of their radiated area, additional resection of the vertebral cortical bone was performed at least 5 mm in depth from the surface of initial surgical margin to achieve a clear surgical margin. Resected bone and surrounding tissue was saved for patho-

Surgery	Margins	Recurrence		Progonosis	Term months
		Local	Distant		
RUL	Negative		Present	Dead	69.7
RUL	Positive	Present	Present	Dead	21.4
LUL	Negative	None	None	Dead	10.7
LPn	Positive	Present	Present	Dead	4.9
LUL	Positive	Present	Present	Dead	21.7
RUL	Positive	Present	Present	Dead	4
RUL	Negative	None	None	Alive	16.1
RUL	Negative	None	None	Alive	7

logical examination as was the remnant of the tumor. Of the six patients undergoing preoperative radiation therapy, pathological examination revealed Ef 0 in one, Ef 1 in two, Ef 2 in two, and Ef 3 in one patient, postoperatively.

Surgery

Median duration of surgery and total amount of blood loss were 459 minutes (range 350 to 610 min) and 937 ml (range 200 to 1,800 ml), respectively. Of the eight patients undergoing pulmonary resection, one underwent pneumonectomy and seven underwent lobectomy (Table 1). The percentage of vertebral involvement with tumor was 15% on the average ranging from 5% to 25%. One patient had 30% of the vertebral body resected. The defect of vertebral cortical bone was reinforced with implantation of rib harvested from the chest wall (Fig. 1 and Fig. 2). Posterior-lateral-anterior thoracotomy (Hook skin incision) using Kent's retractor was employed in seven patients in order to mobilize the scapula, to obtain exposure, and to achieve a clear surgical margin. The intercostal space to enter the thorax was determined pre-operatively. The distal margins of the involved ribs occupied with tumor were cut at 3 cm inspected from the tumor. Subsequently, the pleural cavity was observed. Ribs involved with tumor were disarticulated from the transverse process and vertebral body. In five patients, transverse processes were resected. Resection of the vertebral cortical bone was continued until normal bone was encountered. In six patients who underwent preoperative radiotherapy, the radiated area changed to grayish and fragile fibrous tissues. In one patient, a transverse supraclavicular cervicotomy and upper half median sternotomy with anterior thoracotomy along the third intercostal space (Masaoka's cervico-sterno-thoracotomy)[18] was employed in order to perform a combined resection of the left subclavian artery, vein and the vertebral body.

Postoperative complications and prognosis

The major postoperative complication was pneumonia, occurring in cases 1 and 3. Local recurrence occurred in four patients and distant metastasis was in five. The median follow-up period was 19.1 months (range 4 to 69.7 months). Overall 1-year, 3-year, and 5-year actuarial survival were 68.6%, 22.9% and 22.9% (Fig. 3). The longest survivor was 61 year old male (case 1), with T4N1M0 of squamous cell carcinoma who died of pneumonia after chemotherapy for liver metastasis.

Discussion

Vertebral column invasion is reported to carry a poor prognosis. In patients with superior sulcus tumors invading the vertebral column, the 2-year survival rate with radiation therapy was reported to be no more than 15%.[19] DeMeester et al.[5] reviewed successful surgical treatment for patients with vertebral invasion who required en bloc resection of involved vertebra and surrounding tissue. However their patients did not suffer from cortical involvement of the vertebra. If tumor invasion breached the vertebral cortical bone, the prognosis would be poor.[1-4] These results have suggested that surgical treatment of superior sulcus tumor invading the vertebra will be controversial. In the present study, the patients were suffering from severe pain due to vertebral invasion breaching the vertebral cortex. Even though prognosis was poor, it is considered essential to manage severe pain. This concept is similar in patients with metastatic vertebral invasion.[8] Complete removal of vertebrae and multilevel laminectomy should be recommended, if tumor invasion extends to the spinal canal, transverse process, facet joints, or lamina.[7-9] Spaggiari et al.[20] raised a question about clinical outcomes in patients who underwent hemivertebrectomy for apical chest tumors. If 50% or more of vertebra was breached, total vertebrectomy would be required. Hemi- and total vertebrectomy was performed to achieve complete resection by several surgeons. They emphasized the necessity of complete resection to control local recurrence of vertebral invasion.[6-11] In contrast,

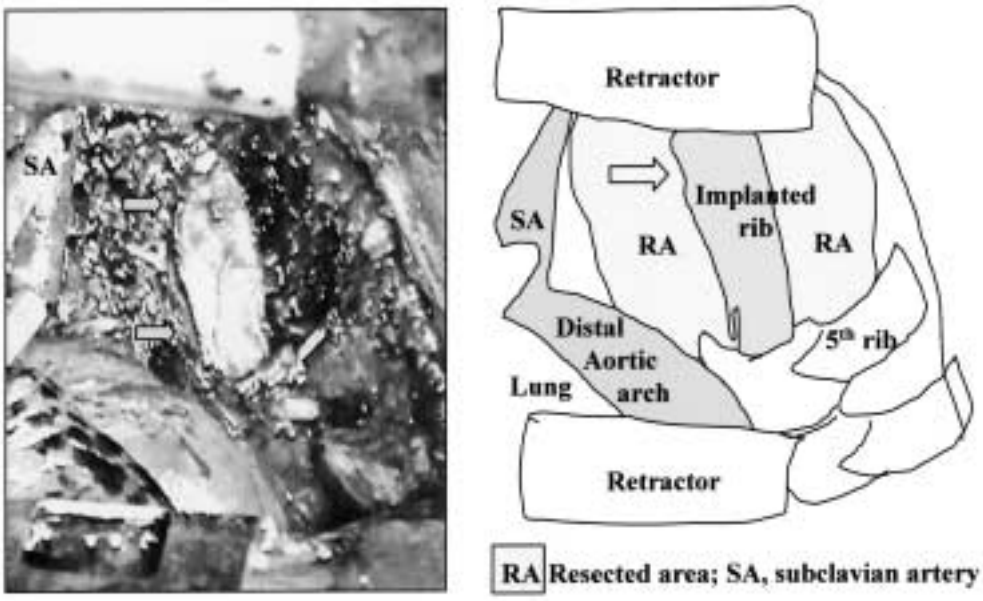

Fig. 1. The 2nd, 3rd and 4th thoracic vertebral bodies were partially resected and the defect was reinforced by a piece of rib harvested from the chest wall.
White arrow indicated the implanted piece of rib. DA, distal aortic arch; SA, left subclavian artery; Rib, the 5th rib; RA, area of combined resection.

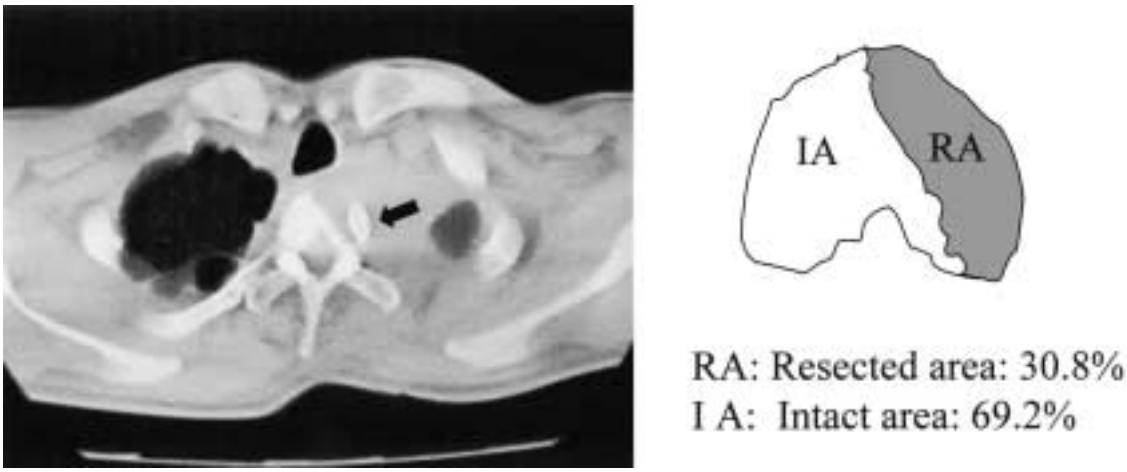

Fig. 2. Postoperative view of combined resection of the vertebral cortical bone.
Postoperative chest CT scan: After combined resection, the thoracic vertebral body was reinforced by implanted piece of rib. Black arrow indicates the implanted rib. Resected area was calculated using NIH image. RA, resected area; RI, intact area.

a vertebral body with less than 30% involvement may be treated with partial vertebrectomy. In this study, we report eight patients with vertebral invasion including vertebral cortical bone involvement. We employed a partial resection of the vertebra with cortical bone involvement with reinforcement of the vertebral body with rib. With partial resection, it is difficult to determine a clear surgical margin because rapid pathological examination is not feasible for bone materials. Therefore, we performed an additional removal of cortical bone from the margin considered to be safe during surgery. As a result, four of eight patients had achieved clear surgical margins. It has been suggested that in tumors with more than 10% vertebral involvement there is a possibility of not achieving clear

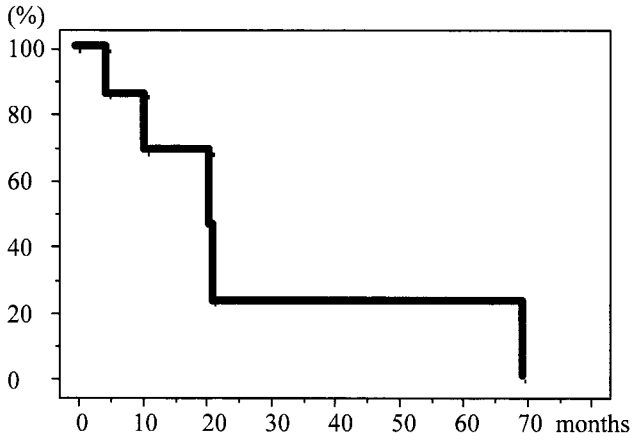

Fig. 3. Kaplan-Meier curve of all patients who underwent combined vertebral resection.
The median follow-up was 19.1 months on the average (range 4 to 69.7 months). Overall 1-year, 3-year, and 5-year actuarial survival were 68.6%, 22.9% and 22.9%. The longest survivor was a 61 year old male (case 1), with T4N1M0 of squamous cell carcinoma, who died of pneumonia after regular chemotherapy for liver metastasis.

margins in the surrounding bone.[9] Therefore, additional concurrent chemoradiotherapy was considered to be essential treatment. Komaki et al.[19] reported that there was no evidence of local regional recurrence in patients who underwent preoperative or postoperative radiation therapy. However preoperative and/or postoperative radiation therapy with concurrent chemotherapy has been reported to improve survival rate in patients who undergo surgery.[12-18] Rusch et al.[17] reported the effective of combined modality therapy to manage superior sulcus tumor regarding resectability and longevity of survival. In the present study, we found it easy to detect the margin of vertebral body involved and place the markers. Postoperative concurrent chemoradiotherapy is considered effective in controlling microscopic residual tumor.

Conclusion

We reported our experience in surgical treatment of lung cancer patients with vertebral invasion. For the patients with 30% or less invasion of the vertebral body, partial resection of vertebrae could be performed and clear margins could be achieved. However, the local recurrence rate is still high, and we considered it necessary to include preoperative and/or postoperative concurrent chemoradiotherapy to control tumor recurrence. Patients with further progressive disease should be treated with a multidisciplinary approach.

References

1. Anderson TM, Moy PM, Holmes EC. Factors affecting survival in superior sulcus tumors. *J Clin Oncol* 1986; **4**: 1598–603.
2. Maggi G, Casadio C, Pischedda F, et al. Combined radiosurgical treatment of Pancoast tumor. *Ann Thorac Surg* 1994; **57**: 198–202.
3. Sartori F, Rea F, Calabro F, et al. Carcinoma of the superior pulmonary sulcus. Results of irradiation and radical approach. *J Thorac Cardiovasc Surg* 1992; **104**: 679–83.
4. Ginsberg RJ, Martini N, Zaman M, et al. Influence of surgical resection and brachytherapy in the management of superior sulcus tumor. *Ann Thorac Surg* 1994; **57**: 1440–5.
5. DeMeester TR, Albertucci M, Dawson PJ, et al. Management of tumor adherent to the vertebral column. *J Thorac Cardiovasc Surg* 1989; **97**: 373–8.
6. Grunenwald D, Mazel C, Girard P, et al. Total vertebrectomy for en bloc resection of lung cancer invading the spine. *Ann Thorac Surg* 1996; **61**: 723–5.
7. Walsh GL, Gokaslan ZL, McCutcheon IE, et al. Anterior approaches to the thoracic spine in patients with cancer: indications and results. *Ann Thorac Surg* 1997; **64**: 1611–8.
8. Gokaslan ZL, York JE, Walsh GL, et al. Transthoracic vertebrectomy for metastatic spinal tumors. *J Neurosurg* 1998; **89**: 599–609.
9. Gandhi S, Walsh GL, Komaki R, et al. A multidisciplinary surgical approach to superior sulcus tumors with vertebral invasion. Ann Thorac Surg 1999; **68**: 1778-85.
10. Grunenwald DH, Mazel C, Girard P, et al. Radical en bloc resection for lung cancer invading the spine. *J Thorac Cardiovasc Surg* 2002; **123**: 271–9.
11. Mazel Ch, Grunenwald D, Laudrin P, et al. Radical excision in the management of thoracic and cervicothoracic tumors involving the spine: results in a series of 36 cases. *Spine* 2003; **28**: 782–92.
12. Shaw RR, Paulson DL, Kee JL. Treatment of the superior sulcus tumor by irradiation followed by resection. *Ann Surg* 1961; **154**: 29–40.
13. Devine JW, Mendenhall WM, Million RR, et al. Carcinoma of the superior pulmonary sulcus treated with

surgery and/or radiation therapy. *Cancer* 1986; **57**: 941–3.
14. Shahian DM, Neptune WB, Ellis FH Jr. Pancoast tumors: improved survival with preoperative and postoperative radiotherapy. *Ann Thorac Surg* 1987; **43**: 32–8.
15. Fuller DB, Chambers JS. Superior sulcus tumors: combined modality. *Ann Thorac Surg* 1994; **57**: 1133–9.
16. Rosell R, Gomez-Codina J, Camps C, et al. A randomized trial comparing preoperative chemotherapy plus surgery with surgery alone in patients with non-small-cell lung cancer. *N Engl J Med* 1994; **330**: 153–8.
17. Rusch VW, Giroux DJ, Kraut MJ, et al. Induction chemoradiation and surgical resection for non-small cell lung carcinomas of the superior sulcus: initial results of Southwest Oncology Group Trial 9416 (Intergroup Trial 0160). *J Thorac Cardiovasc Surg* 2001; **121**: 472–83.
18. Masaoka A, Ito Y, Yasumitsu T. Anterior approach for tumor of the superior sulcus. *J Thorac Cardiovasc Surg* 1979; **78**: 413–5
19. Komaki R, Mountain CF, Holbert JM, et al. Superior sulcus tumors: treatment selection and results for 85 patients without metastasis (Mo) at presentation. *Int J Radiat Oncol Biol Phys* 1990; **19**: 31–6.
20. Spaggiari L, Rusca M, Carbognani P, Solli P. Hemivertebrectomy for apical chest tumors: is the risk justified by the outcome? *Ann Thorac Surg* 1998; **65**: 1515–7.