

Ultrasonic Plaque Density of Aortic Atheroma and Stroke in Patients Undergoing On-pump Coronary Bypass Surgery

Hideaki Nohara, MD,¹ Tsutomu Shida, MD,² Nobuhiko Mukohara, MD,²
Hidefumi Obo, MD,² and Tetsuya Higami, MD³

Objective: The purpose of this study was to determine the relationship between the aortic atheromatous plaque echo density and the incidence of postoperative stroke or embolic events in patients undergoing on-pump coronary artery bypass grafting (CABG).

Patients and Methods: Three hundred and fourteen patients who received on-pump CABG alone were studied. Images of the aortic plaques obtained using transesophageal echocardiography were transferred to a computer. Using an image analysis program, a histogram for plaques more than 3 mm in thickness was obtained through the gray tone frequency distribution of the pixels (0-225). The gray scale median (GSM) was used as a measure of plaque echo density.

Results: Fifty-eight plaques in patients not associated with postoperative stroke or embolic events had GSM ranging from 58 to 241 (151.0 ± 38.2), while 9 plaques in patients associated with stroke or embolic events had GSM ranging from 67 to 130 (90.6 ± 21.3 , $p < 0.001$). The incidence of stroke or embolism was 58.3% when GSM of plaque was less than 100, while it was 3.6% when plaque GSM was more than 100 ($p < 0.001$).

Conclusion: This study indicated that computer analysis of aortic atheromatous plaque was useful for selecting patients who had a high risk of postoperative stroke or embolism when receiving on-pump CABG, and for decreasing the incidence of them. (*Ann Thorac Cardiovasc Surg* 2004; 10: 235-40)

Key words: on-pump coronary artery bypass grafting, postoperative stroke or embolism, aortic atheromatous plaque echo density

Introduction

The importance of the aorta as an embolic source has been emphasized in patients receiving coronary artery bypass grafting (CABG). In the last eight to 10 years, there have been many reports about perioperative stroke that is related to the atheromatous disease of the aorta,

and is evaluated using epiaortic or transesophageal echocardiography. The detailed high-resolution images of the atherosclerotic aortic wall can be obtained during operation by employing B-mode technique. To prevent emboli, many cardiac surgeons have investigated the presence of a diseased ascending aorta, and assessed aortic arch atheroma that is also a risk factor of embolism.

In many reports, a similar correlation between configuration or thickness of the atheromatous intima and perioperative embolic events is demonstrated, but neither morphological characteristics of atheromatous plaque or precise characteristics of the atheromatous plaque have been clarified yet. The purpose of this study was to determine the relationship between ultrasonic plaque density and immediate outcome after on-pump CABG, and to identify fragile aortic plaque that might cause embolic events.

From ¹Department of Surgery, Hyogo Prefectural Kaibara Hospital, Hyogo, ²Department of Cardiovascular Surgery, Hyogo Brain and Heart Center, Himeji, and ³First Department of Surgery, Shimane University School of Medicine, Shimane, Japan

Received September 9, 2003; accepted for publication April 19, 2004.

Address reprint requests to Hideaki Nohara, MD: Department of Surgery, Hyogo Prefectural Kaibara Hospital, 5208-1 Kaibara, Kaibara-cho, Hikami-gun, Hyogo 669-3395, Japan.

Table 1. Patient characteristics

The number of patients	314
Age (mean±SD)	64.8±9.8 years
Sex	246 males 68 females
Cardiac risk factors	The number of patients
Hypertension	126
Diabetes mellitus	112
Hyperlipidemia	63
Hemodialysis	6
Peripheral vascular disease	15
Previous CVA	28
Cerebrovascular diseases detected in preoperative MRA examination (more than 90% of stenosis)	142 (45.2%) 29 (20.4%)

CVA: cerebrovascular accident

MRA: magnetic resonance angiography

Patient Selection

Between January 1997 and December 1999, 426 patients undergoing isolated CABG for coronary artery diseases were studied retrospectively. Eighty-six patients who could not receive transesophageal echocardiography (TEE) for some reason and 26 patients who underwent off-pump CABG because of severe atherosclerotic or calcified findings of the ascending aorta, which prevented cannulation or placement of cross clamp, were excluded from this study. Consequently, data of 314 patients who underwent on-pump CABG were analyzed. Patient demographics are shown in Table 1. One hundred and forty-two patients underwent preoperative magnetic resonance angiography (MRA) to identify severe stenosis at the carotid or intracranial arteries. Postoperative cerebral infarction was diagnosed by a neurologist, and confirmed using a brain computed tomography scan. Acute arterial embolic events of the visceral organ or leg arteries were identified based on clinical signs, enzyme elevation and findings of exploratory operation. Plaque echo density of the aortic arch could not be measured in 24 patients because recorded TEE images were lost.

Methods

Transesophageal echocardiography

After general anesthesia, a biplane or multilane 3.5 MHz transesophageal transducer was placed in position to view the thoracic aorta. Aortic arch scan was performed using Hewlett-Packard 77030A and Sonos 5500 (Hewlett-Packard, Palo Alto, CA, USA) color flow duplex scan-

ner. All images were recorded for the subsequent playback evaluation. We assessed the distribution of atherosclerotic lesions of the entire thoracic aorta, and atheromatous lesions of the aortic arch on TEE were graded morphologically as follows: grade 1, normal or thickening of the intima extending less than 3 mm into the aortic lumen; grade 2, smooth-surfaced plaques and thickening of the intima extending more than 3 mm into the aortic lumen; grade 3, marked irregularity of the intimal surface and thickening of the intima extending more than 3 mm into the aortic lumen; grade 4, plaque with a mobile element.

Plaque echo density

In the presence of atheromatous plaque of grades 2, 3 and 4, we measured echo plaque density through computer analysis. Once the best available image of the aortic plaque was identified, it was recorded on video and the still image was digitized off-line on a personal computer using a commercially available video-grabber card. By means of Adobe Photoshop® (version 5.0, Adobe Systems Incorporated, San Jose, CA, USA) software, the digitized images were normalized by using linear scaling and two reference points of blood and adventitia. The GSM of the lumen (blood) part was assigned to a gray level of 0 to 5. GSM of the adventitia part was assigned to a gray level of 180 to 190, and the image was normalized by performing linear scaling with the "curves" option of the software. The gray tone frequency distribution of the pixels in the plaque was provided by the "histogram" facility of Adobe Photoshop®, and GSM of the plaque pixels was obtained and used as a measure of plaque echo density (Fig. 1).

Operative technique

After median sternotomy and harvest of the grafts, the typical end-hole arterial cannula (Research DF II 22Fr or 24Fr, Research Medical Inc., Midvale, UT, USA) at the ascending aorta and bicaval venous drainage was placed. Cardiopulmonary bypass was initiated, the aorta was cross-clamped, and myocardial protection was performed with retrograde continuous administration of cold-blood cardioplegia. In patients who had severe stenosis of carotid or intracranial arteries, CABG was carried out by the super pulse cardiopulmonary bypass (CPB) method that enabled maintenance of our original dynamic pulsatile flow of 3.0 to 3.5 L/min/m², mean arterial pressure of 70 to 80 mmHg and normothermia (35°C to 36°C).¹⁾ At the time of clamping and declamping, the CPB perfusion

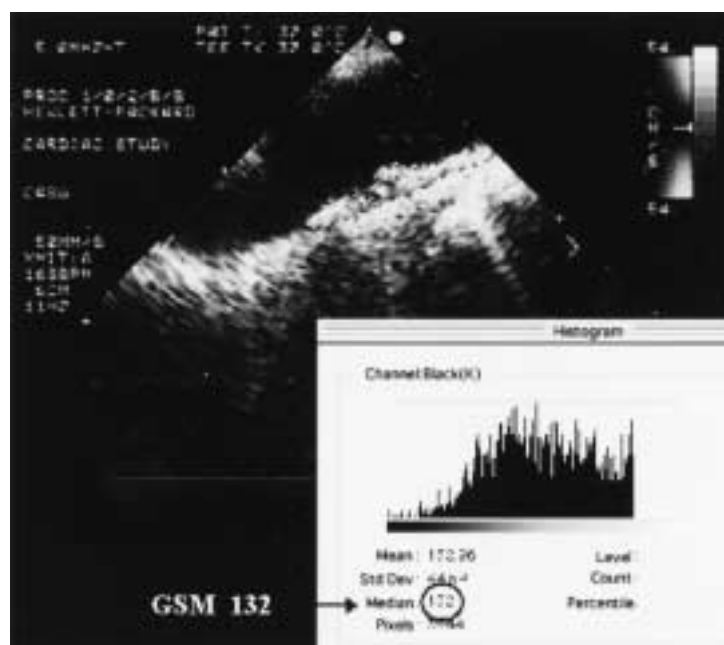


Fig. 1. The gray tone frequency distribution of the pixels in the plaque is provided by the “histogram” facility of Adobe Photoshop®. The median of the gray tone frequency distribution of the pixels in the plaque (GSM) on the normalized image was used as the objective measurement of the echo density.

flow rate was decreased and an anesthesiologist compressed patient’s neck vessels. Proximal and distal anastomoses were performed during a single period of aortic cross clamping.

Statistical analysis

Continuous variables are presented as mean ± standard deviation. Welch’s test and chi square test were used. The statistical calculation was performed using statistical package software, Microsoft Excel® (version 10.1, Microsoft Corporation, Redding, WA, USA) and StatView® (version 5.0, SAS Institute Inc., Cary, NC, USA) for Macintosh. P values of less than 0.01 were considered to be statistically significant.

Results

Clinical outcomes are summarized in Table 2. Postoperative stroke or embolic complications occurred in 11 patients including two patients who simultaneously developed brain and multiple organ embolism. On the other hand, preoperative MRA revealed that 29 patients had severe carotid or intracranial artery diseases with more than 90% of stenosis, and they underwent CABG with our original warm dynamic pulse extracorporeal circulation with no occurrence of stroke. Incidence of stroke or embolic events according to TEE plaque morphology in the aortic arch is shown in Table 3. In 223 patients with grade 1 of TEE findings, no perioperative stroke or em-

bolic episode occurred. However, there were a total of 11 (12.1%) strokes or embolism in 91 patients with plaque that was more than 3 mm in thickness, had irregular surface or was mobile.

Plaque echo density of the aortic arch in 67 patients whose TEE findings were greater than grade 2 and recorded on videotape was analyzed in a computer using the parameter of GSM. The relationship between plaque GSM and stroke or embolic event is shown in Fig. 2. Fifty-eight plaques in patients not associated with stroke or embolic events had GSM ranging from 58 to 241 (151.0±38.2), while 9 plaques in patients associated with

Table 2. Operative data

	The number of patients
CABG	314
Concomitant operation	0
Bypass/patient	3.2±0.8
CPB time (min)	145±39
XCL time (min)	108±29
Mortality	17 (5.4%)
Postoperative stroke	10
Embolic event	3
Foot	1
Visceral organ and brain	2
Postoperative stroke in cases of preoperative MRA cerebrovascular problem	0

CABG, coronary artery bypass grafting; CPB, cardiopulmonary bypass; XCL, aortic cross clamp; MRA, magnetic resonance angiography.

Table 3. TEE grades and postoperative stroke or embolic events

TEE grade	The number of patients	Percentage	Stroke	Other embolic events (simultaneous to stroke)
Grade 1	223	(71%)	0	0
Grade 2	59	(19%)	1	2 (1)
Grade 3	20	(6%)	4	2 (1)
Grade 4	12	(4%)	2	0

TEE, transesophageal echocardiography.

stroke or embolic events had GSM ranging from 67 to 130 (90.6 ± 21.3 , $p < 0.001$). Figure 3 shows GSM values of the aortic plaque according to the TEE morphological grading compared between patients with stroke or embolism and those without. For the purpose of analyzing the results, an arbitrary cut off point of 100 in GSM was taken to investigate if separation of stroke or embolic events could be seen. The incidence of stroke or embolism was 58.3% when plaque GSM was less than 100, while it was 3.6% when plaque GSM was more than 100 (Table 4, $p < 0.001$, with Fisher's exact method).

Discussion

The risk of stroke in patients undergoing coronary artery bypass surgery is reported to be 2% to 4%.²⁻⁵ Perioperative

embolic complications of the central nervous system and body are one of the most important causes of morbidity and mortality associated with on-pump CABG. The cause of perioperative stroke in patients undergoing on-pump CABG is multifactorial, but is considered to include two major important factors. One is severe stenosis of the carotid or intracranial arteries, which causes hypoperfusion of the brain during CPB.⁶ The other is atheromatous embolism resulting in the diseased aortic debris being dislodged by using CBP.^{7,8} In an autopsy series of patients suffering early postoperative deaths, Blauth et al. report that the evidence of atheroemboli is found in 48 (21.7%) of 221 patients and the brain is the most commonly involved organ.⁷ In our study, preoperative MRA screening was performed in 45.2% patients undergoing CABG to identify severe stenosis. Although 29 patients (20.4%) had severe stenosis of greater than 90%, they did not suffer cerebral infarction when our original dynamic pulsatile CPB was employed. Our original dynamic pulse method was contraindicated for patients in whom friable plaque was observed in the ascending aorta or arch, because the jet type blood flow induced by this method might scatter debris to the systemic circulation.¹¹ All 29 patients who underwent the dynamic pulse method had grade 1 plaques on TEE examination. Many previous reports have suggested that the diseased ascending aorta is a main risk factor of stroke.⁹⁻¹¹ In our strategy, the patients whose atheromatous ascending aorta was detected by epi-aortic echography underwent off-pump CABG to avoid any direct manipulation of the ascending aorta. Although we excluded the patients with these diseased ascending aorta from this study, cerebral infarction occurred in 2.6% patients. Katz et al. describe that the high-pressure jet emanating from the cannula tip may break down the fragile atheromatous plaque of the aortic arch.¹² Weinstein suggests that end-hole aortic cannulas, which produce a single high velocity jet at the left carotid orifice, are responsible for a strong predominance of left hemispheric strokes in on-pump CABG.¹³ Some studies have been performed

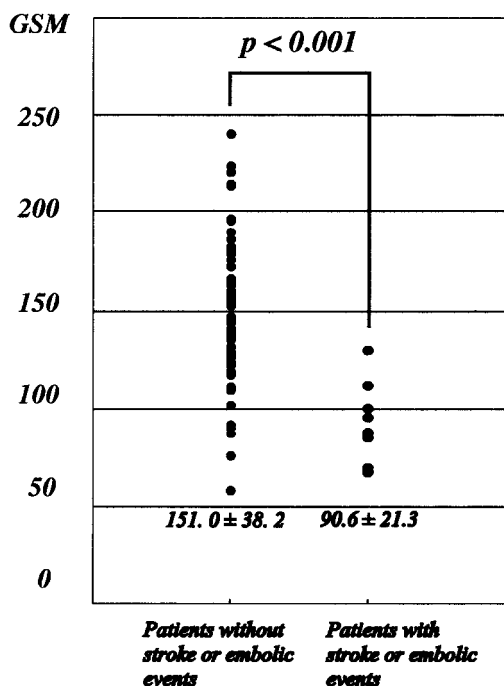


Fig. 2. The GSM values of the aortic plaque associated with and without stroke or embolism.

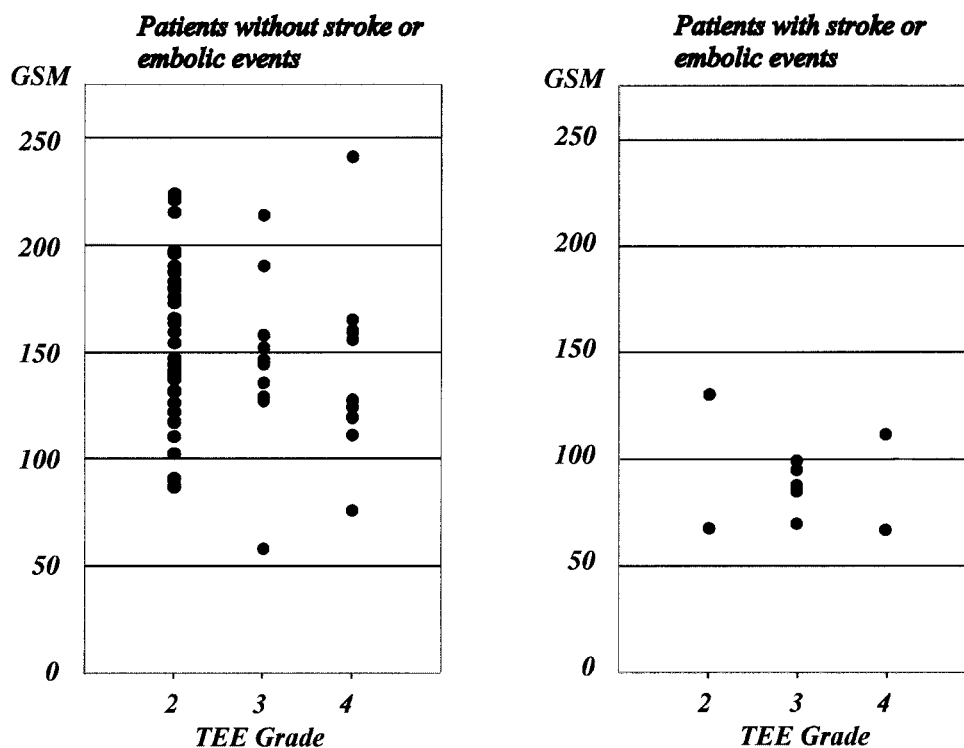


Fig. 3. Relationship of the morphology with GSM values of the aortic plaque associated with and without stroke or embolism.

Table 4. The relationship between plaque GSM and post-operative stroke or embolic events

	No stroke or embolism	Stroke or embolism	Total
GSM≤100	5	7 (58.3%)	12
GSM>100	53	2 (3.6%)	55
Total	58	9	67

to clarify the vulnerable plaque of the atheromatous aorta that may be broken down by the CPB arterial jet flow. Ribakove et al. propose a grading scale of 1 to 5 for atheromatous disease of the aorta, although their morphological classification is obscure and not objective.¹⁴⁾ Mizuno et al. measure intimal thickness for quantitative analysis, and suggest that intimal thickened to more than 5 mm is at a significantly high risk of stroke.¹⁵⁾ Nevertheless, measurement of intimal thickness is changeable by rotating the probe at the level of the arch, and it is difficult to define the plaque characteristics.

Plaque echo density

This study indicated that the plaque which caused a high risk of postoperative stroke or embolism could be identified by analyzing the aortic plaque echo density. In patients with carotid bifurcation disease, several investigators have shown that hypoechoic plaques are associated

with a higher incidence of transient ischemic attacks and brain infarction than hyperechoic ones.¹⁶⁻²⁰⁾ It has been suggested that hypoechoic, lipid rich plaques are associated with an increased risk of stroke or embolism because they are vulnerable to rupture. el-Barghouty et al. measure plaque echogenicity on B-mode ultrasound by estimating the median of the gray scale content through computer image analysis to achieve accurate plaque characterization.¹⁸⁾ In the study by Sabetai et al. computer-assisted plaque characterization with B-mode image normalization by means of digital image processing has been proposed to be a reliable method for the objective and quantitative assessment of carotid plaque echo morphology.²⁰⁾ In our study, it was confirmed that hypoechoic plaques (GSM of less than 100) were associated with a higher incidence of perioperative stroke or embolic events. It has been suggested that echolucent plaques (that are black-colored and have lower GSM on B-mode imaging)

are associated with a higher content of lipids, thin fibrous cap and thrombus attachment, while echogenic plaques (that are white-colored and have higher GSM on B-mode imaging) contain a larger amount of fibrous tissue and calcium deposition. This is probably because echolucent plaques are more prone to rupture and more emboli than echogenic plaques. The use of on-pump or off-pump procedure for CABG candidates depends on the surgeon's technical level. However the surgeon's decision-making remains the most important factor contributing to the outcome of the operation when TEE reveals echolucent atheromatous aortic plaque in patients preparing on-pump CABG. Our data suggest that there should be no hesitation in converting the operation from on-pump to off-pump CABG if the aortic plaque density (GSM) is less than 100. This identification of plaques at high risk of on-pump CABG could be used for selecting patients who were subject to undergoing off-pump procedure and for decreasing the incidence of postoperative stroke or embolism.

In conclusion, our findings suggested that it was very important to detect the fragile atheromatous plaque of the aortic arch that might be broken down by the arterial jet flow for cardiac surgeons who determined the strategy to avoid embolic complications in on-pump CABG patients.

References

- Higami T, Kozawa S, Asada T, et al. Coronary artery bypass grafting using the "Super Pulse" dynamic pulsatile cardiopulmonary bypass device in patients with cerebrovascular occlusive disease. *Ann Thorac Cardiovasc Surg* 2000; **6**: 173–8.
- Lynn GM, Stefanko K, Reed JF 3rd, Gee W, Nicholas G. Risk factors for stroke after coronary artery bypass. *J Thorac Cardiovasc Surg* 1992; **104**: 1518–23.
- Tuman KJ, McCarthy RJ, Najafi H, Ivankovich AD. Differential effects of advanced age on neurologic and cardiac risks of coronary artery operations. *J Thorac Cardiovasc Surg* 1992; **104**: 1510–7.
- Salomon NW, Page US, Bigelow JC, Krause AH, Okies JE, Metzdorff MT. Coronary artery bypass grafting in elderly patients. Comparative results in a consecutive series of 469 patients older than 75 years. *J Thorac Cardiovasc Surg* 1991; **101**: 209–17.
- Almassi GH, Sommers T, Moritz TE, et al. Stroke in cardiac surgical patients: determinants and outcome. *Ann Thorac Surg* 1999; **68**: 391–7.
- D'Agostino RS, Svensson LG, Neumann DJ, Balkhy HH, Williamson WA, Shahian DM. Screening carotid ultrasonography and risk factors for stroke in coronary artery surgery patients. *Ann Thorac Surg* 1996; **62**: 1714–23.
- Blauth CI, Cosgrove DM, Webb BW, et al. Atheroembolism from the ascending aorta: an emerging problem in cardiac surgery. *J Thorac Cardiovasc Surg* 1992; **103**: 1104–11.
- Barbut D, Lo YW, Hartman GS, et al. Aortic atheroma is related to outcome but not numbers of emboli during coronary bypass. *Ann Thorac Surg* 1997; **64**: 454–9.
- Davila-Roman VG, Barzilay B, Wareing TH, Murphy SF, Schechtman KB, Kouchoukos NT. Atherosclerosis of the ascending aorta: prevalence and role as an independent predictor of cerebrovascular events in cardiac patients. *Stroke* 1994; **25**: 2010–6.
- Nicolosi AC, Aggarwal A, Almassi GH, Olinger GN. Intraoperative epiaortic ultrasound during cardiac surgery. *J Card Surg* 1996; **11**: 49–55.
- Hammon JW Jr, Stump DA, Kon ND, et al. Risk factors and solutions for the development of neurobehavioral changes after coronary artery bypass grafting. *Ann Thorac Surg* 1997; **63**: 1613–8.
- Katz ES, Tunick PA, Rusinek H, Ribakove G, Spencer FC, Kronzon I. Protruding aortic atheromas predict stroke in elderly patients undergoing cardiopulmonary bypass: experience with intraoperative transesophageal echocardiography. *J Am Coll Cardiol* 1992; **20**: 70–7.
- Weinstein GS. Left hemispheric strokes in coronary surgery: implications for end-hole aortic cannulas. *Ann Thorac Surg* 2001; **71**: 128–32.
- Ribakove GH, Katz ES, Galloway AC, et al. Surgical implications of transesophageal echocardiography to grade the atheromatous aortic arch. *Ann Thorac Surg* 1992; **53**: 758–61.
- Mizuno T, Toyama M, Tabuchi N, et al. Thickened intima of the aortic arch is a risk factor for stroke with coronary artery bypass grafting. *Ann Thorac Surg* 2000; **70**: 1565–70.
- Reilly LM, Lusby RJ, Hughes L, Ferrell LD, Stoney RJ, Ehrenfeld WK. Carotid plaque histology using real-time ultrasonography: clinical and therapeutic implications. *Am J Surg* 1983; **146**: 188–93.
- Geroulakos G, Ramaswami G, Nicolaides A, et al. Characterization of symptomatic and asymptomatic carotid plaques using high-resolution real-time ultrasonography. *Br J Surg* 1993; **80**: 1274–7.
- el-Barghouty N, Geroulakos G, Nicolaides A, Androulakis A, Bahal V. Computer-assisted carotid plaque characterisation. *Eur J Vasc Endovasc Surg* 1995; **9**: 389–93.
- Tegos TJ, Sabetai MM, Nicolaides AN, et al. Correlates of embolic events detected by means of transcranial Doppler in patients with carotid atheroma. *J Vasc Surg* 2001; **33**: 131–8.
- Sabetai MM, Tegos TJ, Nicolaides AN, et al. Hemispheric symptoms and carotid plaque echomorphology. *J Vasc Surg* 2000; **31**: 39–49.