Case Report

Resection of Giant Right Atrial Lymphoma Using Vacuum-assisted Cardiopulmonary Bypass without Snaring the Inferior Vena Cava

Hankei Shin,[1] Mitsuharu Mori,[1] Toru Matayoshi,[2] Ryo Suzuki,[1] and Ryohei Yozu[1]

A 53-year-old man sustained hemodynamic collapse due to a huge right atrial tumor and was transferred to our hospital and underwent a life-saving emergency operation. The tumor arose from the inferolateral wall of the right atrium, occupying almost the whole right atrial cavity and obstructing not only the inflow of the right ventricle but also the orifice of the inferior vena cava. Venous cannulation via the right atrial wall and placing a snare around the inferior vena cava were impossible. With a cardiopulmonary bypass using vacuum-assisted venous drainage, the tumor was successfully resected and the tricuspid valve was replaced with a bioprosthetic valve without snaring the inferior vena cava. Postoperative histological examination demonstrated the tumor to be a large B-cell non-Hodgkin type malignant lymphoma. When the tumor is large and it is difficult to establish total cardiopulmonary bypass, the vacuum-assisted cardiopulmonary bypass is a useful option. This can achieve a bloodless operative field and is not blocked by the incoming air, due to the venous drainage being continually pressure-regulated. (Ann Thorac Cardiovasc Surg 2004; 10: 249–51)

Key words: cardiac tumor, malignant lymphoma, vacuum-assisted cardiopulmonary bypass

Introduction

Resection of a right atrial tumor is usually performed under total cardiopulmonary bypass (CPB) with snares around the superior vena cava (SVC) and inferior vena cava (IVC). When the tumor obstructs orifices of the vena cavae and protrudes into these, it becomes impossible to establish total CPB with snares of the vena cavae, and hypothermic circulatory arrest is usually needed to resect the tumor completely. We present here a case in which the huge right atrial malignant lymphoma was successfully resected using vacuum-assisted CPB without establishing total CPB or hypothermic circulatory arrest.

From [1]Division of Cardiovascular Surgery and [2]Medical Engineering Center, Keio University School of Medicine, Tokyo, Japan

Received January 14, 2004; accepted for publication February 24, 2004.
Address reprint requests to Hankei Shin, MD: Division of Cardiovascular Surgery, Keio University School of Medicine, 35 Shinanomachi, Shinjuku-ku, Tokyo 160-8582, Japan.

Case Report

A 53-year-old man was transferred from a community hospital to our hospital following hemodynamic collapse. Echocardiography showed that an abnormal mass occupied almost the entire right atrial cavity and was obstructing the inflow of the right ventricle; and the right ventricle and the main pulmonary artery were collapsed. Both computed tomography and magnetic resonance imaging suggested that the mass was a huge tumor. Since this patient's general condition deteriorated rapidly after admission to our hospital, a life-saving emergency operation was performed the same day.

A median sternotomy was made and the heart was exposed. Direct measurement of the pulmonary artery pressure showed that the pulse wave was lost; the mean value was 3 mmHg. The central venous pressure at this time was 17 mmHg. The tumor arose from the inferolateral wall of the right atrium, occupying almost the whole right atrial cavity, so that venous cannulation via the right atrial wall and placing a snare around the IVC were impossible (Fig. 1). Therefore, the ascending aorta was cannulated

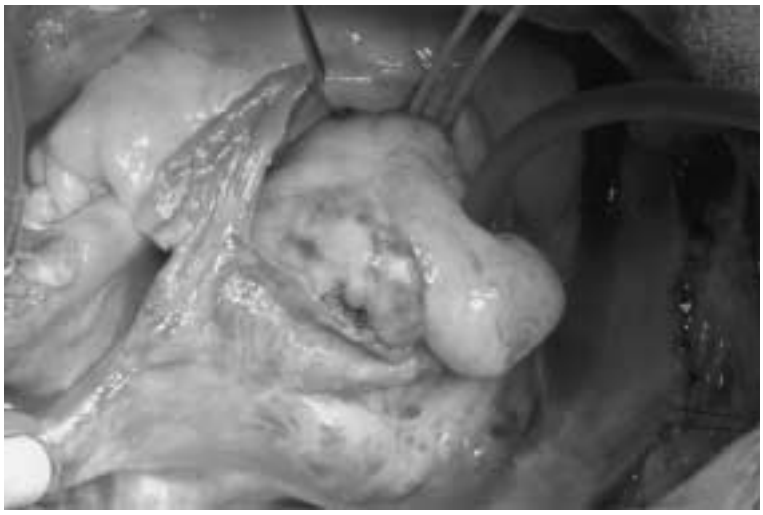

Fig. 1. Large right atrial malignant lymphoma, occupying almost the entire right atrial cavity and obstructing the inflow of the right ventricle and the orifice of the inferior vena cava.

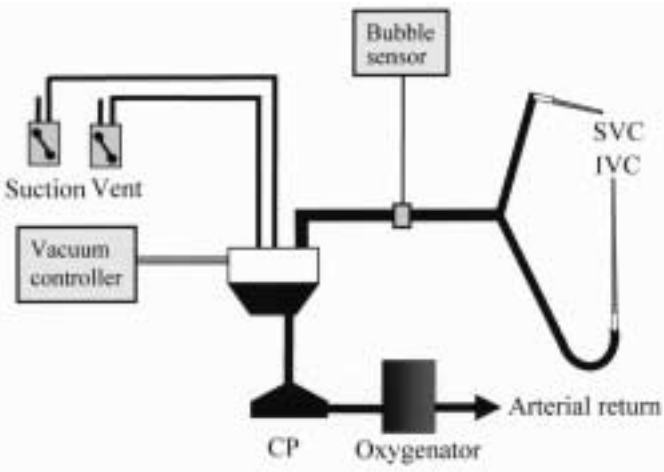

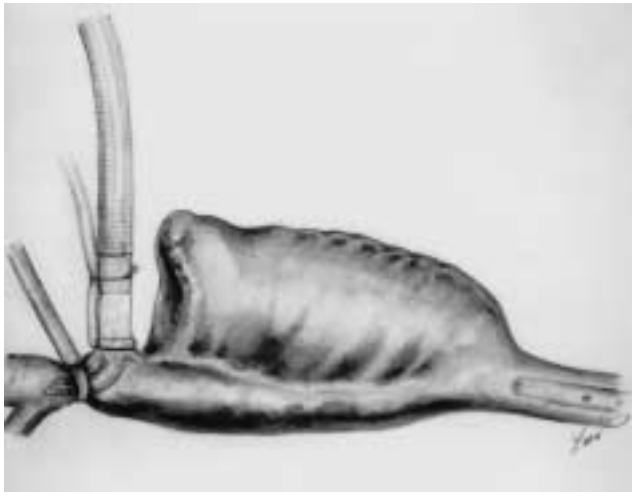

Fig. 2. Cardiopulmonary bypass circuit with vacuum-assisted venous drainage was used. The superior vena cava is directly cannulated and snared. The inferior vena cava is not snared and venous return is performed through a venous return cannula introduced via the right femoral vein. A bubble detector is installed on the venous drainage line. CP, centrifugal pump; SVC, superior vena cava; IVC, inferior vena cava.

and CPB was established with a 20-F long venous return cannula introduced into the IVC via the right femoral vein and another 24-F common right-angled venous return cannula placed in the SVC. A bubble sensor (Bubble Sensor 23-07-45, Stöckert, München, Germany) was installed on the venous drainage line to monitor air sucked via the IVC venous return cannula following right atrial incision (Fig. 2). The ascending aorta was cross-clamped and cold blood cardioplegia was infused into the aortic root. The perfusion flow rate was 2.4 L/m/m^2 and the patient was cooled to 30°C. After a snare around the SVC had been tightened up, the right atrium was opened along the atrioventricular groove. The solid tumor, arising from the inferolateral wall of the right atrium, almost completely filled the atrial cavity, and obstructed the tricuspid valve and the orifice of the IVC. The tumor was dissected from the tricuspid valve and resected completely together with the right atrial wall. The right atrial wall was excised down to the interatrial groove and the border between the right atrium and the IVC orifice. Even after resecting the tumor, it was impossible to bring about total CPB with the IVC clamped because the remnants of the IVC allowed only suturing for reconstruction of the right atrium. The non-functioning tricuspid valve was replaced with a 33-mm bioprosthesis, and the atrial wall was reconstructed with the autologous pericardium. During this procedure,

venous drainage from the IVC was regulated by vacuum pressure, between 20 and 60 mmHg. When the bubble sensor installed on the venous drainage line detected any air sucked via the IVC venous return cannula, the vacuum pressure was slightly reduced. When venous blood coming from the IVC disturbed the surgeons performing the procedure, which the perfusionist could observe on the video monitor, the pressure was increased to facilitate venous drainage and achieve a bloodless operative field. This CPB technique allowed complete resection of the large right atrial tumor without snaring the IVC. Postoperative histological examination demonstrated the tumor to be a large B-cell non-Hodgkin type malignant lymphoma. Eleven months after the operation, the patient has continuing chemotherapy, but there is no recurrence of the tumor in the heart.

Discussion

Right atrial tumors are usually resected under total CPB with snares around the SVC and IVC, but snaring is not always possible because of occupation by the tumor. Opening of the right atrium without these may cause air suction into the venous drainage line; particularly when the pump technician tries to achieve a bloodless field. When venous drainage is achieved by gravity, air suction into the venous drainage line may block this line, so that maintenance of CPB may become difficult. The problem arises even if a centrifugal pump augments venous return. Although hypothermic circulatory arrest is an option to resect the tumor without snares of the vena cavae,[1-4] this option is not realistic for complex lesions because the permitted circulatory arrest time is limited. CPB with vacuum-assisted venous drainage is not blocked by air sucked in because the venous drainage is continually pressure-regulated. A bloodless operative field can be achieved by regulation of vacuum pressure. It is important to minimize air suction by monitoring the sucked air using a bubble sensor as massive air suction may lead to hemolysis.

The CPB method described here allows complete resection of a right atrial tumor easily and safely without hypothermic circulatory arrest even when snaring the vena cavae is not possible.

References

1. Chu MW, Aboguddah A, Kraus PA, Dewar LR. Urgent heart surgery for an atrial mass: metastatic hepatocellular carcinoma. *Ann Thorac Surg* 2001; **72**: 931–3.
2. Rousou JA, Tighe DA, Rifkin RD, et al. Echocardiography allows safer venous cannulation during excision of large right atrial masses. *Ann Thorac Surg* 1998; **65**: 403–6.
3. Savino JS, Weiss SJ. Images in clinical medicine. Right atrial tumor. *N Eng J Med* 1995; **333**: 1608.
4. Takagi M, Kugimiya T, Fujii T, et al. Extensive surgery for primary malignant lymphoma of the heart. *J Cardiovasc Surg* 1992; **33**: 570–2.