Case Report

Aortic Root Replacement with a Freestyle Stentless Valve for Aortitis Syndrome with Ascending Aortic Aneurysm and Aortic Regurgitation

Yoshiharu Nishimura, Yoshitaka Okamura, Keiichi Fujiwara, Shuji Yamamoto, Atsutoshi Hatada, and Takahiro Hisaoka

A 47-year-old woman who had been diagnosed as having aortitis syndrome underwent aortic root replacement for an ascending aortic aneurysm and aortic regurgitation. Because the patient has been treated with steroids for more than 20 years, a Freestyle stentless valve was used to avoid the risk of valve detachment. There were no complications observed during the postoperative course. Although long-term follow-up will be necessary to observe the valve durability, the Freestyle stentless valve seems to be useful for aortic root replacement in patients at high risk of valve detachment due to aortitis syndrome. (Ann Thorac Cardiovasc Surg 2004; 10: 259–62)

Key words: Freestyle stentless valve, aortitis syndrome

Introduction

Aortitis syndrome is an inflammatory vascular disease that often involves the aorta and its main branches, causing aortic regurgitation and coronary ostial stenosis.[1-3] In the surgical management of aortic regurgitation in aortitis syndrome, prosthetic valve detachment is one of the major complications.[1,2] This report describes a successful case of aortic root replacement with a Freestyle stentless valve for aortitis syndrome with ascending aortic aneurysm and aortic regurgitation.

Case Report

A 47-year-old woman previously diagnosed as having aortitis syndrome was admitted to hospital for surgery to correct an ascending aortic aneurysm and aortic regurgitation. The patient had been given a daily oral dose of 20 to 40 mg of predonisolone since 21 years of age. Past history included pyoderma gangrenosum, lumbar compression fracture and cataract. On physical examination, moon face was observed. Blood pressure was 158/60 mmHg in the right arm and 108/78 mmHg in the left arm. The chest auscultation demonstrated a grade 3/6 diastolic murmur on the left sternal border. Laboratory data of the inflammatory marker disclosed: white blood cell count, 12,700/μl; erythrocyte sedimentation rate, 92 mm/hr; C-reactive protein, 2.5 mg/dl ,which were controlled by steroid pulse therapy preoperatively. Preoperative transesophageal echocardiography (Fig. 1) demonstrated moderate (grade 3/4) aortic regurgitation without annular dilatation and marked dilatation of the ascending aorta just above the annulus. Intravenous digital subtraction angiography (Fig. 2) demonstrated an ascending aortic aneurysm and obstruction of the left subclavian artery. Computed tomography showed an ascending aortic aneurysm with a maximal diameter of 8 cm and a narrow descending aorta. Although preoperative coronary angiography was not indicated for this patient, there were no ischemic findings observed by myocardial scintigraphy. Based on these findings, the patient was considered a candidate for replacement of the aortic root and ascending aorta.

Surgery was conducted via median sternotomy on June 14, 2002. Cardiopulmonary bypass was achieved by femo-

From Department of Thoracic and Cardiovascular Surgery, Wakayama Medical University, Wakayama, Japan

Received November 20, 2003, accepted for publication February 6, 2004.
Address reprint requests to Yoshiharu Nishimura: Department of Thoracic and Cardiovascular Surgery, Wakayama Medical University, 811-1 Kimiidera, Wakayama City, Wakayama 641-8509, Japan.

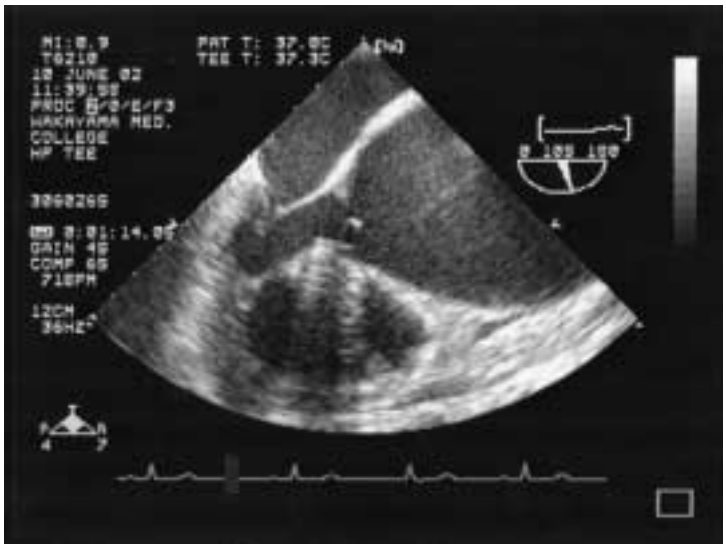

Fig. 1. Preoperative transesophageal echocardiogram (TEE). TEE demonstrated an ascending aortic aneurysm without annular dilatation. Doppler echocardiographic study demonstrated moderate aortic regurgitation.

Fig. 2. Preoperative intravenous digital subtraction angiography (IVDSA). IVDSA demonstrated an ascending aortic aneurysm and obstruction of the left subclavian artery.

ral and bi-caval cannulation. Because of severe adhesion of the aortic root and ascending aorta to the surrounding tissue, the aneurysm was opened and the aortic root was exposed under hypothermic circulatory arrest. The right coronary ostium was occluded. The aortic annulus was small and the 21 mm valve-sizer was tight. The ascending aorta was dissected and cross-clamped, then distal perfusion was resumed. Aortic root replacement was performed using a 21-mm Freestyle stentless valve (Medtronic, Inc., Minneapolis, MN) by the full root method with 24 interrupted mattress suture. A Dacron patch was used to reinforce the anastomotic site. The ascending aorta was transected and anastomosed to the woven Dacron graft (24 mm Hemashieled Gold™, Boston Scientific Medi-tech, Wayne, NJ) by open distal anastomosis under retrograde cerebral perfusion. After the anastomosis was finished, the Dacron graft was clamped and distal perfusion was resumed. The Carrel patch method was used for reattachment of the left coronary artery with reinforcement by gelatin-resorcin-formalin glue. Coronary artery bypass grafting to the right coronary artery was not performed because the orientation of the coronary artery was difficult due to severe adhesion around the epicardial surface. Finally, the proximal Freestyle stentless valve and distal Dacron graft were anastomosed. The patient was weaned uneventfully from cardiopulmonary bypass.

The postoperative course was satisfactory. On ultrasonography, there was no aortic regurgitation observed. Three-dimensional reconstruction of computed tomographic scan (Fig. 3) confirmed excellent results of the anastomotic sites. Biopsy specimen demonstrated myxoid degeneration in the valvular tissue. The aneurysmal wall showed marked myxoid degeneration and sclerosis. Seventeen months postoperatively the patient is doing well without aortic regurgitation or aneurysmal change at the anastomotic site and continues on steroid medication.

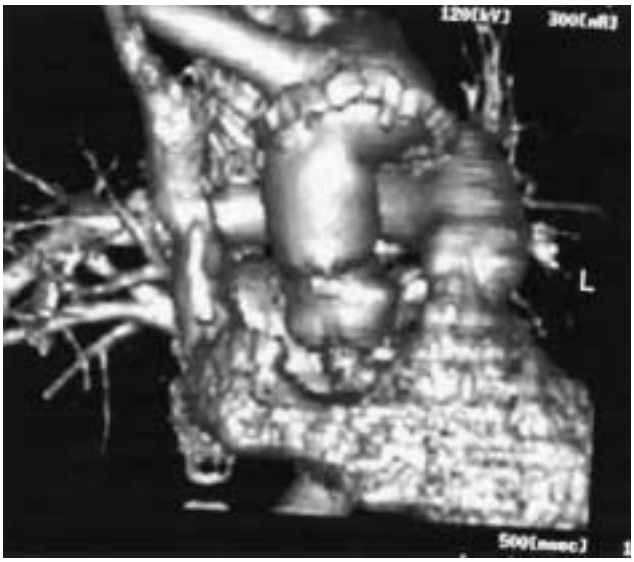

Fig. 3. Three-dimensional reconstruction of computed tomographic scan (3D-CT). 3D-CT confirmed excellent results of the anastomotic sites.

Discussion

It is well documented that major complications of surgical treatment for aortic regurgitation secondary to aortitis syndrome are prosthetic valve detachment and the formation of pseudoaneurysm at the anastomotic site.[1-3] Bentall procedure is one of the surgical strategies for ascending aortic aneurysm associated with aortic regurgitation in aortitis syndrome. However, serious complications due to mechanical valve detachment have been reported previously.[1] In particular, the risk of this complication is thought to be much higher when surgery is performed during the active stage of the inflammation.

As described above, a Freestyle stentless valve was used for aortic root reconstruction in the present case. The reasons to select the Freestyle stentless valve in this patient were as follows. The risk of mechanical valve detachment was considered high because steroid pulse therapy was required to control the preoperative inflammation. Because the annulus of the aortic valve was narrow rather than ectatic, the total root replacement using a Freestyle stentless valve was expected to provide the excellent hemodynamic performance due to its less obstructive profile.[4,5] In addition, the Freestyle stentless valve does not require the use of anticoagulation therapy and this may be beneficial for a patient who will continue to receive steroid therapy in the future.

Regarding other surgical procedures, aortic valve-sparing operation was not indicated for this aortitis patient because of severe inflammatory adhesion around the aortic root. Although aortic homografts may be an attractive alternative to root replacement for aortitis syndrome, the clinical use of homografts is severely restricted by the limited availability of donor organs. In clinical practice, the Freestyle stentless valve was introduced to imitate the hemodynamic performance and handling property of homografts.[5,6] In this case, a Freestyle stentless valve was used as a composite graft along with woven Dacron graft for replacement of the aortic root and ascending aorta.[7,8] This interposed vascular graft was useful to correct the diameter mismatch between the dilated ascending aorta and Freestyle stentless valve.

As to the bioprosthetic valve in patients receiving steroid therapy, some reports suggested that calcific degeneration of bioprosthetic valve might be suppressed by long-term treatment with steroids.[9,10] It was also reported that the rate of calcium deposition in the aortic wall of the Freestyle stentless valve was lower than that observed in the homograft.[11,12] However, these problems are still controversial, and strict long-term follow-up will be necessary for the patients using a Freestyle stentless valve with steroid therapy.

In summary, replacement of the aortic root and ascending aorta with a Freestyle stentless valve and Dacron graft is thought to be one of the surgical options for aortitis syndrome. The early postoperative course has been satisfactory, however, long-term follow-up is mandatory to determine the durability of the Freestyle stentless valve.

References

1. Furukawa K, Ohteki H, Ohnishi H, Narita Y. Redo Bentall operation for the aortitis syndrome. *J Cardiovasc Surg* 2000; **41**: 255–8.
2. Sasaki S, Yasuda K, Takigami K, Shiiya N, Matsui Y, Sakuma M. Takayasu's arteritis complicating annuloaortic ectasia (AAE) treated with modified Bentall procedure. *J Cardiovasc Surg (Torino)* 1997; **38**: 381–4.
3. Harada H, Honma Y, Hachiro Y, Mawatari T, Abe T. Composite graft replacement after aortic valvuloplasty in Takayasu arteritis. *Ann Thorac Surg* 2002; **73**: 644–7.
4. Kon ND, Riley RD, Adair SM, Kitzman DW, Cordell AR. Eight-year results of aortic root replacement with the freestyle stentless porcine aortic root bioprosthesis. *Ann Thorac Surg* 2002; **73**: 1817–21.
5. Kappetein AP, Braun J, Baur LH, et al. Outcome and follow-up of aortic valve replacement with the freestyle

stentless bioprosthesis. *Ann Thorac Surg* 2001; **71**: 601–8.
6. Fukui T, Suehiro S, Shibata T, Hattori K, Hirai H, Aoyama T. Aortic root replacement with freestyle stentless valve for complex aortic root infection. *J Thorac Cardiovasc Surg* 2003; **125**: 200–3.
7. Hata H, Iida M, Kashiwazaki S, et al. Replacement of the aortic root and ascending aorta using a Freestyle valve and woven Dacron graft. *Artif Organs* 2002; **26**: 862–7.
8. Markowitz A. Utility of the full root bioprosthesis in surgery for complex aortic valve-ascending aortic disease. *Semin Thorac Cardiovasc Surg* 2001; **13**: 12–5.
9. Eishi K, Ishibashi-Ueda H, Nakano K, et al. Calcific degeneration of bioprosthetic aortic valves in patients receiving steroid therapy. *J Heart Valve Dis* 1996; **5**: 668–72.
10. Shimazaki Y, Kuraoka S, Takeda F, Watanabe T, Inui K. Mitral valve re-replacement for impaired bioprosthesis after 19 years in a patient undergoing steroid treatment. *J Heart Valve Dis* 2003; **12**: 45–7.
11. Melina G, Rubens MB, Amrani M, Khaghani A, Yacoub MH. Electron beam tomography for cusp calcification in homograft versus Freestyle xenografts. *Ann Thorac Surg* 2001; **71**: S368–70.
12. Melina G, Rubens MB, Birks EJ, Bizzarri F, Khaghani A, Yacoub MH. A quantitative study of calcium deposition in the aortic wall following Medtronic Freestyle compared with homograft aortic root replacement: a prospective randomized trial. *J Heart Valve Dis* 2000; **9**: 97–103.