Original Article

Epicardial Radiofrequency Ablation on a Beating Heart: An Experimental Study

Susumu Ishikawa, MD,[1] Shigeru Oki, MD,[1] Masato Muraoka, MD,[1]
Kiyohiro Oshima, MD,[1] Kenji Kashiwabara, MD,[2] and Yasuo Morishita, MD[1]

Purpose: The effect of epicardial radiofrequency ablation (RFA) during normal heart beating was experimentally studied in order to establish safe and effective procedures for RFA.
Methods: Seven pigs weighing approximately 30 to 50 kg were used in this study. Fifty-one epicardial RFA lesions were created on both atria using a Cobra Cooled™ probe with continuous internal irrigation of a saline solution. The ablation temperature was fixed at 80°C and the duration of the RFA in each case was 20, 30, 60 and 120 seconds.
Results: There was significant positive correlation between the right and left atria in wall thickness. Transmural coagulation was obtained in 69% of the total specimens, which decreased according to the increase of wall thickness especially over 3 mm. Transmural coagulation was seen in 64% of the specimens after RFA of less than 30 seconds, and 86% after ablation of ≥60 seconds. Occurance of 90% or deeper coagulation was higher in the right atrium than in the left one (97% vs. 78%). Right atrial rupture occurred in a region of 1 mm in thickness after ablation of 60 seconds.
Conclusion: Further technical improvements associated with new instruments are indispensable to complete epicardial RFA procedures on a beating heart. (Ann Thorac Cardiovasc Surg 2005; 11: 21–4)

Key words: radiofrequency ablation, atrial fibrillation, beating heart, experiment

Introduction

The use of radiofrequency ablation (RFA) has recently been accepted and widespread as an effective intraoperative treatment for atrial fibrillation (AF). Corresponding to the increase of cases, complications of RFA have been recently reported, including atrio-esophageal fistula[1,2)] and coronary artery obstruction.[3)] The number of basic studies is still limited when compared to clinical reports, and the optimal time and temperature settings for epicardial ablation have not been established especially under the condition of a beating heart. The purpose of this study was to experimentally evaluate the effect of radiofrequency energy focusing on the wall thickness of atria and ablation time in order to establish a safe and appropriate procedure of intraoperative RFA.

From [1]Second Department of Surgery, Gunma University Graduate School of Medicine, and [2]Division of Diagnostic Pathology, Gunma University Hospital, Maebashi, Japan

Received March 11, 2004; accepted for publication August 8, 2004.
Address reprint requests to Susumu Ishikawa, MD: Second Department of Surgery, Gunma University Graduate School of Medicine, 3-39-22 Showa-machi, Maebashi, Gunma 371-8511, Japan.

Materials and Methods

Seven pigs weighing approximately 30 (n=5) and 50 (n=2) kg were used in this study. The pericardium was opened through a median sternotomy under general anesthesia. Radio-frequency lesions were created using a unipolar flexible, 7-electrode, temperature controlled Cobra Cooled™ surgical probe (EP Technologies, Boston Scientific Corporation, San Jose, CA). A total number of 51 RFA lesions were created on both atria of the beating heart, including 33 lesions on the right atrium and 18 on the left atrium. A Cobra Cooled™ surgical probe was used with continuous internal irrigation of a saline solution (500

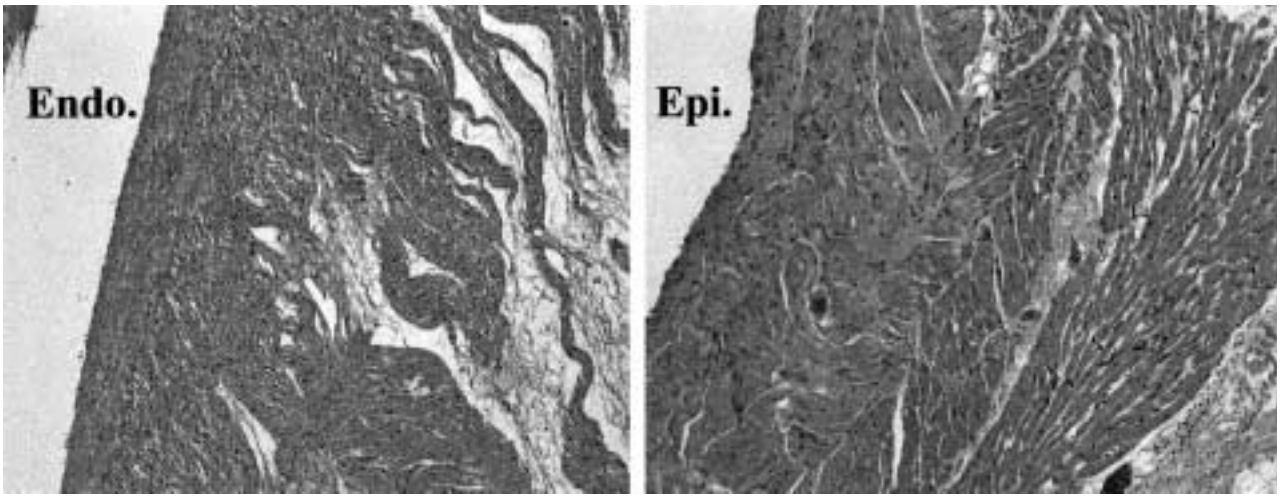

Fig. 1. Histopathological findings (Hematoxylin-eosin stain).
A: 100% (transmural) coagulation
B: 60% (less than 80%) coagulation
Endo., endocardium; Epi., epicardium

A | **B**

ml/h). A Cobra Cooled™ surgical probe is an improved model of non-irrigation type of Cobra™ probe with seven flexible electrodes. An internally cooled system is designed for controlled heat removal. This reduces temperatures at the tissue-electrodes interface, allowing for greater energy delivery and larger and deeper lesions. The ablation temperature was fixed at 80°C. One or two electrodes were used for ablation and the duration of the RFA in each case was 20, 30, 60 and 120 seconds. A new support adapter, which was created in order to insure better contact between the ablation probe and a beating heart were used for the RFA on the posterior wall of left atrium. Myocardial transmural specimens were harvested from both atria two hours after RFA and evaluated histopathologically using He matoxylin-eosin stain. The results were classified into three groups; transmural coagulation (100%), transmusclar coagulation except for endocardium (90%) and less than 80% (Fig. 1). The co-relations of the RFA effect and wall thickness and ablation time were studied. All animals in this study received humane care in compliance with the "Guide for the Care and Use of Laboratory Animals" (NIH Publication No.86-23, revised 1985).

Statistical analysis was conducted with SAS version 5.0 software (SAS Institute, Inc., Cary, NC). The values were expressed as the mean ± the standard error of the mean. The Students' t-test and the χ^2-test were used for statistical analysis, and a p value of less than 0.05 was considered to be significant.

Results

The mean wall thickness of the right and left atrium in pigs weighing 30 kg were 2.1±0.8 and 2.2±1.0 mm, respectively. In pigs weighing 50 kg the values were 3.1±1.2 and 3.7±1.2 mm, respectively. There was significant (p=0.03) correlation between the right and that of left atria in wall thickness (LA=1.086×RA+0.322) (Fig. 2). Transmural coagulation was obtained in 69% of the total specimens, which decreased according to the increase of wall thickness (Table 1). With respect to the ablation time, transmural coagulation was seen in 64% of specimens after RFA less than 30 seconds, and 86% after ablation of

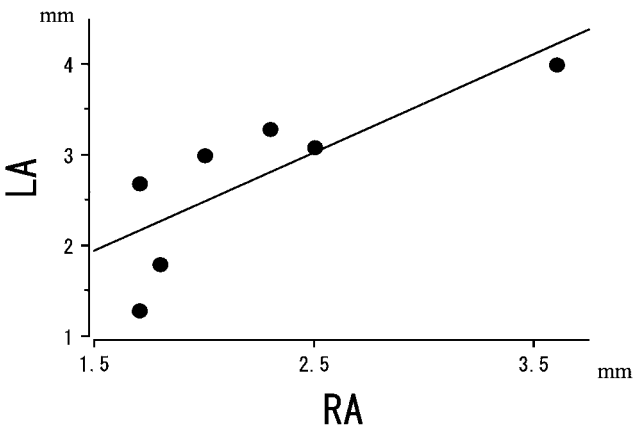

Fig. 2. Relationship between right and left atrial wall thickness.
LA=1.086×RA+0.322 (p=0.03)

Table 1. Atrial wall thickness and transmural coagulation

Atrial wall thickness (mm)	Transmural coagulation	
1-1.5	13/13	(100%)
2-2.5	13/19	(68%)
3-3.5	7/13	(54%)
4-4.5	2/4	(50%)
5-	0/2	(0%)
Total	35/51	(69%)

Table 2. Ablation time / atrial wall thickness and transmural coagulation

	Atrial wall thickness		
Ablation time	-2.5 mm	3.0 mm-	Total
<30 seconds	14/19 (74%)	9/18 (50%)	64%
≥60 seconds	12/13 (92%)	0/1	86%

Table 3. Histopathological results in both atria

Coagulation	Right atrium (n=33)	Left atrium (n=18)	Total (n=51)
100%	76%	56%	69%
90%	21%	22%	21%
<80%	3%	22%	10%

≥60 seconds. The percentage of transmural coagulation decreased in specimens with over 3 mm in wall thickness (Table 2). Transmural coagulation was obtained in 76% of the right atrium and 56% of the left atrium. Ninety percent coagulation was obtained equally in both the right atrium and in the left atrium (21% vs. 22%). A percentage of 90% or greater coagulation was significantly higher in the right atrium than in the left one (97% vs. 78%, $p<0.05$) (Table 3). As a complication of RFA, right atrial rupture occurred in a region of 1 mm in thickness after 60 seconds ablation. Thrombus formation on the endocardial wall was noted in 26% of all specimens.

Discussion

After the pioneering work done by Dr. James Cox, i.e., the Maze procedure,[4] surgical treatment for AF is now poised for a second breakthrough, including the so called, minimally invasive procedures. Intraoperative RFA is an effective procedure and favorable results have been reported even in long-term follow-up.[5,6] Before starting the RFA procedure, we had used a modified Maze procedure with cryoablation. The greatest benefits of RFA seem to be safety and time effectiveness. The major advantage of intraoperative RFA is the application of an epicardial approach. The efficacy of epicardial RFA following an arrested heart has already been reported.[7] The future direction of RFA should be directed at the possibility of epicardial RFA during heart beating. This might extend to application of endoscopic surgery. The possibility of RFA during surgery involving a beating heart has already been discussed,[8,9] however, the protocol has not yet been established.

There are two major problems in epicardial RFA on a beating heart; one is the cooling effect induced by the intracardiac blood flow and the other is the difficulty in establishing sufficient probe contact. We addressed the latter problems by using original adaptors, however, 90% coagulation, except for endocardium, was noted in approximately 20% of the specimens of both atria. As a result, we believe that an appropriate time setting is indispensable relative to both the thickness of the atrial wall and to the unavoidable cooling effect of the intracardiac blood flow. The wall thickness of the left atrium was slightly larger than that of the right atrium, however the differences were not significant. The percentage of transmural coagulation was lower in the left atrium than in the right atrium, probably indicating the difficulty in the epicardial RFA procedure itself including the energy blockage by epicardial fat pads. Santiago and his colleagues[10] reported that both the thickness and the composition of the epicardium and also of the myocardium are major determinants in the formation of the lesion. These finding were similar to our results. Transmural coagulation is obviously ideal for achieving complete electrical blockage. However, we think it's still controversial if transmural coagulation is always indispensable for electrical blockage. Particularly in lesions of 90% coagulation not involving intima, further electrical research is necessary.

In Japan, only the non-irrigation type Cobra™ surgical probe is currently commercially available. We do not plan to carry out this heart-beating procedure using this non-irrigation type Cobra™ surgical probe because we think, to date an ablation procedure on the arrested heart is a better procedure for obtaining high success rates. In this study we used a Cobra Cooled™ surgical probe to shorten ablation time because it's indispensable to obtain transmural coagulation within a short time when treating a beating heart. The basic premise of cooled ablation systems is to cool the tissue-electrode interface. This system circulates saline within the probe, removing some of the

heat within the coils and the plastic. This reduces the potential for very high temperatures, which may produce char, coagulation, or popping. Char and coagulum act as insulator and can reduce current delivered to tissue. By cooling the tissue-electrode interface, greater power can be delivered to tissue over time, resulting in larger and deeper lesions. In addition to the unipolar RFA probe, new instruments such as a new argon cryocatheter,[11] a microwave catheter,[12] a bipolar RFA catheter[13] have been introduced in the United States and European countries. Bonanomi and his colleagues reported good experimental results using a bipolar RFA probe for a beating heart.[14] Video-assisted procedure in nonmitral cases using cryoablation has already been reported.[15] In conclusion, there are notable and significant problems to be solved in order to establish the professional protocol for epicardial RFA procedures during treatment of a beating heart. Thus, further technical improvements associated with these new instruments are critical to their success.

References

1. Sonmez B, Demirsoy E, Yagan N, et al. A fatal complication due to radiofrequency ablation for atrial fibrillation: atrio-esophageal fistula. *Ann Thorac Surg* 2003; **76**: 281–3.
2. Doll N, Borger MA, Fabricius A, et al. Esophageal perforation during left atrial radiofrequency ablation: is the risk too high? *J Thorac Cardiovasc Surg* 2003; **125**: 836–42.
3. Fayad G, Modine T, Tourneau TL, et al. Circumflex artery stenosis induced by intraoperative radiofrequency ablation. *Ann Thorac Surg* 2003; **76**: 1291–3.
4. Cox JL, Jaquiss RD, Schuessler RB, Boineau JP. Modification of the maze procedure for atrial flutter and atrial fibrillation. II. Surgical technique of the Maze III procedure. *J Thorac Cardiovasc Surg* 1995; **110**: 485–95.
5. Sie HT, Beukema WP, Elvan A, Misier ARR. Long-term results of irrigated radiofrequency modified maze procedure in 200 patients with concomitant cardiac surgery: six years experience. *Ann Thorac Surg* 2004; **77**: 512–7.
6. Chiappini B, Martìn-Suàrez S, LoForte A, Arpesella G, Bartolomeo RD, Marinelli G. Cox/Maze III operation versus radiofrequency ablation for the surgical treatment of atrial fibrillation: a comparative study. *Ann Thorac Surg* 2004; **77**: 87–92.
7. Raman JS, Ishikawa S, Power JM. Epicardial radiofrequency ablation of both atria in the treatment of atrial fibrillation: experience in patients. *Ann Thorac Surg* 2002; **74**: 1506–9.
8. Melo J, Adragao P, Neves J, et al. Endocardial and epicardial radiofrequency ablation in the treatment of atrial fibrillation with a new intra-operative device. *Eur J Cardiothorac Surg* 2000; **18**: 182–6.
9. Mazzitelli D, Park CH, Park KY, Benetti FJ, Lange R. Epicardial ablation of atrial fibrillation on the beating heart without cardiopulmonary bypass. *Ann Thorac Surg* 2002; **73**: 320–1.
10. Santiago T, Melo J, Gouveia RH, et al. Epicardial radiofrequency applications: in vitro and in vivo studies on human atrial myocardium. *Eur J Cardiothorac Surg* 2003; **24**: 481–6.
11. Doll N, Kiaii BB, Fabricius AM, et al. Intraoperative left atrial ablation (for atrial fibrillation) using a new argon cryocatheter: early clinical experience. *Ann Thorac Surg* 2003; **76**: 1711–5.
12. Williams MR, Knaut M, Berube D, Oz MC. Application of microwave energy in cardiac tissue ablation: from in vitro analysis to clinical use. *Ann Thorac Surg* 2002; **74**: 1500–5.
13. Prasad SM, Maniar HS, Diodato MD, Schuessler RB, Damiano RJ. Physiological consequences of bipolar radiofrequency energy on the atria and pulmonary veins: a chronic animal study. *Ann Thorac Surg* 2003; **76**: 836–42.
14. Bonanomi G, Schwartzman D, Francischelli D, Hebsgaard K, Zenati MA. A new device for beating heart bipolar radiofrequency atrial ablation. *J Thorac Cardiovasc Surg* 2003; **126**: 1859–66.
15. Ohtsuka T, Kubota H, Suematsu Y, Motomura N, Takamoto S. Video-assisted transseptal cryoablation of left atrium in nonmitral cases. *J Thorac Cardiovasc Surg* 2003; **125**: 1537–8.