Case Report

Node Dissection for Solitary Interlobar Node Metastasis from Renal Cell Carcinoma by VATS

Atsushi Watanabe, MD, Hisayoshi Ohsawa, MD, Takuro Obama, MD,
Tohru Mawatari, MD, and Tomio Abe, MD

We present an unusual case of a patient with a right pulmonary interlobar node metastasis from renal cell carcinoma following nephrectomy. She underwent interlobar node dissection (ND) by video-assisted thoracoscopic surgery (VATS). Interlobar ND without lobectomy by VATS has not been reported until now in English literature. The retraction of the right intermediate bronchus is a useful technique during this procedure. (Ann Thorac Cardiovasc Surg 2005; 11: 38–40)

Key words: lymph node dissection, interlobar node, renal cell carcinoma, metastatic node, video-assisted thoracoscopic surgery

Introduction

Cases of solitary interlobar node metastasis from renal cell carcinoma (RCC) are very rare. The node metastases were mainly in the retroperitoneal space and mediastinum. The treatment for metastatic RCC remains controversial, although immunotherapy[1)] or surgical resection is considered to be the first choice in therapy. We think that a metastasectomy is valuable if the metastatic lesions are resected completely, and it is better if the procedure is minimally invasive. We present an unusual case of a patient with a right pulmonary interlobar node metastasis from RCC, who underwent interlobar node dissection (ND) by video-assisted thoracoscopic surgery (VATS). Interlobar ND without lobectomy by VATS has never been previously reported in English literature, and we present here the first case.

Case Report

A 56-year-old woman was referred for evaluation of a right interlobar mass. She had undergone left nephrectomy for RCC (clear cell carcinoma) in 1989, a right upper partial nephrectomy for recurrence of RCC in 1996, and partial resection of pancreatic tail and body and a splenectomy for recurrence in 2003. Although immunotherapy (subcutaneous administration of interferon alpha) was performed between June 2003 and January 2004, it was not effective. Chest computed tomography (CT) showed an interlobar mass (10×10 mm) between the right upper lobe and right middle lobe in June 2003. The node increased in size to 25×25 mm on chest CT in January 2004 (Fig. 1). Further examination revealed no abnormalities in the other organs and tissue including lung fields. It was suspected she had solitary interlobar node metastases from RCC, so we scheduled a pulmonary interlobar ND by VATS for definitive diagnosis and treatment.

Selective ventilation was performed using a double lumen endotracheal tube. Two access ports were made on the anterior axillary line in the 7th intercostal space (ICS) and on the posterior axillary line in the 8th ICS. A 40 mm-minithoracotomy was made in the 5th ICS. Interlobulation between the right upper lobe and right lower lobe was partially incomplete, so fissure-making was performed by the use of an endoscopic liner stapler (Endo-GIA, United States Surgical Corp., Norwalk). The right main bronchus, right upper lobe bronchus and intermediate bronchus (IMB) were exposed. The right IMB was taped following dissection of the IMB from surrounding tissue and retracted posterolaterally allowing enlargement of the angle that was made in the right upper bronchus and IMB. After the retraction, the thoracoscopic view

From Department of Thoracic and Cardiovascular Surgery, Sapporo Medical University School of Medicine, Hokkaido, Japan

Received June 21, 2004; accepted for publication August 30, 2004.
Address reprint requests to Atsushi Watanabe, MD: Department of Thoracic and Cardiovascular Surgery, Sapporo Medical University School of Medicine, South 1, West 16, Chuo-ku, Sapporo, Hokkaido 060-8543, Japan.

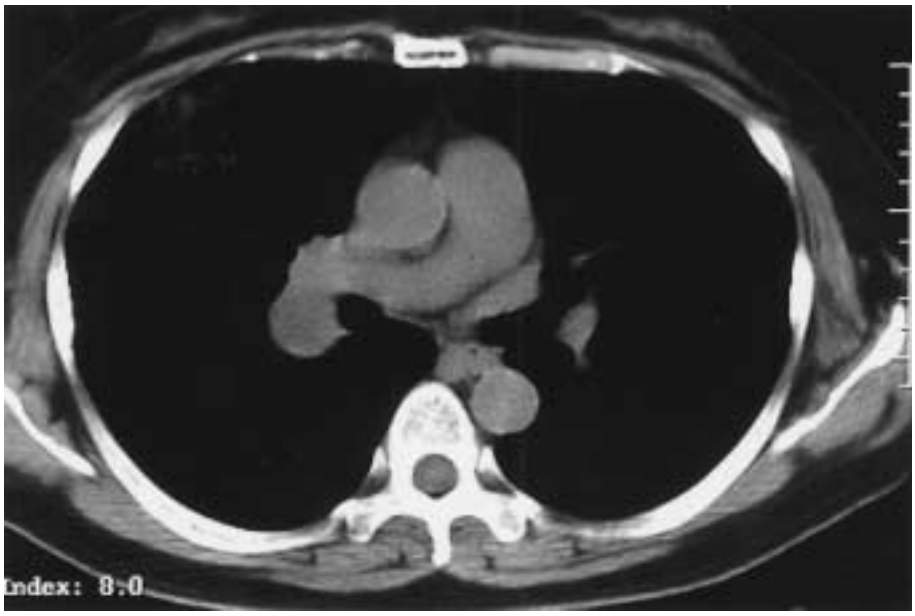

Fig. 1. CT showing a round mass 25 mm in diameter in the right upper interlobar area.

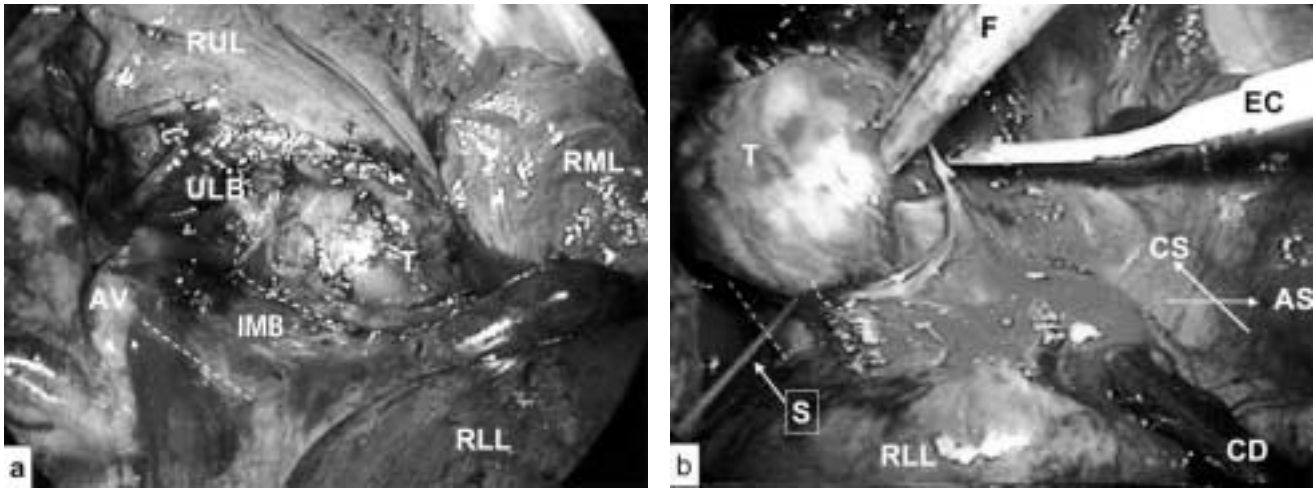

Fig. 2. Intraoperative thoracoscopic view.
a: Posterior view; b: Interlobar view
Dotted lines showing bronchial edge. RUL, Right upper lobe; RML, Right middle lobe; RLL, Right lower lobe; ULB, Upper lobe bronchus; AV, Azygos vein; IMB, Intermediate bronchus; T, Tumor; F, Forceps; EC, Electrocautery; CS, Cranial side; AS, Anterior side; S, Suture for posterolateral retraction of IMB; CD, Cherry dissector (Ethicon, Cincinnati, OH).

was improved (Fig. 2). The swollen interlobar node was well encapsulated and touched (slightly adhered to) the lung parenchyma, the bronchi and pulmonary arteries. The node was dissected from them. Additionally, sampling of hilar, subcarinal, tracheobronchial, and paratracheal nodes was performed, but the upper and middle lobar bronchial nodes were not found. The postoperative course was uneventful and she was discharged on the 3rd postoperative day.

Pathological examination for the interlobar node resected confirmed metastases from RCC. The node was well encapsulated and malignant cells did not invade the capsule. The other nodes were free from metastatic malignancy. The patient is doing well, with no evidence of recurrence at 7 months postoperatively.

Discussion

Solitary interlobar masses are unusual except swollen nodes with metastasis from bronchogenic cancer, scle-

rosing hemangioma,[2] pleural mesothelioma[3] and primary unknown cancer.[4]

Although RCC has a high metastatic potential, solitary interlobar node metastasis without lung or mediastinal node metastasis is very rare. The metastatic route to the interlobar node still remains unclear. We suspect antegrade metastasis from occult lung metastatic lesions or retrograde metastasis from occult mediastinal node metastases. The spread to the mediastinal node occurs by extension from the retrocrural and para-aortic nodes into the thoracic duct and then by antegrade flow into the thoracic duct and its collaterals, with retrograde flow from these channels to the mediastinal nodes.[5]

In metastatic RCC, most conventional antineoplastic drugs and radiation therapy have yielded little or no efficacy. Immunotherapy has proved to be a new treatment in the therapy of advanced RCC.[1]

In this case, surgical resection was undertaken due to solitary nodal metastasis. Furthermore, ND by VATS is minimally invasive and causes little functional damage. Metastasectomy by usual VATS does not permit palpation of the lung. Thin-slice-high-resolution CT can reveal 2-3 mm diam. abnormal (occult) masses. Intraoperative manual palpation of the lung during metastasectomy is not always necessary if thin-slice-high-resolution CT and tumor localization were performed preoperatively. Hence we did not perform palpation of the lung during the procedure.

The dissection should be performed just along the bronchial wall from the posterior side as the posterior ascending artery or trunk of the right pulmonary artery might be injured if it was done from an interlobar aspect. At this time, retraction of the IMB to the posterolateral side enabled us to get a good thoracoscopic view and to perform dissection and removal of the interlobar node easily. In our case, we were able to dissect and remove the interlobar node mostly through the posterior approach. An interlobar approach will be required if the node is severely adhered to the pulmonary artery. In this situation, the trunk of the pulmonary artery should be taped at the proximal and distal sites of the ascending pulmonary artery to prevent bleeding due to pulmonary artery injury during the dissection.

Pulmonary interlobar ND without lobectomy by VATS is safe and minimally invasive if the node has not invaded the bronchi or pulmonary arteries.

References

1. Krejci KG, Markiewicz MA, Kwon ED. Immunotherapy for urological malignancies. *J Urol* 2004; **171**: 870–6.
2. Kim KH, Sul HJ, Kang DY. Sclerosing hemangioma with lymph node metastasis. *Yonsei Med J* 2003; **44**: 150–4.
3. Mannes GP, Gouw AS, Berendsen HH, Verhoeff AJ, Postmus PE. Mesothelioma presenting with pneumothorax and interlobar tumour. *Eur Respir J* 1991; **4**: 120–1.
4. Kawasaki H, Yoshida J, Yokose T, et al. Primary unknown cancer in pulmonary hilar lymph node with spontaneous transient regression: report of a case. *Jpn J Clin Oncol* 1998; **28**: 405–9.
5. Mahon TG, Libshitz HI. Mediastinal metastases of infradiaphragmatic malignancies. *Eur J Radiol* 1992; **15**: 130–4.