Case Report

Infective Endocarditis during Pregnancy: Report of a Case

Shigeaki Aoyagi, MD, Koji Akasu, MD, Mau Amako, MD, Kazuhiro Yoshikawa, MD, and Hidetsugu Hori, MD

A 23-year-old woman, gravida 1, para, 0, was transferred at 29 weeks and 2 days gestation for management of infective endocarditis (IE). Based on vegetations attached to the mitral valve by echocardiography and positive blood cultures for Streptococcus mitis, the diagnosis of IE was made at the referring hospital. On admission to our hospital, echocardiography demonstrated a large vegetation and prolapse of the mitral valve with severe valve regurgitation. The fetal heart rate was 140/min. Ultrasound examination demonstrated an appropriate for gestational age 1,350 g fetus in vertex presentation. The day after admission, her membrane ruptured spontaneously, and she delivered a male infant by caesarean section at 29 weeks and 3 days of gestation. On the 42nd day of hospitalization, the mitral valve was reconstructed by quadrangular resection of the posterior commissure and annuloplasy with a prosthetic ring. A histological examination of specimens of the resected leaflets indicated that IE was active. One year later, the patient delivered a healthy infant without any complications by a caesarean section. The latest Doppler study demonstrated trivial mitral regurgitation and a mitral valve area of 2.5 cm^2. (Ann Thorac Cardiovasc Surg 2005; 11: 51–4)

Key words: infective endocarditis, pregnancy, mitral regurgitation, mitral valve repair

Introduction

The incidence of infective endocarditis (IE) during pregnancy has been reported to be 0.006%[1] or 1 in 8,000 deliveries (0.0125%).[2] According to a recent collective study,[3] the calculated maternal and fetal mortality rates were 22.1% and 14.7%, respectively, in this condition, and heart diseases are the most important non-obstetric cause of maternal death during pregnancy, accounting for 10% of maternal deaths.[4] Although there have been several reports of postpartum IE, most likely secondary to incomplete antibiotic prophylaxis,[5,6] there is little in the literature on the management of pregnancy complicated by IE.

In this paper, we report a case of acute mitral regurgitation (MR) resulting from IE occurring in a pregnant woman, and discuss the clinical management of IE during pregnancy.

From Department of Surgery, Kurume University School of Medicine, Kurume, Japan

Received June 11, 2004; accepted for publication August 9, 2004.
Address reprint requests to Shigeaki Aoyagi, MD: Department of Surgery (2), Kurume University School of Medicine, 67 Asahi-machi, Kurume, Fukuoka 830-0011, Japan.

Case Report

A 23-year-old woman, gravida 1, para, 0, was transferred at 29 weeks and 2 days gestation for management of IE after the diagnosis of IE was made at the referring hospital. The pregnancy had been uncomplicated until 17 days prior to the transfer, when the patient complained of fever and general fatigue. Her past history was not significant for congenital and valvular abnormalities including mitral valve prolapse. On admission to the referring hospital, the diagnosis of urinary tract infection was made based on findings of positive urinalysis, and antibiotic therapy with aminobenzylpenicillin (1 g/day) was begun. Despite intravenous antibiotic therapy, the patient's temperature remained above 39.0˚C with shaking chills. Ten days later, an apical systolic murmur was first noticed. Echocardiography showed massive MR and vegetations

Fig. 1. A transthoracic echocardiogram showing a large vegetation attached to the mitral valve (left panel), and a transesophageal echocardiogram showing prolapse of the posterior leaflet of the mitral valve (right panel).

attached to the mitral valve. Blood cultures were positive for Streptococcus mitis.

On admission to our hospital, her vital signs included temperature of 36.8˚C, a pulse rate of 90/min, and a blood pressure of 102/60 mmHg. On physical examination, she was slightly anemic and dyspneic. Examination of the chest showed a grade 4 systolic murmur at the apex but no ràles on the lung fields. Hemoglobin content was 8.9 g/dl and white blood cell count was 7,600/mm^3 with a left shift. C-reactive protein (CRP) was 6.77 mg/dl. The chest X-ray revealed moderate cardiomegaly (a cardiothoracic ratio of 67%). The electrocardiogram showed sinus tachycardia without specific ST and T-wave changes. Echocardiography demonstrated a large vegetation (1.7 cm in size) and prolapse of the mitral valve with severe valve regurgitation, as shown in Fig. 1. Following the diagnosis of streptococcal IE, the patient was placed on antibiotic therapy with penicillin G (1,800×10^4 units/day). The fetal heart rate was 140/min. Ultrasound examination revealed an appropriate for gestational age 1,350 g fetus in vertex presentation. The day after admission, her membrane ruptured spontaneously, and she delivered a 1,396 g male infant with APGAR scores of 6 and 7 at 1 and 5 min, respectively, by caesarean section at 29 weeks and 3 days of gestation. After the caesarean section, the patient continued to experience tachycardia, fever of 37-38˚C, and elevation of CRP, despite intravenous antibiotic therapy with a combination of penicillin G (2,400×10^4 units/day) and gentamycin (120 mg/day). Repeated blood cultures were continuously negative. On the 42nd day of hospitalization, the patient underwent surgical mitral valve repair as well as repair of a previously undiagnosed patent foramen ovale because of the patient's strong desire to have one more child. Consequently, antibiotic therapy was maintained for 7 weeks preoperatively but low grade fever and elevated CRP did not return to normal range. During surgery, vegetations and torn chordae with prolapse of the posterior commissure were observed but no extravalvular extension of IE was found (Fig. 2). After quadrangular resection of the posterior commissure, the mitral valve was reconstructed by a primary suture of the free edges of the remaining leaflets and annuloplasy with a prosthetic ring. The patient recovered uneventfully. Antibiotic therapy was maintained for 13 days after the operation. Postoperative echocardiography revealed no mitral valve regurgitation. A histological examination of specimens of the resected leaflets indicated that IE was active.

The neonate required mechanical ventilation during 2 weeks after birth because of severe respiratory distress syndrome and patent ductus arteriosus was successfully treated with indometacin on day 3 of life. Ultimately, the neonate was discharged home on day 78 of life at a weight of 2,564 g.

One year later, the patient delivered another healthy infant without any complications by a caesarean section, and she is doing well at present 3 years after cardiac surgery. The latest Doppler study demonstrated trivial MR

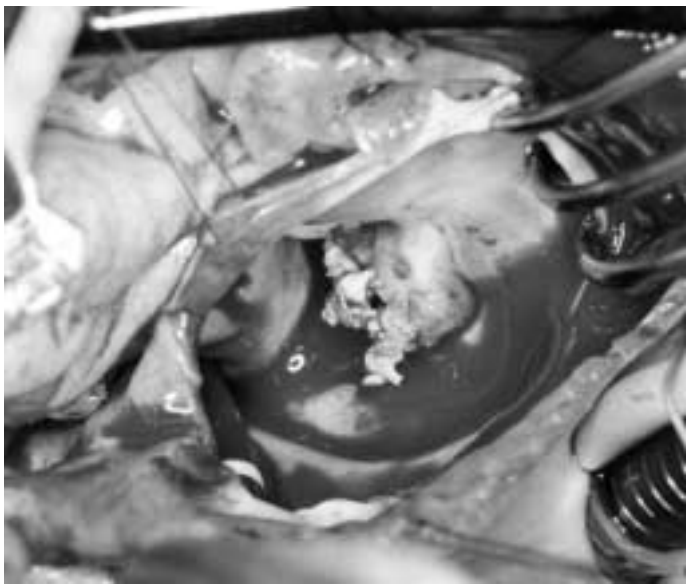

Fig. 2. An operative photograph showing prolapse of the posterior commissure of the mitral valve and vegetations attached to the valve.

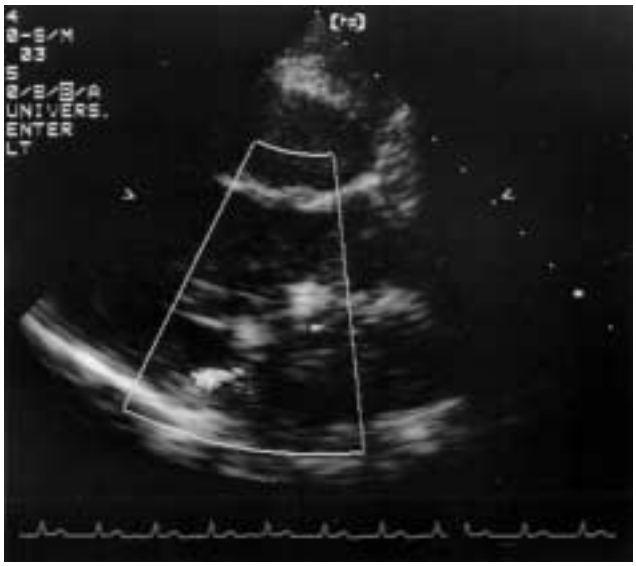

Fig. 3. A transthoracic Doppler echocardiogram showing trivial residual mitral regurgitation.

and a mitral valve area of 2.5 cm^2 (Fig. 3).

Discussion

IE is a rare but life-threatening complication of pregnancy. Over the past three decades, however, improved medical and surgical management of pregnant patients with heart disease has greatly reduced the maternal and fetal mortality rates, and the most recent collective study has indicated overall maternal and fetal mortality rates of 22.1% and 14.7%, respectively, in pregnant patients with IE.[3] In clinical management of pregnant patients with IE, the most important issue is to save the maternal and fetal lives. To minimize the maternal and fetal risks, the first choice of treatment should be medical, however, in cases that are refractory to medical treatment, corrective cardiac operations are unavoidable. While some cases of successful open-heart operations with cardiopulmonary bypass (CPB) have been reported,[7] congenital malformations possibly resulting from drug administration and CPB have been common when CPB is performed during the first trimester.[8,9] Considering these facts, a cardiac operation is not recommended except in extreme emergencies during the first two trimesters.[10] On the other hand, since a report by Zitnik and colleagues,[9] many reports of fetal survival to term after operations with CPB performed in the second and third trimesters, particularly between 24 and 28 weeks of gestation after organogenesis, have been described.[11] Furthermore, recent improvements in neonatal care have improved the survival of premature infants of greater than 28 weeks gestation. For these reasons, elective delivery by caesarean section just before CPB (after heparinization and cannulation of the mother but before commencing CPB) in the third trimester has been advocated for minimizing maternal and fetal risks.[10] In this patient, we preferred to perform delivery before valve surgery because of spontaneous rupture of the membrane at 29 weeks and 3 days of gestation and hemodynamic condition responding to medical treatment.

At present, mitral valve replacement (MVR) with a prosthetic valve is, generally, a standard surgical proce-

dure for active IE of the mitral valve. However, better operative results and lower incidence of valve-related complications have been recently demonstrated in mitral valve reconstruction as compared with those of MVR, even in patients with acute IE.[12-14] Sternik and colleagues[14] compared operative results of mitral valve (MV) repair with those of MVR in 44 patients with MR resulting from acute IE, and showed that patients undergoing repair had a significantly lower risk of in-hospital mortality (MVR; 21%, MV repair 0%), late cardiac death (MVR; 21%, MV repair; 0%), and reoperation (MVR; 5 patients, MV repair; 0 patients) compared with those receiving MVR. In surgical experience of 40 patients with active IE, Dreyfus and colleagues[12] performed MV repair within 1 week of adequate antibiotic therapy regardless of positive blood cultures to lower surgical mortality, and emphasized that no recurrence of IE or reoperation for MR were observed. Based on these data, they concluded that valve repair is not only feasible but also safer than valve replacement in the early stage of IE because it avoids use of prosthetic materials. Both studies indicated that the only limiting factor of valve repair would be the near-total destruction of the leaflets or subvalvular apparatus in patients with mitral IE, rather than other abnormalities such as vegetation, annular abscess, or chordae tendineae rupture.

In summary, we experienced active mitral IE occurring in a pregnant woman, and performed successful mitral valve repair 42 days after delivery by a caesarean section at 29 weeks and 3 days of gestation.

References

1. Cox SM, Hankins GDV, Leveno KJ, Cunningham FG. Bacterial endocarditis: a serious pregnancy complication. *J Reprod Med* 1988; **33**: 671–4.
2. Nazarian M, McCullough GH, Fielder DL. Bacterial endocarditis in pregnancy: successful surgical correction. *J Thorac Cardiovasc Surg* 1976; **71**: 880–3.
3. Campuzano K, Roquè H, Bolnick A, Leo MV, Campbell WA. Bacterial endocarditis complicating pregnancy: case report and systemic review of the literature. *Arch Gynecol Obstet* 2003; **268**: 251–5.
4. Montoya ME, Karnath BM, Ahmad M. Endocarditis during pregnancy. *South Med J* 2003; **96**: 1156–7.
5. Kangavari S, Collins J, Cercek B, Atar S, Siegel R. Tricuspid valve group B streptococcal endocarditis after an elective termination of pregnancy. *Clin Cardiol* 2000; **23**: 301–3.
6. Sexton DJ, Rockson SG, Hempling RE, Cathey CW. Pregnancy-associated group B streptococcal endocarditis: a report of two fatal cases. *Obstet Gynecol* 1985; **66**(Suppl 3): 44S–7S.
7. Becker RM. Intracardiac surgery in pregnant women. *Ann Thorac Surg* 1983; **36**: 453–8.
8. Lapiedra OJ, Bernal JM, Ninot S, Gonzalez I, Pastor E, Miralles PJ. Open heart surgery for thrombosis of a prosthetic mitral valve during pregnancy: fetal hydrocephalus. *J Cardiovasc Surg* 1986; **27**: 217–20.
9. Zitnik RS, Brandenburg RO, Sheldon R, Wallace RB. Pregnancy and open-heart surgery. *Circulation* 1969; **39**(Suppl 1): 257–62.
10. Parry AJ, Westaby S. Cardiopulmonary bypass during pregnancy. *Ann Thorac Surg* 1996; **61**: 1865–9.
11. Mahli A, Izdes S, Coskun D. Cardiac operations during pregnancy: review of factors influencing fetal outcome. *Ann Thorac Surg* 2000; **69**: 1622–6.
12. Dreyfus G, Serraf A, Jebara VA, et al. Valve repair in acute endocarditis. *Ann Thorac Surg* 1990; **49**: 706–13.
13. Podesser BK, Rödler S, Hahn R, et al. Mid-term follow up of mitral valve reconstruction due to active infective endocarditis. *J Heart Valve Dis* 2000; **9**: 335–40.
14. Sternik L, Zehr KJ, Orszulak TA, Mullany CJ, Daly RC, Schaff HV. The advantage of repair of mitral valve in acute endocarditis. *J Heart Valve Dis* 2002; **11**: 91–8.