Case Report

Re-do Mitral Valve Replacement Using the Valve-on-valve Technique: A Case Report

Yamato Tamura, MD, Tetsuji Kawata, MD, Yoichi Kameda, MD, and Shigeki, Taniguchi, MD

We report a repeated mitral valve replacement (re-do MVR) using the valve-on-valve technique for a degenerated bioprosthesis. A 49-year-old female, who had had a 29 mm Carpentier-Edwards mitral bioprosthesis for mitral regurgitation 20 years previously, was referred to our institution for dyspnea. She presented with pulmonary edema secondary to severe mitral bioprosthetic valve regurgitation. We replaced the degenerated mitral bioprosthesis with a 25 mm mechanical prosthesis using the valve-on-valve technique, as the struts of the bioprosthesis were embedded in the left ventricular myocardium.

Removal of the bioprosthesis may be not only time-consuming but also complicated by cardiac rupture at the atrioventricular junction or the posterior left ventricular wall. The valve-on-valve technique is a simplified procedure that can avoid the potential complications of complete excision of the bioprosthesis. We believe this technique can be a useful strategy for patients with a degenerated mitral bioprosthesis. (Ann Thorac Cardiovasc Surg 2005; 11: 125–7)

Key words: valve-on-valve technique, re-do mitral valve replacement

Introduction

Complete removal of a defective mitral bioprosthesis may be sometimes technically difficult and may cause damage to the native atrioventricular structure. This can occur when a prosthetic valve strut is buried into the myocardium of the left ventricle, when there is calcification of the tissue ingrowth into the bioprosthetic annulus, or when an oversized valve has been implanted into the mitral annulus denuded of fibrous periannular tissue. Use of the valve-on-valve technique, which was reported by Stassano in 1993, in which a mechanical prosthesis is implanted on the bioprosthetic annulus, avoids such difficulties.[1)]

From Department of Thoracic and Cardiovascular Surgery, Nara Medical University School of Medicine, Nara, Japan

Received October 25, 2004; accepted for publication November 9, 2004.
Address reprint requests to Yamato Tamura, MD: Department of Thoracic and Cardiovascular Surgery, Nara Medical University School of Medicine, 840 Shijo-cho, Kashihara, Nara 634-8522, Japan.

Case Report

A 49-year-old female was referred to our hospital with severe dyspnea. She had a history of mitral valve replacement (MVR) using a 29 mm Carpentier-Edwards bioprosthesis (Edwards Lifesciences, Irvine, CA) for mitral regurgitation 20 years previously.

She presented with pulmonary edema and bilateral pleural effusions on chest X-ray, secondary to severe mitral bioprosthetic valve regurgitation (Fig. 1). Color Doppler echocardiography demonstrated a tear in a cusp due to degenerative changes in the mitral bioprosthesis without perivalvular leakage (Fig. 2). Cardiac catheterization demonstrated a pulmonary arterial pressure of 65/35 (mean 45) mmHg, and severe mitral regurgitation, and moderate tricuspid regurgitation.

The surgery was carried out through a repeated median sternotomy. Cardiopulmonary bypass (CPB) was established with ascending aortic perfusion and bicaval drainage. Intermittent antegrade and retrograde infusion of cold cardioplegia was used for myocardial protection. Exposure of the mitral bioprosthesis was achieved through a transseptal approach. The mitral bioprosthesis was ex-

Fig. 1. Preoperative chest X-ray demonstrated cardiac enlargement with a cardiothoracic ratio of 0.65, and bilateral pleural effusion.

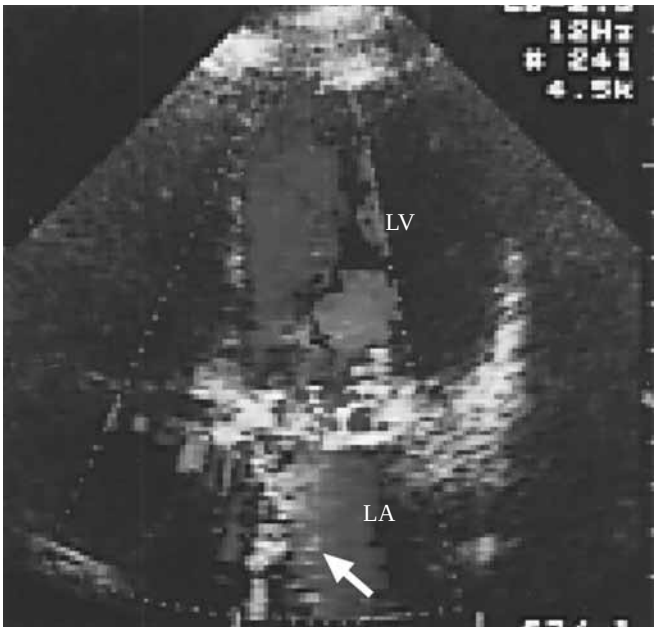

Fig. 2. Preoperative echocardiogram showed severe mitral regurgitation due to degenerative changes in the mitral bioprosthesis, and absence of perivalvular leakage (arrow).

tensively covered by neoendocardium and its struts were deeply embedded into the ventricular wall. Only the leaflets of the bioprosthesis were resected with a knife blade, and a new 25 mm mechanical prosthesis (St. Jude Medical [SJM]; SJM, Inc, St. Paul, MN) was sewn onto the old bioprosthetic ring. Mattress sutures with 2-0 polyester were placed through the sewing ring of the mitral bioprosthesis and subsequently passed through the sewing ring of the mechanical prosthesis, which was oriented in an antianatomical position. Associated procedures included tricuspid valve annuloplasty with a 28 mm Cosgrove-Edwards band (Edwards Lifesciences, Irvine, CA). The patient was easily weaned from CPB.

Postoperative recovery was uneventful. Echocardiography confirmed normal seating of the mechanical prosthesis, no abnormal movements of the leaflets, no significant gradient across the prosthesis, and no perivalvular leakage. The patient was discharged on the 25th postoperative day and is doing well at 12 months of follow-up on a regimen of oral antiplatelet drugs.

Discussion

Although several pathologies might result on the need for reoperation in patients with previously implanted cardiac bioprostheses, one of the most common is structural failure. In such cases, the bioprosthetic leaflets are usually torn and partially calcified, with the struts buried in the myocardium. Explantation of the bioprosthesis is time-consuming and may be complicated by cardiac rupture at the atrioventricular junction or at the posterior left ventricular wall, by injury to the circumflex coronary artery, or by late perivalvular leakage.[2,3]

The valve-on-valve technique is a surgical option for replacement of a degenerated bioprosthesis with a mechanical bileaflet prosthesis. Only the degenerated tissue is excised, leaving the stent and supporting structure of the bioprosthesis intact; a new mechanical prosthesis is attached to the old bioprosthetic valve annulus (Fig. 3). This procedure is a simple technique that can avoid some of the complications associated with complete excision of the bioprosthesis.

From a technical point of view, a low profile mechanical bileaflet prosthesis is to be preferred, in order to avoid impingement of the disks on the bioprosthetic ring.[4] In our case, we implanted an SJM prosthetic valve because its leaflets are hinged on the atrial side and only slightly protrude into the ventricular side.

The optimum size of the new mechanical prosthesis can be determined from that of the previously implanted bioprosthesis. A new mechanical prosthesis must be one

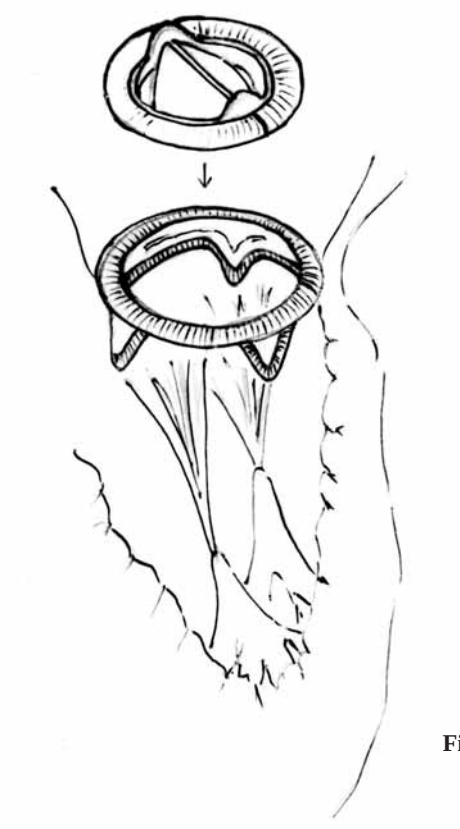

Fig. 3. Concept of the valve-on-valve technique. Only leaflet tissue is excised, and a mechanical prosthesis is attached to the old bioprosthetic valve annulus.

or two sizes smaller than the bioprosthesis in order to easily fit onto the bioprosthetic valve annulus.[3,4] In our case, we implanted a mechanical prosthesis that was two sizes smaller than the bioprosthetic valve, because we thought that a 25 mm mitral prosthesis was acceptable in a patient with a body surface area of 1.41 m^2. In fact, there was no significant pressure gradient by echocardiographic evaluation.

Conclusion

We performed re-do MVR using the valve-on-valve technique to replace a degenerated bioprosthesis. We believe this technique to be useful for patients with a degenerated mitral bioprosthesis in certain difficult situations.

References

1. Stassano P, Losi MA, Golino A, Gagliardi C, Iorio D, Marzullo M, Spampinato N. Bioprosthesis replacement with mechanical valve implantation on the bioprosthetic ring. *Eur J Cardiothorac Surg* 1993; **7**: 507–10.
2. Geha AS, Lee JH. Evolution of the surgical approach for replacement of degenerated mitral bioprostheses. *Surgery* 1995; **118**: 662–8.
3. Geha AS, Massad MG, Snow NJ. Replacement of degenerated mitral and aortic bioprostheses without explantation. *Ann Thorac Surg* 2001; **72**: 1509–14.
4. Stassano P, Musumei A, Losi MA, Gagliardi C, Spampinato N. Midterm results of the valve-on-valve technique for bioprosthetic failure. *Eur J Cardiothorac Surg* 2000; **18**: 453–7.