Case Report

Surgical Treatment of Methicillin-resistant Staphylococcus Aureus Infection Following Infrainguinal Arterial Reconstruction

Shinji Hirai, MD, Yoshiharu Hamanaka, MD, Norimasa Mitsui, MD, Masahiko Morifuji, MD, and Miwa Sutoh, MD

A 64-year-old man was referred to our hospital with Methicillin-resistant Staphylococcus aureus (MRSA) infection following infrainguinal arterial reconstruction. As repeated MRSA sepsis occured, we decided to remove the infected graft with distal revascularization via circuitous graft tunneling to avoid serious infections and allow limb salvage. An iliofemoro bypass was performed via an extra-anatomical bypass, from just below the iliac crest into the musculus quadriceps femoris using an 8 mm-ringed polyester gelatin polypropylene tube graft, with complete debridement of a groin infection. Postoperative 3-dimentional CT angiography revealed that the prostheses was patent and the patient had an uneventful postoperative course. We concluded that this extra-anatomical bypass was a safe procedure and an excellent option for patients with an infected vascular prosthetic graft in the groin after previous revascularization, like in our case with no available autogeneous vein grafts. (Ann Thorac Cardiovasc Surg 2005; 11: 139–41)

Key words: iliofemoro bypass, extra-anatomical bypass, vascular prosthetic graft infections, MRSA, inguinal wound infections

Introduction

The optimal management of vascular prosthetic graft infections in the groin remains controversial. We report a successful treatment for Methicillin-resistant Staphylococcus aureus (MRSA) infection following infrainguinal arterial reconstruction using the external iliac artery as an inflow source for a new extra-anatomical bypass from just below the iliac crest into the musculus quadriceps femoris.

Case Report

A 64-year-old man who had undergone percutaneous cardiopulmonary support (PCPS) using the left femoral artery and femoral vein for treatment of accidental hypothermia after being rescued from drowning was referred again to our hospital with wound infection of the left groin where the PCPS was inserted three weeks earlier. On removal of the PCPS the common femoral artery was exposed via a 5 cm skin incision to secure hemostasis. MRSA was cultured from the wound. In spite of continued administration of antibiotics and lavage with povidone iodine, emergency operations were performed three times due to massive bleeding from the infected common or superficial femoral arteries caused by wound infection. At the first and second such operations, patch-plasty of the common femoral artery with debridement of the groin infection was performed, using the saphenous vein graft (SVG) with wound debridement to stop bleeding, and debridement of the artery wall infection was also done. At the third surgery, an 8 mm-ringed polyester gelatin polypropylene tube graft was needed for reconstruction of the infected common and superficial femoral arteries. A SVG was used for reconstruction of the infected deep

From Department of Thoracic and Cardiovascular Surgery, Hiroshima Prefectural Hospital, Hiroshima, Japan

Received May 21, 2004; accepted for publication October 21, 2004.
Address reprint requests to Shinji Hirai, MD: Department of Thoracic and Cardiovascular Surgery, Hiroshima Prefectural Hospital, 1-5-54 Ujinakanda, Minami-ku, Hiroshima 734-8530, Japan.

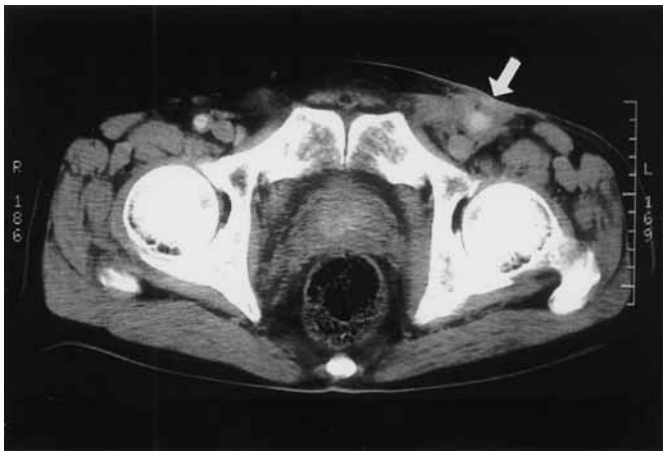

Fig. 1. The pelvic CT scan revealed the low density mass around an 8mm-ringed polyester gelatin polypropylene tube graft infection with a skin ulcer in the groin.

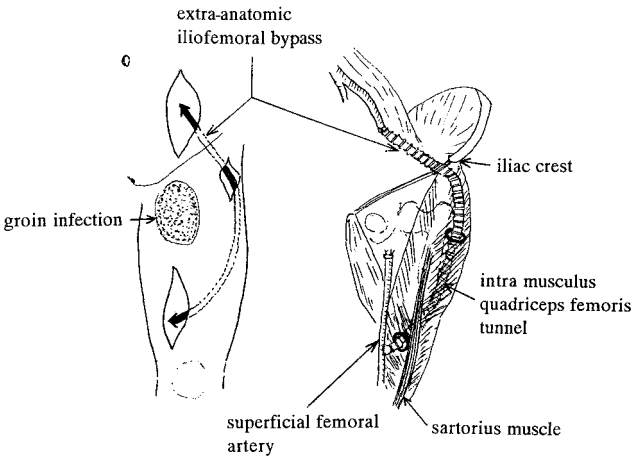

Fig. 2. After the external iliac artery was used as an inflow source via a retroperitoneal, the iliofemoro bypass passed through the lateral femoral muscle just below the iliac crest via a intra musculus quadriceps femoris tunnel to prevent a septic groin.

femoral artery. However, as a result of infection with treatment resistance, graft infection with a skin ulcer in the groin reoccurred (Fig. 1). As conservative wound debridement and drainage with antibiotic administration led to repeated MRSA sepsis, we decided to remove the infected graft with distal revascularization via circuitous graft tunneling to avoid serious infections and allow limb salvage. An iliofemoro bypass was performed via an extra-anatomical bypass, from just below the iliac crest into the musculus quadriceps femoris using an 8 mm-ringed polyester gelatin polypropylene tube graft, with complete debridement of the groin infection, and arterial reconstruction of the deep femoral artery was not undertaken (Fig. 2). Postoperative 3-dimentional CT angiography on the 64th postoperative day revealed that the prostheses was patent (Fig. 3). The patient had an uneventful postoperative course.

Disccusion

One of the most serious complications of vascular surgery is arterial prosthetic graft infection, occuring in approximately 1% of vascular surgical procedures.[1] It had been reported that the incidence of infrainguinal arterial prosthetic graft infection is 2.5%, the mortality rate is 17%, and that the amputation rate is 41%.[2] In particular, MRSA infection has a high mortality in vascular surgical patients when prosthetic grafts became infected. It had been reported that MRSA infection after infrainguinal bypass resulted in 29% mortality due to MRSA sepsis or anastomotic bleeding.[3]

Specific guidlines for management of inguinal wound infections after vascular graft placement have not been defined. Some reports described succesful eradication of infection with conservative wound debridement, drainage with antibiotic administration, and local muscle flap coverage even in the most extreme cases of hemorrhage and gram-negative sepsis.[4] However, we belive that those methods could be adequately administered only in superficial infections of the skin or subcutaneous tissue. We agree that complete excision of infected graft material results in a reduction in the recurrence rate of infection after reviewing the literature.[5,6] Excision of the infected graft alone, although effective for infections, may result in severe lower limb ischemia, and graft removal with distal revascularization for limb salvage via a circuitous graft tunneling to avoid serious infections should be performed to bypass a seriously infected groin involving a vascular graft, as in this case.

However, the operative procedure for graft removal with distal revascularization also varies, and there is controversy regarding the optimal management. It had been reported that the axillary, subclavian, common carotid, external iliac, or common iliac artery are useful for proximal anastomosis, and that the femoral, profunda femoris, popliteal above the knee or below the knee, or crural artery can function in distal anastomosis, and that autogeneous vein grafts would be a better form of treatment than vascular prosthetic grafts because of resistance to MRSA infection.[3,6,7] Recently, the obturator iliofemoral bypass had been reported as a good technique.[8,9] How-

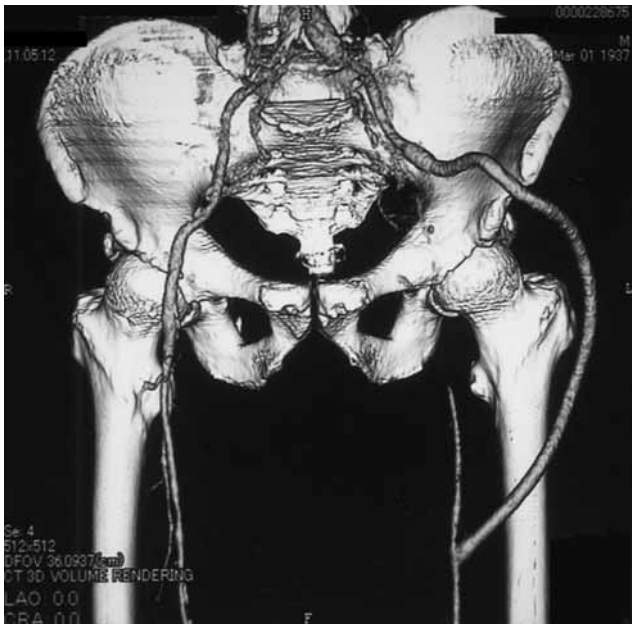

Fig. 3. Postoperative 3-dimentioned CT angiography revealed that the prostheses was patent.

ever, this approach might cause bleeding while the tunnel is being created in patients presenting with deep infection and active hemorrhage as in our case, which is difficult to control without groin dissection. Futhermore, if obturator bypass graft infection occured, it would be difficult to diagnose because of deep tissue infection. Delayed diagnosis could increase the amputation and mortality rates.

We believe our method of extra anatomic iliofemoral bypass to avoid a septic groin to be a useful therapeutic concept in a case such as ours where no vein was available because of use for previous revascularization. As shown in Fig. 2, the skin incision starting parallel to the lateral border of the rectus muscle above the inguinal ligament was extended for about 10 cm. The external iliac artery, which was exposed easily via a retroperitoneal approach, was used as an inflow source for redo bypass. This artery can be isolated and controlled with silicone rubber vessel loops. The second incision of about 3 cm was made in the lateral musculus quadriceps femoris just below the iliac crest. The third incision was made at the level of the medial border of the sartorius muscle for about 10 cm. The intra musculus quadriceps femoris tunnel connecting both incisions was safely and easily created by tunnelar to avoid the septic groin, using an 8 mm-ringed polyester gelatin polypropylene tube graft. After that procedure was done, complete excision of the infected graft and tissue was undertaken. Our procedure, which passed through the lateral femoral muscle to prevent a septic groin, offers a safe and simple technique because graft patency is good, despite the use of chronic anticoagulation therapy. We belive that this approach should be used preferentially to avoid the difficult and hazardous dissection of a groin previously operated on several times, as in our case with no available autogeneous vein grafts.

Conclusion

We concluded that this extra-anatomical bypass is a safe procedure and an excellent option for patients with infected prosthetic vascular grafts in the groin after previous revasculation.

References

1. Edwards WH Jr, Martin RS 3rd, Jenkins JM, Edwards WH Sr, Mulherin JL. Primary graft infections. *J Vasc Surg* 1987; **6**: 235–9.
2. Yeager RA, Porter JM. Arterial and prosthetic graft infection. *Ann Vasc Surg* 1992; **6**: 485–91.
3. Murphy GJ, Pararajasingam R, Nasim A, Dennis MJ, Sayers RD. Methicillin-resistant Staphylococcus aureus infection in vascular surgical patients. *Ann R Coll Surg Engl* 2001; **83**: 158–63.
4. Kimmel RM, Murphy RX Jr, Chowdary RP. Optimal management of inguinal vascular graft infections. *Ann Plast Surg* 1994; **32**: 623–9.
5. Mertens RA, O'Hara PJ, Hertzer NR, Krajewski LP, Beven EG. Surgical management of infrainguinal arterial prosthetic graft infections: review of a thirty-five-year experience. *J Vasc Surg* 1995; **21**: 782–91.
6. Taylor SM, Weatherford DA, Langan EM 3rd, Lokey JS. Outcomes in the management of vascular prosthetic graft infections confined to the groin: a reappraisal. *Ann Vasc Surg* 1996; **10**: 117–22.
7. Meyer T, Schweiger H, Lang W. Extraanatomic bypass in the treatment of prosthetic vascular graft infection manifesting in the groin. *Vasa* 1999; **28**: 283–8.
8. Ascer E, Kirwin J, Mohan C, Gennaro M. The preferential use of the external iliac artery as an inflow source for redo femoropopliteal and infrapopliteal bypass. *J Vasc Surg* 1993; **18**: 234–41.
9. Fujikura H, Masaki H, Morita I, et al. Obturator foramen bypass in the management of infectious groin complications following vascular surgery (in Japanese with English abstract). *Nihon Kekkangeka Gakkaizasshi (Jpn J Vasc Surg)* 2000; **9**: 471–7.