Original Article

Usefulness of Automatic Triangular Anastomosis for Esophageal Cancer Surgery Using a Linear Stapler (TA-30)

Yoshiyuki Furukawa, MD, Nobuyoshi Hanyu, MD, Katsuya Hirai, MD, Takuro Ushigome, MD, Naruo Kawasaki, MD, Youichi Toyama, MD, Tomoko Nakayoshi, MD, and Katsuhiko Yanaga, MD

In a clinical evaluation, thirty-one patients with thoracic esophageal cancer who were treated from 1997 to 2000 were selected as subjects including those who underwent hand sewn anastomosis method, circular stapler method and triangular anastomosis method. Incidence of anastomosis failure was 27.3%, 25.0% and 8.3% for the hand sewn anastomosis method, circular stapler method and triangular anastomosis method, respectively. Anastomosis stenosis was found in 32.4%, 45.6% and 8.3% for the hand sewn anastomosis method, circular stapler method and triangular anastomosis method, respectively.

In the basic examination, reduction rate of anastomosis caliber was 22.1±4.8%, 14.9±1.4% and 7.37±0.9%, for the hand sewn anastomosis method, circular stapler method and triangular anastomosis method. Microscopic evaluation revealed serious problems with the circular stapler method. The cause of anastomotic stenosis may include the fact that if anastomosis is performed by a circular stapler method, all the layers of gastrointestinal tract are punched out at the anastomosis portion, and mucosal conjugation is not observed and the muscular layer is exposed in the inner lumen of the gastrointestinal tract. Taking that the ulcer is formed circularly at the anastomotic portion into account, it is easily understood that this circular ulcer develops into stenosis in the healing process. The advantage of triangular anastomosis for esophago-gastric anastomosis is less suture failure, and is extremely advantageous for prevention of stenosis at the anastomotic portion when compared with other anastomosis methods. However, with regard to the healing process of eversion anastomosis in gastrointestinal tract instrumental anastomosis, detailed examination is expected hereafter. (Ann Thorac Cardiovasc Surg 2005; 11: 80–6)

Key words: esophageal cancer, esophago-gastric anastomosis, triangular anastomosis method, circular stapler method, linear stapler, hand sewn anastomosis method, anastomotic stenosis

Introduction

Instrumental anastomosis in the digestive surgery field has been extensively used due to its safety and simplicity. In esophageal cancer surgery, the instrumental anastomosis method appeared and it is considered to be a good indication for shortening of operation time and prevention of anastomosis failure.[1] Although, different from the reconstruction after total gastrectomy or low anterior resection for rectal cancer, even if instrumental anastomosis is performed for esophago-gastric anastomosis, the incidence of suture failure is not dramatically reduced and there remain some problems. In the case of instrumental anastomosis using a circular stapler method, if end to side anastomosis where the esophago-gastric anastomosis suturing instrument is inserted from the stump of the gastric tube is performed, the vascular net inside of the gastric wall is punched out by a staple, thus interruption in the circulation occurs at the tip of the gastric tube,

From Department of Surgery, Jikei University School of Medicine, Tokyo, Japan

Received September 1, 2004; accepted for publication December 20, 2004.
Address reprint requests to Yoshiyuki Furukawa, MD: Department of Surgery, Jikei University School of Medicine, 3-25-8 Nishi-shinbashi, Minato-ku, Tokyo 105-8461, Japan.

causing suture failure.[2] On the other hand, for performing end to end anastomosis, if the separated portion for producing the gastric tube is incised and the suture instrument is inserted, the sternum or clavicle becomes the obstacle, making it difficult to perform anastomosis. Furthermore, the most important problem in the control of patients after esophageal cancer surgery is swallowing dysfunction. Even the patients who underwent radical surgery of cancer and are expected to live long may die due to aspiration pneumonia after surgery. Since we have performed end to end anastomosis using automatic triangular anastomosis method and had excellent surgical results, our surgical technique and clinical results are reported. Usefulness of this triangular anastomosis method and basic experimental examination based on microscopic observation of the anastomosis in the removed bovine small bowel and the canine small bowel are also reported.

Surgical Technique, Subjects and Methods

1. Surgical technique

First, pull up the greater curvature of the gastric tube and anastomose the remaining esophagus and the gastric tube at the cervical region. Reconstruction approach can be the approach posterior to the sternum or posterior mediastinal approach. Then, apply 2-3 stitches of the supporting sutures to all the layers of the esophagus in the posterior wall and the gastric tube. Elevate these supporting sutures and perform anastomosis of the posterior wall using a linear stapler (TA-30). Great care should be taken to securely suture the mucosa and seromuscular layer, and perform posterior wall anastomosis which is shorter in length than the ordinary hand sewn suture. Elevate the portion between the supporting sutures using Allis forceps together with all the layers of esophagus in the posterior wall and the gastric tube, hence the supporting force is sustained and suture by a linear stapler can be facilitated (Fig. 1a). Staple using TA-30 and resect the remaining mucosa and seromuscular layer. Then, apply the supporting sutures to the left and right ends of the staple line on the sutured posterior wall, and perform anterior wall suture using a linear stapler so that it intersects with the staple line of the posterior wall (Fig. 1b). It is the most important point of this surgical technique that the staple lines are securely intersected. Apply the supporting sutures to the center of anterior wall, and elevate both this and the supporting sutures on the posterior wall staple, then staple using TA-30 (Fig. 1c). Suture everting the final side in the same manner (Fig. 1d). Finally, suture everting, making the anterior wall an isosceles triangle against the anastomosis line of the posterior wall, firing the TA-30 twice. As mentioned above, what is important is to staple so that both staple lines intersect mutually, and finally confirm that 3 sides of the knocked staple line intersect. In terms of results, 2/3 encircling eversion anastomosis composed of inversion for the posterior wall and eversion for the anterior wall should be performed.

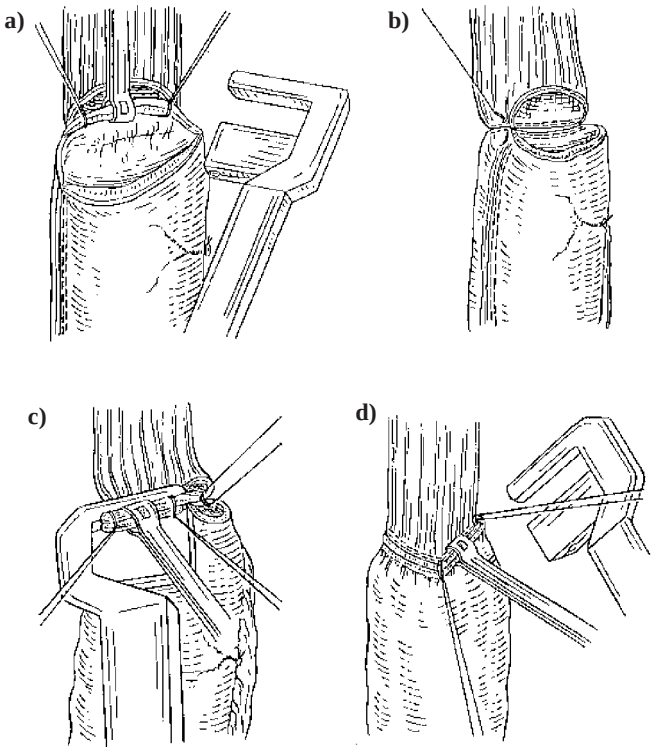

Fig. 1. Cervical esophagogastro-anastomosis using a linear stapler (TA-30).
a) Elevate the portion between two supporting sutures applied to the mucosa and muscularis using Allis forceps and staple it.
b) Apply supporting sutures to the right and left ends on the staple line of the sutured posterior wall, and perform anterior wall suture so that it intersects with the staple line of the posterior wall.
c) Suture everting the anterior wall to make an isosceles triangle.
d) Staple so that the both staple lines mutually intersect without fail, and finally confirm that 3 sides of the staple lines mutually intersect.

2. Clinical examination

Thirty-one patients with thoracic esophageal cancer who were treated from November 1997 to July 2000 were selected as subjects including hand sewn anastomosis method, circular stapler method and triangular anastomosis method in 11, 8, and 12 patients, respectively. Anastomosis time, incidence of anastomosis failure and inci-



Fig. 2. Experiment method for maximal pressure at the anastomotic part using removed bovine small bowel.
The anastomosed bowel was drawn into water, and the air was infused into it to examine pressure resistance at the anastomosis part.

dence of stenosis at the anastomotic portion were retrospectively compared. Hand sewn anastomosis method was performed as layer to layer anastomosis using 4-0 silk suture. Anastomosis by circular stapler method was performed by EEA 25 (Tyco Healthcare Co., Ltd.), and the stump of esophagus was treated with encircling suture using 3-0 proline, and anastomosis was performed after inserting the anvil.

a) Examination on anastomosis time
After the gastric tube was pulled up to the cervical portion, the time required for cervical esophago-gastric anastomosis was calculated based on the intraoperative nursing records.

b) Incidence of suture failure
Incidence of suture failure demonstrated in the postoperative course was retrospectively examined. Suture failure was examined including all failures from minor leakage to major leakage.

c) Incidence of stenosis at the anastomotic portion
Stenosis at the anastomotic portion is defined as stenosis which is endoscopically examined due to postoperative swallowing difficulty and is required to be endoscopically dilated by the balloon.

3. Basic examination
a) Examination on the removed bovine small bowel
For the removed bovine small bowel, the layer to layer hand sewn anastomosis method, instrumental anastomosis by EEA 25 and triangular anastomosis method by TA-30 were performed. After completion of end to end anastomosis, the air was infused and the shape of anastomosis was observed. Taking into consideration the technical skill of surgeons, examination was done by 4 surgeons who had experience of more than 10 years in digestive surgery, and anastomosis was performed 8 times in total. The following items were examined.

Maximal pressure resistance: The bowel was resected into a 5 cm piece in the longer diameter including the anastomotic portion treated by each anastomosis method. Both ends were ligated, and a tube for inner pressure measurement was inserted in the bowel, which was connected to an internal pressure meter and was drawn into the water. The air was infused into the bowel, and the pressure value where the anastomotic portion first ruptured was regarded as maximal pressure resistance at the anastomotic portion and was compared (Fig. 2).

Stenosis rate at the anastomotic portion: Anastomosis was circularly resected into a piece of about 5 mm length including the suture line at the anastomotic portion, and anastomosis caliber and anastomosis length were measured. Similarly, the healthy small intestine in the oral side was circularly resected into a piece of 5 mm length and the stenosis rate due to anastomosis against the circumference length of the healthy bowel was calculated in percentage.

b) Microscopic observation of the canine bowel anastomosis
For the canine small bowel, hand sewn anastomosis method, circular stapler method, and triangular anasto-



Fig. 3. Time required for esophago-gastric anastomosis
Anastomosis time for triangular anastomosis method was significantly shorter than that of the hand sewn anastomosis method.



Fig. 4. Incidence of anastomosis failure
Incidence of anastomosis failure was 27.3%, 25.0% and 8.3% for the hand sewn anastomosis method, circular stapler method and for the triangular anastomosis method, respectively.



Fig. 5. Incidence of stenosis in anastomosis site
Stenosis at the anastomotic site was 32.4%, 45.6% and 8.3% (1 patient) for the hand sewn anastomosis method, circular stapler method and for circular stapler method, respectively.

mosis method were performed. The anastomotic portion was removed 1 week after and stained with hematoxylin and eosin, and anastomosis situation was microscopically observed.

Results

1. Clinical examination

The mean time required for esophago-gastric anastomosis was 54.0±18, 34.9±9 and 24.0±11 min for the hand sewn method, circular stapler method and triangular anastomosis method, respectively. Clearly anastomosis time for the triangular anastomosis method was shorter than that for the hand sewn anastomosis method (Fig. 3).

Incidence of anastomosis failure was 27.3%, 25.0% and 8.3% for the hand sewn anastomosis method, circular stapler method and triangular anastomosis method, respectively (Fig. 4). Anastomosis which postoperatively developed swallowing dysfunction was endoscopically examined and in those of which it was judged necessary to perform balloon dilatation were defined as having stenosis at the anastomotic portion, which was found in 32.4%, 45.6% and 8.3% for the hand sewn anastomosis method, circular stapler method and triangular anastomosis method, respectively (Fig. 5).

2. Basic examination

a) Anastomosis of the removed bovine small bowel

Even when triangular anastomosis was performed using a linear stapler, the shape of anastomosis was almost circular (Fig. 6), and maximal pressure at the anastomotic portion was about 110 mmHg by any anastomosis method, showing no significant difference (Fig. 7).

The reduction rate of anastomosis caliber was 22.1±4.8%, 14.9±1.4% and 7.37±0.9%, the least stenosis for the hand sewn anastomosis method, circular stapler method and triangular anastomosis method (Fig. 8).

b) Microscopic observation of the anastomotic portion of the canine small bowel

Continuity of mucosa at the anastomotic portion was sustained 1 week after surgery by the hand sewn anastomosis method or triangular anastomosis method, whereas by the circular stapler method, all the layers of the anastomosed bowel were severed at the same time when stapled, thus union of the muscularis was exposed in the bowel and was found that the mucosa had not been sutured (Fig. 9).

Discussion

Since the automatic esophagogastro suturing instrument has been advanced and improved, it has extensively applied to the esophageal surgery field, aiming for shorten-

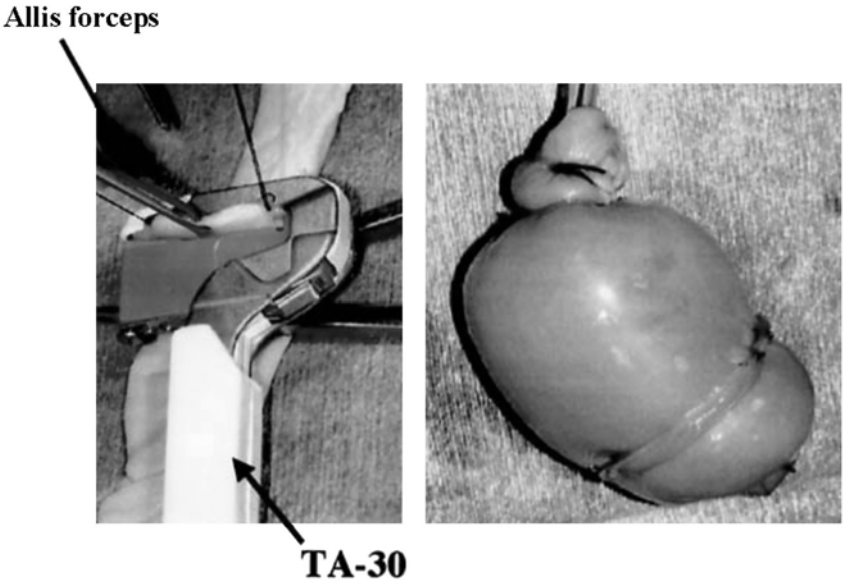

Fig. 6. The shape of anastomosis of the removed bovine bowel by triangular method. Even if triangular anastomosis is performed, the shape of the anastomosis is almost circular.

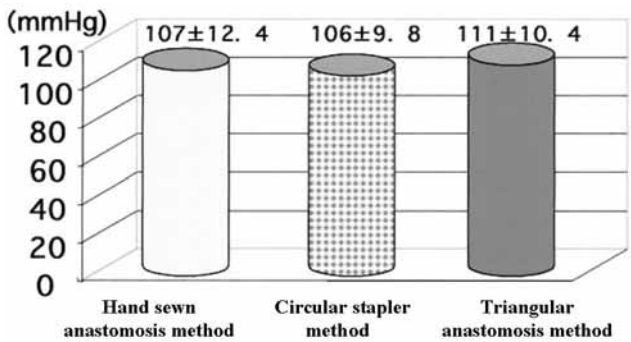

Fig. 7. Maximal pressure resistance of the removed bovine small bowel at the anastomotic part.
Maximal pressure at the anastomotic part was about 110 mmHg by any anastomosis method, showing no significant difference between them.

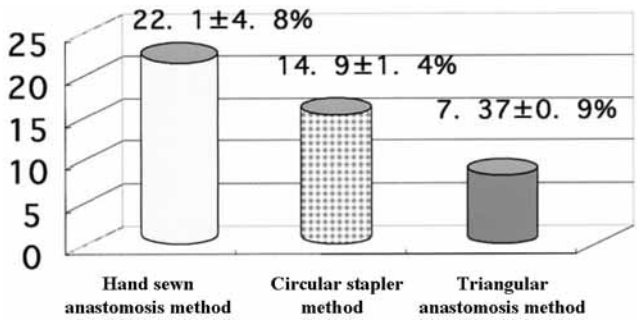

Fig. 8. Examination of stenosis rate at the anastomotic site of the removed bovine small bowel.
Reduction rate of anastomosis caliber was 22.1±4.8%, 14.9±1.4% and 7.37±0.9%, the worst was the hand sewn method, followed by the circular stapler method and the triangular anastomosis method.

ing of the operation time and validity of anastomosis.[3] However, in order to make the best use of instrumental anastomosis, it is necessary to understand sufficiently its advantage and defects. Even in instrumental anastomosis, it is necessary that (1) sufficient blood flow is maintained in the anastomotic portion, (2) it is not affected by infection, and (3) excessive strain is not applied.[4]

We applied triangular anastomosis method which has been applied to the abdominal digestive system anastomosis to the reconstruction in esophageal cancer surgery. There are 2 types for triangular anastomosis method; 2/3 eversion method where the other 2 sides are anastomosed everting after inversion anastomosis of the posterior wall, and total eversion method where 3 sides are anastomosed everting from the serous membranous side by rotating the anastomotic portion of the bowel. If triangular anastomosis method is performed in the narrow surgical field such as cervical esophago-gastric anastomosis, 2/3 eversion method which proceeds posterior wall anastomosis is to be performed. It is believed that the site where the union of the gastrointestinal tract tends to occur most easily is the serous membrane. It was reported that the submucosa has the most excellent blood flow and the union of this part is important.[5,6] Thus, layer to layer anastomosis where the mucosal layer and the lamina muscularis of the serous membrane are met was performed.

However, instrumental anastomosis for the gastrointestinal tract has been extensively used, so there is clinical experience that even mucosa eversion suture can provide good anastomosis results. Succesful factors include that

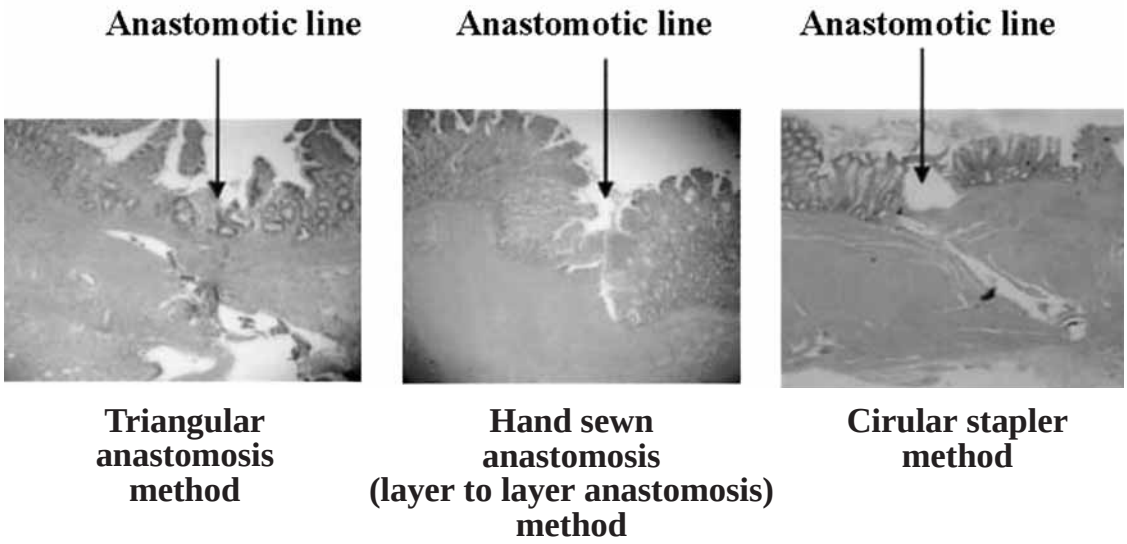

Fig. 9. Microscopic observation after anastomosis of the canine small bowel.
Continuity of the mucosa was kept by hand sewn anastomosis or triangular anastomosis. On the other hand, by the the circular stapler method, all the layers of the anastomosed bowel are severed at the same time when stapled, thus union of the muscularis is exposed in the bowel and it is found that the mucosa is not sutured.

titanium was used as the material for the staple, reducing tissue reaction or sustaining good blood flow at the anastomosis portion. Because of this, hyperplasy of the fibroblasts and reproduction of collagen are excellent. These are very advantageous against secondary phase healing process in gastrointestinal tract anastomosis. In principle, anastomosis procedure for esophageal cancer surgery is performed in the last stage of surgery in most cases. Thus, when the anastomosis procedure is started, it is necessary for all the members of surgical team to perform layer to layer anastomosis, having the same tension as that at the start of surgery in order to prevent the occurrence of anastomosis failure in advance. Discussion on suture failure and stenosis at anastomosis portion is described below.

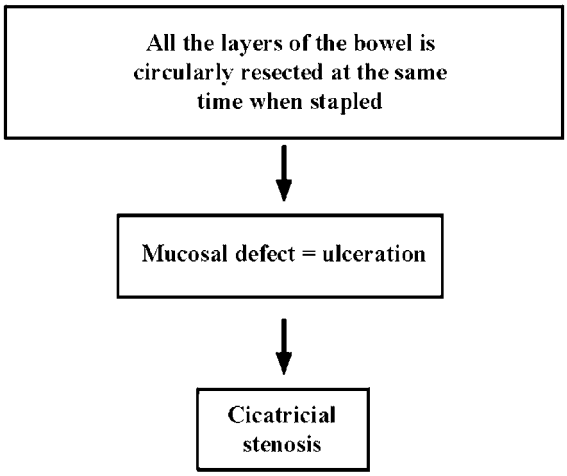

Fig. 10. Stenosis at the anastomosis by a circular stapler.
At the anastomosis, all the layers of the gastrointestinal tract are punched out and muscularis are exposed to the lumen of the gastrointestinal tract, resulting in the condition where an ulcer is circularly formed. This may develop stenosis in the healing process.

1. Suture failure

Incidence of suture failure varies depending on the reconstructed organs or reconstruction approach, and is reported to be 16% as a whole.[7] The greatest cause includes blood flow disorder at the tip of the gastric tube. There is a report that the blood flow at the tip of the gastric tube is measured using a Doppler blood flow meter, and the anastomotic site of the gastric tube is determined, significantly reducing the incidence of suture failure to 8.7%.[8]

However, recent incidence of suture failure of instrumental anastomosis without using a Doppler blood flow meter is about 20%. This may not be an improvement when compared with the results of 21.9% which is the incidence of suture failure of conventional hand sewn suture. In terms of incidence of suture failure, further switchover of approach may be requested.

It is reported that the anastomosis method using the circular stapler method is frequently performed as end to side anastomosis where the tip of the gastric tube is incised and the esophago-gastric anastomosis suturing instrument is inserted, thus the vascular net of the wall of

the gastric tube is blocked by the stapler itself, causing poor blood flow in the coecum, which develops suture failure.[9] There is a report that suture failure was reduced by elongating the distance between the esophago-gastric anastomosis line and the gastric tube coecum closure and taking a distance of about 3 to 4 cm in order to reduce suture failure at the coecum of the gastric tube.[9] In end to end anastomosis of the esophageal gastric tube by triangular anastomosis method, the vascular net of the gastric wall is not injured and blood flow at the anastomosis portion is excellent. Furthermore, considering the passage of food during swallowing, end to end anastomosis is ideal, thus, in terms of this, we would like to recommend esophago-gastric anastomosis by triangular anastomosis method.

2. Stenosis at the anastomosis portion

Conventionally, it is reported that by the circular stapler method, stenosis at the anastomotic portion occurs in 20%,[7] thus there remains very important problem for instrumental anastomosis. The cause may include that if anastomosis is performed by a circular stapler, all the layers of gastrointestinal tract are punched out at the anastomotic portion, so as we have shown, mucosal conjugation is not observed and the muscular layer is exposed in the inner lumen of the gastrointestinal tract, producing a situation where an ulcer is circularly formed at the anastomotic portion (Fig. 10). It is easily understood that this develops into stenosis in the healing process. It is reported that low blood flow in the anastomotic portion may cause not only anastomosis failure but also stenosis at the anastomotic portion, which may be one of the greatest defects of instrumental anastomosis.[10,11]

The severest complication in stenosis at the anastomotic portion is aspiration due to postoperative swallowing dysfunction. When it occurs, it may even be life threatening life in some cases. Even if recurrent nerve paralysis does not occur, stenosis of esophago-gastric anastomosis may develop life threatening aspiration. In terms of prevention of such complications, automatic triangular anastomosis method with less stenosis may be useful. The factors of triangular anastomosis method lessening stenosis may include that 2 sides of the anterior wall are eversion anastomosis. And this method can be applied to gastroduodenal anastomosis after gastrectomy, colono-colonal anastomosis or intestino-intestinal anastomosis. In particular, there is a report that in colono-colonal anastomosis or intestino-intestinal anastomosis, there are no problems if eversion anastomosis is performed, encircling all through in order to enlarge the anastomosis caliber.[12]

3. Expenses of esophago-gastric anastomosis suturing instrument

Instrumental anastomosis by a circular stapler is costly and needs to be taken into consideration. Costs of triangular anastomosis method using a linear staple three times is equivalent to that of for single use of a circular stapler. This bears relevance regarding claiming health insurance.

References

1. Steichen FM, Ravitch MM. Mechanical sutures in esophageal surgery. *Ann Surg* 1980; **191**: 373–81.
2. Orringer MB, Marshall B, Iannettoni MD. Eliminating the cervical esophagogastric anastomotic leak with a side-to-side stapled anastomosis. *J Thorac Cardiovasc Surg* 2000; **119**: 277–88.
3. Beitler AL, Urschel JD. Comparison of stapled and hand-sewn esophagogastric anastomosis. *Am J Surg* 1998; **175**: 337–40.
4. Laterza E, de'Manzoni G, Veraldi GF, Guglielmi A, Tedesco P, Cordiano C. Manual compared with mechanical cervical oesophagogastric anastomosis: a randomized trial. *Eur J Surg* 1999; **165**: 1051–4.
5. Bardini R, Bonavina L, Asolati M, Ryol A, Castoro C, Tiso E. Single layered cervical esophageal anastomosis: a prospective study of two suturing techniques. *Ann Thorac Surg* 1994; **58**: 1087–90.
6. Zieren HU, Muller JH, Pichlmaier H. Prospective randomised study of one- or two- layer anastomosis following oesophageal resection and cervical oesophagogastrostomy. *Br J Surg* 1993; **80**: 608–11.
7. Wong J, Cheung H, Lui R, Fan VW, Smith A, Siu KF. Esophagogastric anstomosis performed with a stapler: the occurrence of leakage and stricture. *Surgery* 1987; **101**: 408–15.
8. Boyle NH, Pearce A, Hunter D, Owen WJ, Mason RC. Intraoperative scanning laser Doppler flowmetry in the assessment of gastric tube perfusion during esophageal resection. *J Am Coll Surg* 1999; **188**: 498–502.
9. Tabira Y, Sakaguchi T, Kuhara H, Teshima K, Tanaka M, Kawasuji M. The width of a gastric tube has no impact on outcome after esophagectomy. *Am J Surg* 2004; **187**: 417–21.
10. Pierie JP, De Graaf PW, Poen H, Vander Tweel I, Obertop H. Impaired healing of cervical oesophagogastrostomies can be predicted by estimation of gastric serosal blood perfusion by laser Doppler flowmetry. *Eur J Surg* 1994; **160**: 599–603.
11. Aiko S, Ando N, Shinozawa Y, et al. Increased chemiluminescence and ulcer development in the low blood flow state of the gastric tube for esophageal replacement. *J Clin Gastroenterol* 1993; **17** (Suppl 1): S161–6.
12. Reynolds JV, Enker WE. A simple, safe technique for stapled reconstruction after right hemicolectomy. *J Am Coll Surg* 1995; **181**: 178–81.