Original Article

Late Development of Mitral Regurgitation after Left Ventricular Reconstruction Surgery

Goichi Yotsumoto, MD,[1] Ryuzo Sakata, MD,[1] Takayuki Ueno, MD,[1] Yoshifumi Iguro, MD,[1] Tamahiro Kinjo, MD,[1] Akira Kobayashi, MD,[1] Kazuhisa Matsumoto, MD,[1] Chuwa Tei, MD,[2] Yutaka Otsuji, MD,[2] and Yasuhiro Tanaka, MD[3]

Purpose: Late presence of mitral regurgitation (MR) after the Dor procedure (left ventricular (LV) reconstruction associated with coronary artery bypass grafting) for postinfarction patients carries a poor prognosis. The aim of this study was to review our experience with the Dor procedure and to analyze the correlation of surgical results with late MR.

Methods: The study group comprised 19 patients with previous anterior transmural myocardial infarction (MI). Ten patients were classified as New York Heart Association (NYHA) functional class III or IV at surgery. MR was moderate in 2 patients and mild in 15 patients.

Results: Myocardial revascularization was performed in all patients, with a mean of 3.7±1.2 grafts. Mitral valve was repaired in 6 patients. Four patients with mild MR underwent posterior annuloplasty, and 2 with moderate MR underwent rigid annular remodeling. Early postoperative NYHA functional class improved from 2.7±0.9 to 1.3±0.5; however, MR deteriorated to moderate in 5 patients with worsening NYHA functional class 3 months after surgery. Although the valve was not repaired during surgery in 4 patients with preoperative mild MR, 1 patient with moderate MR underwent annuloplasty with a rigid ring. All patients with late MR underwent more than 30-mL/m^2 reduction of end-diastolic volume index at surgery. Cumulative 4-year survival including hospital deaths was 89.5%.

Conclusion: To prevent the risk of late MR, a more than 30-mL/m^2 reduction of end-diastolic volume index should be avoided and mitral valve repair should be performed even if preoperative functional MR is only mild. (Ann Thorac Cardiovasc Surg 2005; 11: 159–163)

Key words: ischemic heart disease, ischemic mitral regurgitation, postinfarction ventricular remodeling, Dor procedure, mitral valve repair

Introduction

Left ventricular (LV) reconstruction associated with coronary artery bypass grafting (Dor procedure) has recently been applied to postinfarction patients with dilated left ventricle and depressed systolic function. The Dor procedure improves pump function, clinical status, and survival; however, the late occurrence of mitral regurgitation (MR) with poor prognosis is not an unusual finding after this operation.[1)] Here, we report the results of our experience with the Dor procedure and analyze the correlation of surgical results with late MR.

From [1]Second Department of Surgery, [2]First Department of Internal Medicine, and [3]Second Department of Internal Medicine, Faculty of Medicine, Kagoshima University, Kagoshima, Japan

Received October 12, 2004; accepted for publication December 3, 2004.

Address reprint requests to Goichi Yotsumoto, MD: Second Department of Surgery, Faculty of Medicine, Kagoshima University, 8-35-1 Sakuragaoka, Kagoshima 890-8520, Japan.

Patients and Methods

Between January 2000 and June 2002, 22 postinfarction patients underwent LV reconstruction at our hospital. Nineteen of these patients (86%) had LV reconstruction with a patch. These 19 patients comprised the study group.

The mean age of these patients at surgery was 65±10

years (range 48-77 years). There were 18 men and one woman. Fourteen patients had anterior myocardial infarction (MI) and five had anterior plus posterior MI. Preoperative echocardiography revealed impaired LV wall motion, with ten patients having akinetic areas and nine patients having dyskinetic areas. Five patients had LV mural thrombus, and cerebral infarction was provoked preoperatively in one patient. Even after intensive medical therapy, ten patients (53%) had heart failure of New York Heart Association (NYHA) functional class III or IV. Two patients (11%) had a history of ventricular tachycardia (VT). Seventeen patients (89%) had functional MR: two had moderate MR, and the remaining 15 had mild MR. Mitral regurgitation was assessed with color Doppler echocardiography and the severity was graded as mild, moderate, moderate to severe, or severe. Eighteen patients (95%) had two- or three-vessel coronary disease; the left anterior descending artery was occluded or significantly narrowed in all but two patients, who underwent percutaneous transluminal coronary angioplasty when acute MI occurred. Ten patients (53%) had angina including four with unstable angina.

Surgery was conducted using standard cardiopulmonary bypass with mild hypothermia. The aorta was crossclamped, and myocardial protection was achieved with antegrade crystalloid cardioplegia followed by intermittent blood cardioplegia. The left ventricle was opened from the apex with an incision parallel to the left anterior descending artery just over the scarred area and any thrombi were removed. When the MR was moderate or greater, the right side of the left atrium was opened and a Carpentier-Edwards rigid ring was inserted using interrupted mattress sutures of 3-0 braided polyester placed along the mitral annulus. Except in the initial 11 patients, posterior annuloplasty was performed to repair mild MR. The mitral valve was exposed through the same left ventriculotomy used for ventricular reconstruction. Interrupted sutures were placed in the posterior annulus from fibrous trigone to fibrous trigone and then passed through a flexible linear reducer.[2] Overall reduction of the annulus was established based on measurement of the posterior margin of the Carpentier-Edwards ring sizer, which was chosen to match the anterior leaflet size. Then, ventricular reconstruction was performed. The transitional zone between the healthy muscle and the infarcted zone was identified, and a 3-0 polypropylene purse-string suture was placed and snared. In the patients with VT, cryotherapy was applied at the margin of the infarction zone. Ventricular closure was accomplished with an oval Dacron patch by continuous 4-0 polypropylene suture.[3,4] The excluded external tissue was then plicated with or without felt strips to repair the ventriculotomy. Complete coronary revascularization was performed concomitantly.

Data are reported as mean ± standard deviation (continuous variables) or as absolute count and percentage (binary variables). Paired and unpaired *t* tests were used as appropriate. Postoperative patient survival was calculated by the Kaplan-Meier method. All analyses were performed by JMP software for Windows, version 4 (SAS Institute Inc., Cary, NC). A probability value of less than 0.05 was considered significant.

Results

Myocardial revascularization was performed in all patients (100%). The left, right, or both internal thoracic arteries were used in 18 patients (95%), the radial artery in 11 patients, the right gastroepiploic artery in three patients, and saphenous vein grafts in 17 patients. The mean number of distal anastomoses was 3.7±1.2, of which 2.3±1.1 were arterial grafts.

The mitral valve was repaired in six patients (32%). Four patients with mild MR underwent posterior mitral annuloplasty with a flexible linear reducer,[2] with the valve approached via the ventricle through the same incision used for ventricular reconstruction. The remaining two patients with moderate MR underwent rigid annular remodeling with a Carpentier-Edwards ring through the left atrium from the right side. Cryoablation was used in two patients (11%) who had a history of spontaneous VT.

The mean aortic crossclamp time was 107±23 minutes, cardiopulmonary bypass time was 145±31 minutes, and operation time was 367±60 minutes. An intra-aortic balloon pump was placed preoperatively in one patient and removed 2 days after surgery. The other 18 patients did not require intra-aortic balloon pump support after completion of the procedure.

Postoperatively, fifteen patients were examined for coronary angiography. The string angiography pattern was seen in two internal thoracic artery grafts and the graft patency was 98% (54/55 anastomoses).

Two in-hospital deaths (11%) occurred. One patient died of uncontrollable VT and ventricular fibrillation on postoperative day 24. This patient did not have a history of either arrhythmia. Another patient died of congestive heart failure with moderate MR 4 months after surgery. In this patient who had mild MR at surgery the mitral value was not repaired. Intraoperative stroke occurred in

Table 1. Echocardiographic variables of patients with and without significant late MR (n=12)

	Patients without significant late MR[a] (n=7)	Patients with Significant late MR[b] (n=5)	*p* Value
Preoperative			
LVEF(%)	27±7	22±2	0.126
LVEDVI (mL/m^2)	99±22	133±21	0.021
LVESVI (mL/m^2)	71±20	104±19	0.014
Early postoperative			
LVEF(%)	33±11	33±6	0.916
LVEDVI (mL/m^2)	83±23	86±10	0.822
LVESVI (mL/m^2)	59±22	58±9	0.938
Late postoperative			
LVEF(%)	39±11	31±4	0.180
LVEDVI (mL/m^2)	76±19	122±17	0.002
LVESVI (mL/m^2)	48±20	84±16	0.009

[a]Defined as patients without or with only mild MR.
[b]Defined as patients with moderate or greater MR.
LVEDVI = left ventricular end-diastolic volume index; LVEF = left ventricular ejection fraction; LVESVI = left ventricular end-systolic volume index; MR = mitral regurgitation.

one patient (5%). One patient developed complete atrioventricular block and underwent permanent pacemaker implantation 1 month after surgery. There was no late death during a mean follow-up of 37±15 months (range 28 to 57 months). The 4-year survival rate was 89.5% including emergent operation, hospital death, and noncardiac death.

Mean NYHA functional class significantly improved 1 month after surgery (from 2.7±0.9 to 1.3±0.5, p<0.0001). All patients were NYHA functional class I or II; however, six patients (two of 12 class I patients and four of six class II patients) worsened to NYHA functional class III 3 months after surgery. Although five patients recovered to NYHA functional class II by medical treatment, one patient died of congestive heart failure (one of the two in-hospital deaths). Among these six patients, MR deteriorated to moderate after surgery in five patients.

MR was detected early postoperatively in ten patients (53%); one had moderate and nine had mild MR. Three months after surgery, seven had mild MR and five had moderate MR. The valve was not repaired at surgery in four of these five patients with moderate MR in the late postoperative period; however, the remaining patient underwent annuloplasty with a 30-mm rigid ring.

Preoperative, early and late postoperative echocardiographic measurements by modified biplane Simpson method in 12 patients are reported in Table 1. Patients with moderate MR in the late postoperative period (significant late MR group) had greater LV end-diastolic and end-systolic volumes index (LVEDVI and LVESVI) than those of patients without or with only mild MR (no significant late MR group), both preoperatively and late postoperatively. However, LV volumes in the early postoperative period were the same in the two groups. MR fraction was significantly correlated with the reduction in (LVEDVI) at operation (r^2=0.82, p<0.0001, Fig. 1). All patients with significant late MR had a more than 30-mL/m^2 reduction in (LVEDVI).

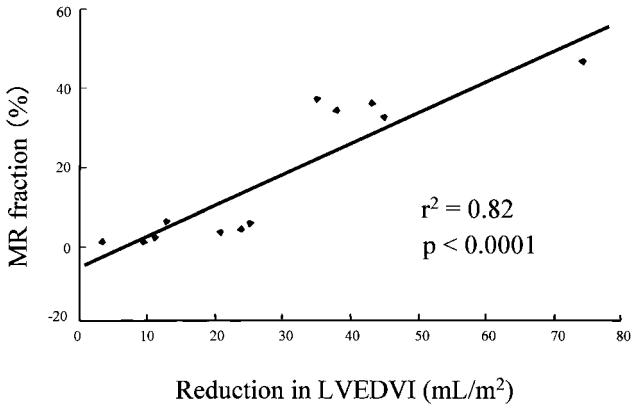

Fig. 1. Correlation between the reduction in left ventricular end-diastolic volume index (LVEDVI) and mitral regurgitant (MR) fraction.

Discussion

Postinfarction left ventricles are characterized by changes in shape and function with markedly increased volume as remodeling processes, frequently complicated by functional MR. Recent studies have shown that without LV

dilatation, global LV dysfunction, segmental LV dysfunction even in the papillary muscle territory, and isolated annular dilatation per se are not the primary causes of functional MR.[5-7] LV dilatation has been shown to cause functional MR by inducing apical displacement of the mitral leaflets and incomplete leaflet closure caused by an augmented tethering force that is a result of outward displacement of the papillary muscles.[8-12] The pathophysiologic basis for the components of the Dor procedure include coronary revascularization to optimize perfusion of viable muscle, modification of the mitral apparatus by reducing the width between displaced papillary muscles, reduction of ventricular volume, and reconstruction of ventricular shape.[13-15] If severe functional MR is present on the preoperative echocardiographic study, the mitral valve should be repaired. However, the decision to repair mild to moderate MR is problematic for the surgeon.

Di Donato and coworkers[1] reported that significant preoperative functional MR diminished 1 year after surgery in some patients who did not undergo mitral repair. Conversely, almost 30% of patients with very large and spherical ventricles without preoperative MR developed late MR. To avoid late MR, positioning the patch with an oblique orientation toward the aortic outflow tract is very important.[14-16] When the patch is positioned parallel to the mitral plane, a spherically shaped chamber without an apex will result. Residual ventricular sphericity may displace the papillary muscles toward the lateral wall, causing tethering of the mitral valve. Residual sphericity may also impair late function. When the apex is lost, the oblique apical loop fibers become transverse, and the fiber orientation of the apical loop begins to resemble that of the basal loop. The oblique orientation causes a 60% ejection fraction, whereas the transverse orientation produces only a 30% ejection fraction, even if fibers are normal.[17] The Dor procedure reduces the mass of abnormal myocardium; however, the new ventricle with severe tissue damage and profound structural extracellular collagen matrix alterations caused by preoperative remodeling will develop late further remodeling with re-dilatation.

In our series, although patients with late MR had greater preoperative volumes than did patients without late MR, the early postoperative volumes were nearly the same. Three months after surgery, patients with MR showed a significant increase in volume compared with early control volumes, and volumes were significantly larger in comparison with those of patients without MR (Table 1). This indicates that the ventricle dilated again because the remaining muscle was impaired so severely by the preoperative remodeling process that it was incapable of normal contractile function even after a more normal geometry was reconstructed. If the residual volume is too small, the consequence will be catastrophic, resulting in a dramatic reduction of stroke volume and hemodynamic impairment. To avoid restricting the LV cavity, Dor and coworkers[14] introduced the use of an intraventricular balloon filled to the theoretical diastolic volume of the patient. Menicanti and coauthors[16] recently reported the use of a preshaped elliptical balloon with a volume of 60 mL/m^2 and advised the addition of a further 15% to the volume of the balloon in the case of a very large preoperative volume, because the volume 60 mL/m^2 may be too small if the preoperative volume is very large. The correct size for different preoperative volumes has not yet been determined; however, we suggest that a more than 30-mL/m^2 reduction of the LVEDVI should be avoided to diminish the risk of late MR.

It was reported that mitral intervention should be performed if functional MR was moderate or greater.[18,19] Early in our series, however, four of 11 patients with preoperative mild MR who did not undergo mitral valve repair at surgery developed moderate MR in the late postoperative period. Therefore, we have recently used a flexible linear reducer in four patients to repair mild MR, and MR did not recur during follow-up. In contrast, moderate MR occurred in one of two patients with moderate MR who underwent mitral annuloplasty with a 30-mm rigid ring. This patient had a very large ventricle before surgery and developed late further remodeling with re-dilatation, causing late MR due to tethering. Bolling and coworkers[20, 21] recommended an undersized circumferential ring to reduce annulus size for severe MR associated with dilated cardiomyopathy. Calafiore and coauthors[22] reported that the mitral valve must be replaced in patients with functional MR due to dilated cardiomyopathy if the coaptation depth of the leaflets is 11 mm or more because return of functional MR is very likely if mitral valve repair is performed in these patients. It is not clear whether our patient required valve replacement; however, late MR would not have occurred if we had used a 26- or 28-mm ring instead of a 30-mm ring.

In conclusion, the late presence of MR in our patients appeared to be related to severe preoperative remodeling and large LV volume. To prevent the risk of late MR, a more than 30-mL/m^2 reduction of LVEDVI should be avoided. Although it is not well established which surgical technique is the most effective, mitral valve repair should be performed even if preoperative functional MR is only mild.

References

1. Di Donato M, Sabatier M, Dor V, et al. Effects of the Dor procedure on left ventricular dimension and shape and geometric correlates of mitral regurgitation one year after surgery. *J Thorac Cardiovasc Surg* 2001; **121**: 91–6.
2. Matsumoto H, Sakata R, Iguro Y, et al. Posterior mitral annuloplasty with a flexible linear reducer. *Jpn J Thorac Cardiovasc Surg* 2002; **50**: 371–4.
3. Dor V, Saab M, Coste P, Kornaszewska M, Montiglio F. Left ventricular aneurysm: a new surgical approach. *Thorac Cardiovasc Surg* 1989; **37**: 11–9.
4. Cooley DA. Ventricular endoaneurysmorrhaphy: a simplified repair for extensive postinfarction aneurysm. *J Cardiac Surg* 1989; **4**: 200–5.
5. Otsuji Y, Handschumacher MD, Schwammenthal E, et al. Insights from three-dimensional echocardiography into the mechanism of functional mitral regurgitation: direct in vivo demonstration of altered leaflet tethering geometry. *Circulation* 1997; **96**: 1999–2008.
6. Otsuji Y, Handschumacher MD, Liel-Cohen N, et al. Mechanism of ischemic mitral regurgitation with segmental left ventricular dysfunction: three-dimensional echocardiographic studies in models of acute and chronic progressive regurgitation. *J Am Coll Cardiol* 2001; **37**: 641–8.
7. Otsuji Y, Kumanohoso T, Yoshifuku S, et al. Isolated annular dilation does not usually cause important functional mitral regurgitation: comparison between patients with lone atrial fibrillation and those with idiopathic or ischemic cardiomyopathy. *J Am Coll Cardiol* 2002; **39**: 1651–6.
8. Kono T, Sabbah HN, Stein PD, Brymer JF, Khaja F. Left ventricular shape as a determinant of functional mitral regurgitation in patients with severe heart failure secondary to either coronary artery disease or idiopathic dilated cardiomyopathy. *Am J Cardiol* 1991; **68**: 355–9.
9. Kaul S, Spotniz WD, Glasheen WP, Touchstone DA. Mechanism of ischemic mitral regurgitation: an experimental evaluation. *Circulation* 1991; **84**: 2167–80.
10. He S, Fontaine AA, Schwammenthal E, Yoganathan AP, Levine RA. Integrated mechanism for functional mitral regurgitation: leaflet restriction versus coapting force: in vitro studies. *Circulation* 1997; **96**: 1826–34.
11. Liel-Cohen N, Guerrero JL, Otsuji Y, et al. Design of a new surgical approach for ventricular remodeling to relieve ischemic mitral regurgitation: insights from 3-dimensional echocardiography. *Circulation* 2000; **101**: 2756–63.
12. Yiu SF, Enriquez-Sarano M, Tribouilloy C, Seward JB, Tajik AJ. Determinants of the degree of functional mitral regurgitation in patients with systolic left ventricular dysfunction: a quantitative clinical study. *Circulation* 2000; **102**: 1400–6.
13. Stanley AW Jr, Athanasuleas CL, Buckberg GD: RESTORE Group. Left ventricular remodeling and functional mitral regurgitation: mechanisms and therapy. *Semin Thorac Cardiovasc Surg* 2001; **13**: 486–95.
14. Dor V, Di Donato M, Sabatier M, Montiglio F, Civaia F: RESTORE Group. Left ventricular reconstruction by endoventricular circular patch plasty repair: a 17-year experience. *Semin Thorac Cardiovasc Surg* 2001; **13**: 435–47.
15. Menicanti L, Di Donato M: RESTORE Group. Surgical ventricular reconstruction and mitral regurgitation: what have we learned from 10 years of experience? *Semin Thorac Cardiovasc Surg* 2001; **13**: 496–503.
16. Menicanti L, Di Donato M. The Dor procedure: what has changed after fifteen years of clinical practice? *J Thorac Cardiovasc Surg* 2002; **124**: 886–90.
17. Buckberg GD. Basic science review: the helix and the heart. *J Thorac Cardiovasc Surg* 2002; **124**: 863–83.
18. Menicanti L, Di Donato M, Frigiola A, et al.: RESTORE Group. Ischemic mitral regurgitation: intraventricular papillary muscle imbrication without mitral ring during left ventricular restoration. *J Thorac Cardiothorac Surg* 2002; **123**: 1041–50.
19. Isomura T, Suma H, Yamaguchi A, Kobashi T, Yuda A. Left ventricular restoration for ischemic cardiomyopathy- comparison of presence and absence of mitral valve procedure. *Eur J Cardiothorac Surg* 2003; **23**: 614–9.
20. Bolling SF, Deeb GM, Brunsting LA, Bach DS. Early outcome of mitral valve reconstruction in patients with end-stage cardiomyopathy. *J Thorac Cardiovasc Surg* 1995; **109**: 676–83.
21. Bolling SF, Pagani FD, Deeb GM, Bach DS. Intermediate-term outcome of mitral reconstruction in cardiomyopathy. *J Thorac Cardiovasc Surg* 1998; **115**: 381–8.
22. Calafiore AM, Gallina S, Di Mauro M, et al. Mitral valve procedure in dilated cardiomyopathy: repair or replacement? *Ann Thorac Surg* 2001; **71**: 1146–53.