Case Report

Successful Surgical Treatment of Rupture of Coronary Arteriovenous Fistula with Unconsciousness after Chest and Back Pain

Shinsuke Choh, MD,[1] Yukihiko Orime, MD,[1] Saeki Tsukamoto, MD,[1]
Motomi Shiono, MD,[2] and Nanao Negishi, MD[2]

A 65 year-old woman was admitted to our hospital, because of unconsciousness after chest and back pain. Echocardiography showed pericardial effusion. She suffered from pre-shock due to cardiac tamponade.
Although a cause of cardiac tamponade was unclear, we performed emergency surgical treatment without coronary angiography. In operation, we found a rupture of coronary arteriovenous fistula and repaired it. The patient recovered from the surgery uneventfully.
Coronary artery fistula is an abnormal communication between a coronary artery and a cardiac chamber or major vessel. It is the most common congenital anomalies of the coronary artries. Many patients with these anomalies remain asymptomatic, but some patients develop symptoms of congestive heart failure, infective endocarditis, myocardial ischemia, arrhythmia, or rupture of an aneurismal fistula. Usually, the dilatation of fistula is common, and although 19% of this may become aneurysmal, the rupture of the aneurysm is very rare.
We report a case of ruptured coronary arteriovenous fistula who underwent successful emergent surgery. (Ann Thorac Cardiovasc Surg 2005; 11: 190–3)

Key words: coronary arteriovenous fistula, cardiac tamponade, coronary aneurysm

Introduction

A coronary artery fistula is the most common congenital anomaly of the coronary artries and is an abnormal communication between an epicardial coronary artery and a cardiac chamber or major vessel. Althogh some patients develop symptoms of congenital heart failure, infective endocarditis, myocardial ischemia, arrhythmia, or rupture of an aneurysmal fistula, many patients with these anomalies remain asymptomatic. Rupture of an aneurysmal fistula is a very rare. We report here a case of ruptured coronary fistula who became unconscious after chest and back pain. This patient developed cardiac tamponade and emergent surgical treatment was successfully performed.

From [1]Department of Cardiovascular Surgery, Surugadai-Nihon University Hospital, and [2]The 2nd Department of Surgery, Nihon University School of Medicine, Tokyo, Japan

Received March 15, 2004; accepted for publication November 22, 2004.
Address reprint requests to Shinsuke Choh, MD: Department of Cardiovascular Surgery, Surugadai-Nihon University Hospital, 1-8-13 Kandasurugadai, Chiyoda-ku, Tokyo 101-8309, Japan.

Case Report

A 65 year-old woman was admitted to intensive care unit in our hospital, because of unconsciousness after chest and back pain. Her past medical history includes hypertension and hyperlipidemia. On arrival, her consciousness was clear and she did not feel pain, but she was pre-shock. Her blood pressure was 76/40 mmHg and pulse rate was 90/min. A dilated neck vein was observed. Echocardiography performed on admission showed pericardial effusion and cardiac tamponade. Electrocardiograph (ECG) was normal sinus rhythm and indicated no change of ST-T wave. Computerized tomography (CT) showed no dissection of aorta, only pericardial effusion (Fig. 1). All other laboratory tests were normal.

Although a cause of cardiac tamponade was unclear,

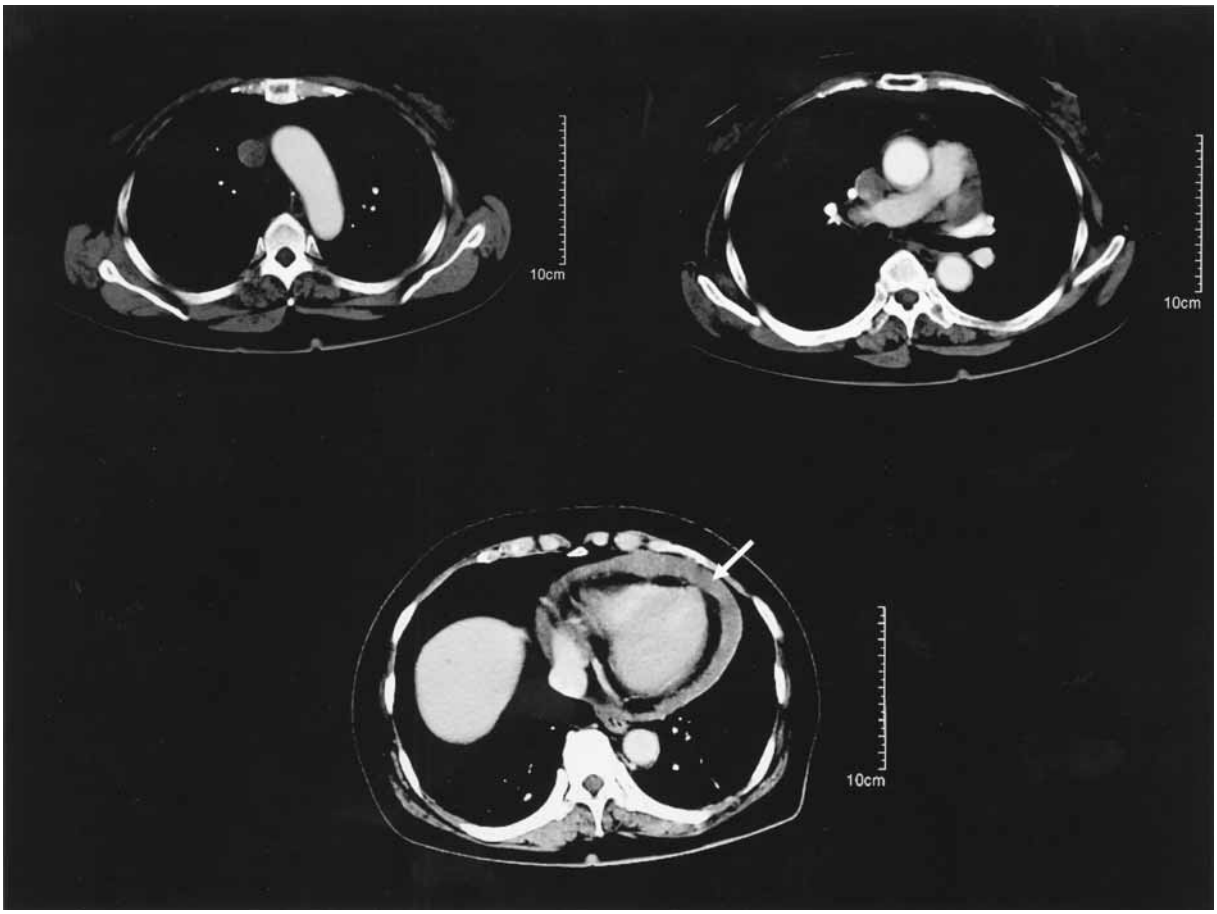

Fig. 1. Chest CT showed pericardial effusion (an arrow), but no aortic dissection.

we performed emergent surgical treatment without coronary angiography because she was pre-shock.

In operation, pericardial effusion was bloody and we found a hematoma and a dilated coronary arteriovenous fistula in area of left circumflex artery (LCx). The shape of this fistula was saccular, and it measured about 10 by 30 mm (Fig. 2). At this fistula, a bleeding point was identified. We put this fistula in between the felt strips like a sandwich and ligated on a beating heart.

On postoperative day one, coronary angiography showed the occlusion of a branch of LCx (Fig. 3), but the left ventricular wall motion and ECG was normal. She recovered uneventfully, and was discharged on the postoperative day 10.

Discussion

Coronary artery fistula is an abnormal communication between an epicardial coronary artery and a cardiac chamber or major vessel (vena cava, pulmonary artery etc.)[1] and the most common congenital anomalies of the coronary artries. Sometimes we find small coronary arteriovenous fistula in coronary angiography. Many patients with these anomalies remain asymptomatic, but some patients develop symptoms of congestive heart failure, infective endocarditis, myocardial ischemia, arrhythmia, or rupture of an aneurysmal fistula. Coronary steal, volume overload or an infection are the causes of these clinical manifestations.

Usually, the dilatation of fistula is common, and although 19% of this may become aneurysmal,[2] the rupture of the aneurysm is very rare.

To the best of our knowledge, there are 12 cases of ruptured coronary arteriovenous fistula,[3-14] excluding our case (Table 1). Surgical treatment was performed in twelve patients including ours. The prognosis was good in surgically treated patients.

In this case, we took acute aortic dissection (Stanford

Fig. 2. In operation, a dilated coronary arteriovenous fistula that was saccular type, and measured about 10 by 30 mm was found in the area of the left circumflex artery (an arrow).

A type) into consideration, because of unconsciousness after chest and back pain, and cardiac tamponade at echocardiography on her arrival. Aortic dissection was not revealed at chest CT. Although the cause of cardiac tamponade was unclear, we performed emergency surgical treatment without coronary angiography because she was in a state of pre-shock. It is recommended to perform coronary angiography prior to surgery if patient is hemodynamically stable.

In order to permanently close the coronary fistula, surgical ligation and percutaneous closure are the currently available options. Transcatheter embolic occlusion of a coronary fistula have been successfully reported with a variety of materials, such as a covered stent, platinum coils, detachable balloons, double-umbrella devices and thrombogenic foams.[15-17] Although transcatheter embolic occlusion is easier than surgical treatment, in a case of acute manifestation like this patient, we think it is necessary to perform an emergency surgical treatment.

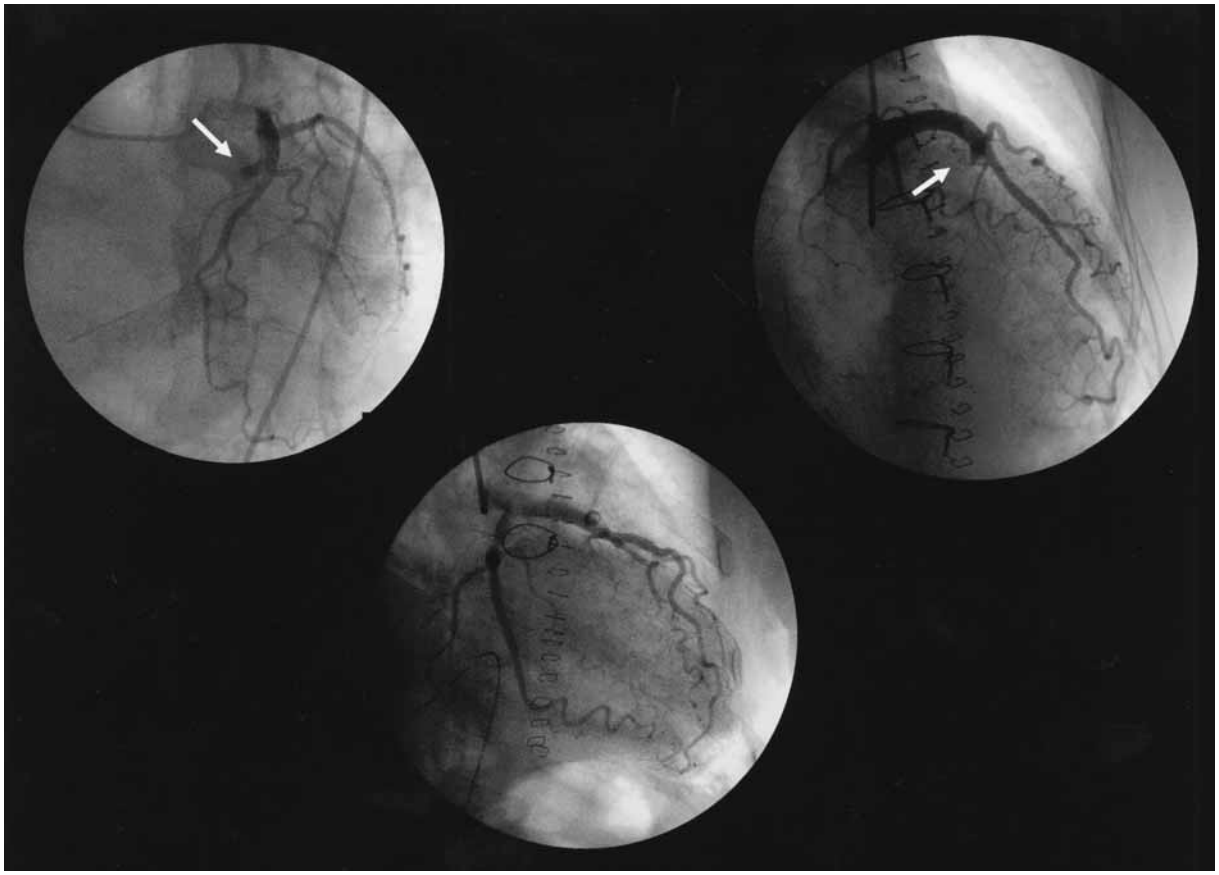

Fig. 3. Coronary angiography showed total occlusion of a branch of the left circumflex artery (an arrow).

Table 1. The reports of ruptured coronary arteriovenous fistura

Author	(year)	Age	Sex	Chief complaints	Surgical treatment	Prognosis
1. Habermann[3]	(1963)	52	M	Epigastralgia, chest pain	(–)	Sudden death
2. Shichijo[4]	(1993)	65	F	Chest, back pain	(+)	Alive
3. Koyama[5]	(1993)	72	F	Abnormal shadow (chest X-P)	(+)	Alive
4. Yamaki[6]	(1993)	63	F	Acute heart failure	(+)	Alive
5. Bauer[7]	(1996)	82	F	Epigastralgia, chest pain	(+)	Alive
6. Rhu[8]	(1997)	52	F	Chest pain	(+)	Alive
7. Koshika[9]	(1999)	57	F	Chest pain	(+)	Alive
8. Sakao[10]	(2000)	59	F	Unconsciousness	(+)	Alive
9. Ito[11]	(2000)	58	F	Chest pain	(+)	Alive
10. Misumi[12]	(2001)	63	F	Unconsciousness	(+)	Alive
11. Akashi[13]	(2003)	69	F	Unconsciousness	(+)	Alive
12. Ozeki[14]	(2002)	75	F	Chronic cardic tamponade	(+)	Alive
13. Ours		65	F	Chest, back pain, unconsciousness	(+)	Alive

References

1. Vavuranakis M, Bush CA, Boundoulas H. Coronary artery fistulas in adults: incidence, angiographic characteristics, natural history. *Cathet Cardiovasc Diagn* 1995; **35**: 116–20.
2. Urrutia-S CO, Falaschi G, Ott DA, Cooley DA. Surgical management of 56 patients with congenital coronary artery fistulas. *Ann Thorac Surg* 1983; **35**: 300–7.
3. Habermann JH, Howard ML, Johnson ES. Rupture of the coronary sinus with hemopericardium. a rare complication of coronary arteriovenous fistula. *Circulation* 1963; **28**: 1143–4.
4. Shichijo T, Motohiko K, Umemori Y. A case of coronary artery to pulmonary artery fistula associated with impending rupture of saccular aneurysm. *Kyobu Geka* 1993; **46**: 164–7. (in Japanese)
5. Koyama K, Suzuki S, Fukui K, et al. Bilateral coronary-pulmonary artery fistulas with a large saccular aneurysm: a case of cardiac tamponade following rupture of the coronary artery aneuryam. *Kyobu Geka* 1993; **46**: 714–6. (in Japanese)
6. Yamaki F, Nakajima M, Hirayama T, Kume S. A case report of surgical treatment of ruptured coronary artery aneurysm. *Nippon Kyobu Geka Gakkai Zassi* 1993; **41**: 2229–33. (in Japanese)
7. Bauer HH, Allmendinger PD, Flaherty J, Owlia D, Rossi MA, Chen C. Congenital coronary arteriovenous fistula: spontaneous rupture and cardiac tamponade. *Ann Thorac Surg* 1996; **62**: 1521–3.
8. Ryu JC, Choe YH, Park PW, Park JE, Chae H, Lee WR. Cardiac tamponade due to a rupture of the coronary arteriovenous aneurysm—a case report. *J Korean Med Sci* 1997; **12**: 143–5.
9. Koshika M, Goto S, Yamamoto K, Inoue H, Oguma F, Kasuya S. Surgical treatment of a ruptured saccular aneurysm associated with bilateral coronary arteries-pulmonary artery fistulas: a case report. *Kyobu Geka* 1999; **52**: 924–7. (in Japanese)
10. Sakao T, Tsunooka N, Nakagawa H, Kajiwara S. Ruptured saccular aneurysm of a coronary artery to pulmonary artery fistula associated with cardiac tanponade. *Kyobu Geka* 2000; **53** (8 Suppl): 684–6. (in Japanese)
11. Ito M, Kodama M, Saeki M, et al. Rupture of a giant saccular aneurysm of coronary arteriovenous fistulas. *Jpn Heart J* 2000; **41**: 659–64. (in Japanese)
12. Misumi T, Nishikawa K, Yasudo M, Suzuki T, Kumamaru H. Rupture of an aneurysm of a coronary arteriovenous fistula. *Ann Thorac Surg* 2001; **71**: 2026–7.
13. Akashi H, Tayama E, Tayama K, et al. Rupure of an aneurysm resulting from a coronary artery fistula: a case report. *Circ J* 2003; **67**: 551–3.
14. Ozeki S, Utsunomiya T, Kishi T, et al. Coronary arteriovenous fistula presenting as chronic pericardial effusion. *Circ J* 2002; **66**: 779–82.
15. Boccalandro F, Awadalla H, Smalling RW. Percutaneous transcatheter coil embolization of two coronary fistulas originating from the left main ostium and left anterior descending artery. *Catheter Cardiovasc Interv* 2002; **57**: 221–3.
16. Dorros G, Thota V, Ramireddy K, Joseph G: Catheter-basaed techniques for closure of coronary fistulae. *Catheter Cardiovasc Interv* 1999; **46**: 143–50.
17. Perry SB, Lock JE. Front-loading of double-umbrella devices, a new technique for umbrella delivery for closing cardiovascular defects. *Am J Cardiol* 1992; **70**: 917–20.