

Surgical Treatment of Ischemic Mitral Valve Regurgitation

Kazuo Tanemoto, MD, PhD

In cases of old myocardial infarction, the presence of mitral valve regurgitation is one of the predicting factors of long-term prognosis. The mechanism of ischemic mitral regurgitation consists of mitral annular dilatation, left ventricular (LV) dilatation followed by tethering of the mitral valve, etc. Since long-term prognosis of the patients in whom the degree of mitral valve regurgitation is 2+ or more is typically poor, the mitral valve procedure should be considered at the time of coronary artery bypass grafting (CABG) or more. In this type of surgery, the treatment essentially involves the use of an artificial ring implantation as the basic technique. In the chronic stage, a significant degree of mitral regurgitation persists in approximately 20% of the cases if they have been treated by ring annuloplasty alone. Additional surgical procedures that reduce or eradicate the tethering are essential for the control of the regurgitation completely in cases with strong tethering. We recently employed two new surgical techniques, namely, cutting the secondary chordae to the anterior mitral valve leaflet and the anterior and posterior papillary muscle reapproximation. The surgical results of the acute phase appear to be promising; however, the long-term results of such new methods are yet to be determined. If the mitral valve regurgitation cannot be controlled even by various operative techniques of mitral valve repair, mitral valve replacement should be considered. This is because the long-term survival rate of the suboptimal repair surgical patients is lower when compared with that of mitral valve replacement patients. (*Ann Thorac Cardiovasc Surg* 2005; 11: 228–31)

Key words: ischemic mitral regurgitation, tethering, papillary muscle, mitral valve repair surgery, mitral valve replacement

Introduction

Although the advancement in catheter intervention for ischemic heart disease has improved the survival rate, the increase in the number of ischemic cardiomyopathy patients has resulted in an increase in the cases of ischemic mitral regurgitation. It has been clearly shown that patients with mitral regurgitation have poor long-term prognosis;¹⁾ therefore, ischemic mitral regurgitation is one of

the main problems that should be considered while treating ischemic heart disease patients.

Mitral Valve Replacement, as Lifesaving Surgery, Should Be Considered When Papillary Muscle Disruption Occurs

Papillary muscle disruption, which occurs in the acute stage, causes severe mitral valve regurgitation, and the patient faces rapid circulatory deterioration. The patient begins to develop acute pulmonary edema, which is extremely hazardous; hence, emergency surgery needs to be performed to prevent fatality. In almost all cases, mitral valve replacement surgery is performed, although there are some reports of successful mitral valve repair surgery for the treatment of papillary muscle disruption.

From Division of Thoracic and Cardiovascular Surgery, Department of Surgery, Kawasaki Medical School, Okayama, Japan

Received April 18, 2005; accepted for publication June 10, 2005. Address reprint requests to Kazuo Tanemoto, MD, PhD: Division of Thoracic and Cardiovascular Surgery, Department of Surgery, Kawasaki Medical School, 577 Matsuyama, Kurashiki, Okayama 701-0192, Japan.

However, despite these surgeries, the mortality rate is very high, and the prognosis is considerably bad in the acute period.²⁾

Chronic Mitral Regurgitation Is More Frequent with Inferior Wall and Lateral Wall Infarcts

In such cases, the mitral valve itself is not diseased, and mitral valve regurgitation occurs due to left ventricular (LV) remodeling following myocardial infarction. While treating ischemic mitral regurgitation, it is important to have a deep understanding of the changes in the intraventricular apparatus that can improve ischemic mitral valve regurgitation. Previously, it was believed that ischemic mitral regurgitation occurred due to papillary muscle dysfunction.³⁾ However, a recent study revealed that the ischemic mitral regurgitation may be attributed to several factors such as the mitral valve annulus, LV shape, papillary muscles, and chordae tendineae. Moreover, it was shown that ischemic mitral regurgitation develops more frequently in patients with lateral and inferior wall infarctions, rather than anterior wall infarction, and the severity of mitral valve regurgitation does not depend only on the degree of LV dilation.

At the Time of Coronary Artery Bypass Grafting (CABG), the Treatment of the Mitral Valve Should Be Considered If the Degree of Mitral Regurgitation Is 2+ or More

In some cases, mitral valve regurgitation disappears after the improvement of LV movement by coronary artery bypass grafting (CABG).⁴⁾ However, it is extremely difficult to predict the cases in which the regurgitation disappears after CABG alone. Moreover, it was shown that the long-term prognosis was poor in the cases in which the degrees of mitral valve regurgitation remained 2+ or more after the operation. Hence, cases in which the degree of mitral regurgitation is 2+ or more before surgery are recommended to undergo mitral valve surgery.⁵⁾ Mitral valve treatment is particularly recommended for patients in whom exercise increases mitral regurgitation before surgery. Moreover, in certain cases, the degree of regurgitation evaluated by transesophageal echocardiography before the surgery differs greatly from that evaluated in the operating room. This is because the after-load is reduced by anesthesia, and it is necessary to decide the type of surgery based on the evaluation by UCG, which is conducted prior to surgery.

Anchoring the Artificial Ring Is the Principle of the Surgery for Mitral Valve Regurgitation

Mitral valve repair surgery results in an excellent prognosis in patients with ischemic mitral valve regurgitation. This surgery is basically mitral valve annuloplasty that involves the insertion of an artificial ring. The distance between both the fibrous trigones expands in ischemic mitral valve regurgitation, and results in an increase in the distance between the anterior annulus and the posterior annulus. Therefore, the selection of a ring that reduces the septolateral diameter and restores the inter-trigonal distance of the mitral valve is frequently employed for this type of mitral valve surgery. It has been suggested that a rigid ring or a semi-rigid ring (Physio™ ring) is suitable for the above-mentioned purposes. Since it is not necessary to consider the development of SAM postoperatively due to the use of a small ring, it is recommended that while selecting the size, a ring that is one or two sizes smaller than the mitral valve ring be chosen in order to reduce the septolateral diameter of the mitral valve to a considerable extent.^{6, 7)} With regard to the implantation technique, interrupted mattress suture has been employed as a standard technique. We practiced an improved technique of anchoring the artificial ring with continuous sutures. This technique requires less time to anchor the ring than the original method with interrupted mattress sutures, and it can prevent narrowing the mitral valve annulus when a type of flexible ring is used.⁸⁾

New Surgical Approach to the Phenomenon of “Tethering”

It is considered that the papillary muscles are displaced to the lateral side due to LV dilatation. The phenomenon of “tethering,” in which the mitral valve leaflet is pulled toward the LV apex, is an important cause of ischemic mitral regurgitation.⁹⁾ In patients with strong tethering, regurgitation cannot be treated by mitral valve ring annuloplasty alone. A significant degree of mitral regurgitation persists in approximately 20% of the cases that were treated by ring annuloplasty alone during the chronic stage. Additional surgical procedures that reduce or eradicate the tethering are necessary for complete control of the regurgitation in cases with strong tethering.

Cutting the secondary chordae to the anterior mitral valve leaflet¹⁰⁾

Cutting the secondary chordae of the anterior leaflet of

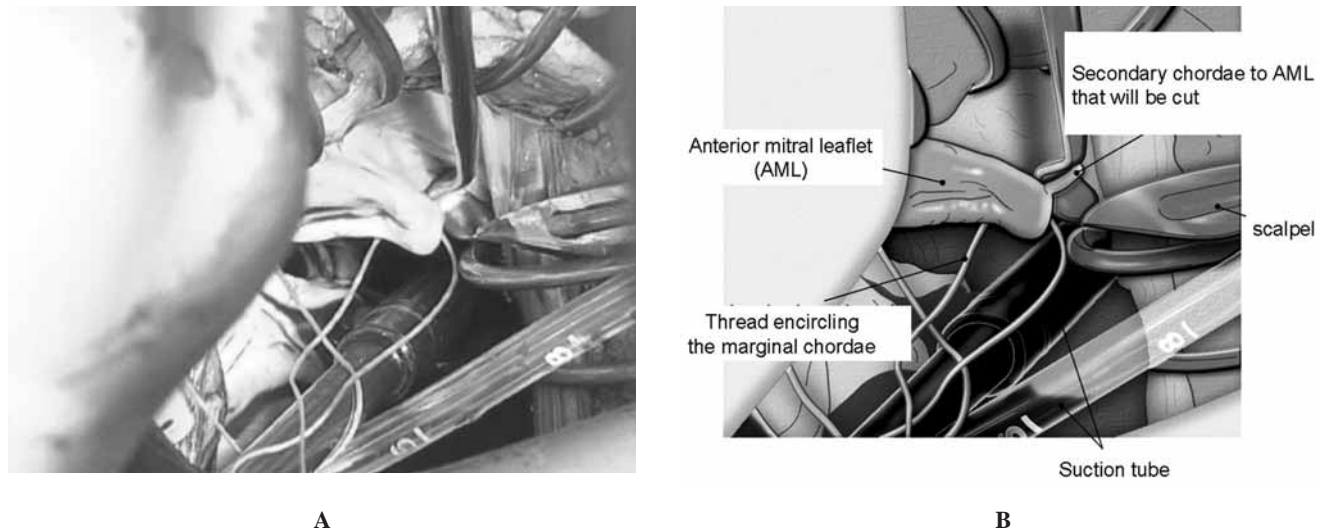


Fig. 1. Cutting the secondary chordae of the anterior mitral valve leaflet.

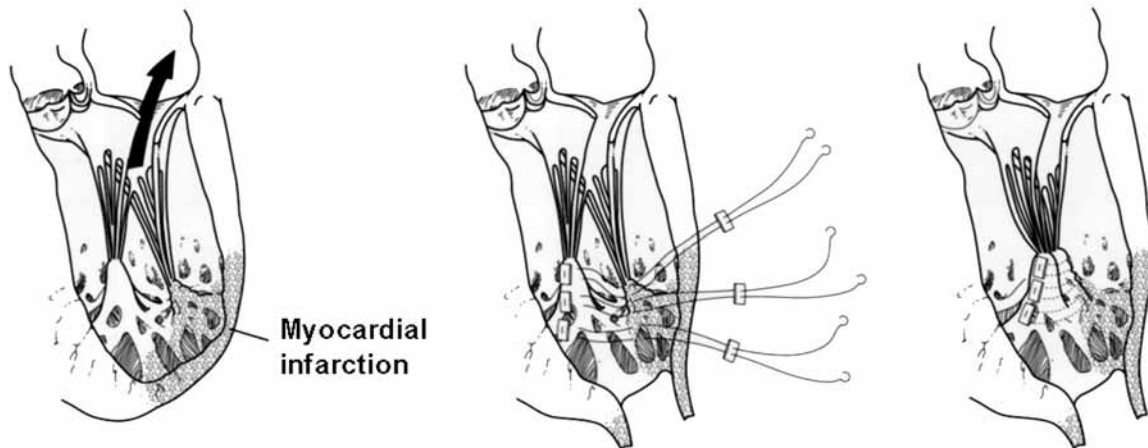


Fig. 2. The anterior and posterior papillary muscle reapproximation.

the mitral valve improves the coaptation of the mitral valve and diminishes anterior leaflet bending. The secondary chordae can be cut in three ways: through the aortic valve, from the LV, and from the left atrium. We generally employ the left atrial approach and cut the secondary chordae originating from the posterior papillary muscle and extending to the anterior leaflet of the mitral valve (Fig. 1A, B). In combination with this technique, mitral valve annuloplasty should be carried out using a small size annuloplasty ring (Physio™ ring). With regard to this type of surgery, a number of problems concerning the long-term complications have not yet been understood. Therefore, this discussion will be continued in the future, including the justification of cutting the chordae tendineae that originally have a physiological function.

The anterior and posterior papillary muscle reapproximation¹¹⁾

Another procedure is reapproximating both the papillary muscles side by side and reducing the tethering (Fig. 2). Tethering was lost immediately after surgery, and mitral regurgitation was not observed on the echocardiogram of the patient who underwent this procedure. It is believed that a large number of case studies are required for elucidating the long-term complications that may arise when the papillary muscle itself is sutured.

Other Types of Surgeries

Pulling up the papillary muscle toward the mitral annulus by placing a suture from the papillary muscle base to

the mitral annulus has been reported as an alternative to ischemic mitral valve regurgitation surgery. Another surgical procedure that has been reported is the plication of the posterior wall of the LV in order to reduce the tethering force. Moreover, patch enlargement of the posterior mitral leaflet is performed to increase its height. However, none of these surgeries has yielded promising results; hence, reports on the long-term results are required before widespread acceptance of this new type of surgery.

The Long-Term Prognosis of Suboptimal Mitral Valve Repair Surgery Is Worse than That of Valve Replacement

With regard to the operative mortality, there should not be a significant difference between mitral valve repair surgery and valve replacement. However, the mitral valve repair surgery has a clear benefit with regard to long-term mortality and valve-related morbidity.¹²⁾ On the other hand, the long-term survival rate of cases in which significant mitral regurgitation of 2+ or more degrees persisted after a suboptimal repair surgery was performed was found to be lower when compared with cases that underwent the mitral valve replacement.¹³⁾ In cases in which mitral valve regurgitation cannot be controlled even by various operative techniques of mitral valve repair, mitral valve replacement should be considered for the improvement of long-term prognosis.

References

1. Grigioni F, Enriquez-Sarano M, Zehr KJ, Bailey KR, Tajik AJ. Ischemic mitral regurgitation: long-term outcome and prognostic implications with quantitative Doppler assessment. *Circulation* 2001; **103**: 1759–64.
2. Yada I, Wada H, Shinoda M, Yasuda K, Committee of Science, Japanese Association for Thoracic Surgery: Thoracic and cardiovascular surgery in Japan during 2001: annual report by the Japanese Association for Thoracic Surgery. *Jpn J Thorac Cardiovasc Surg* 2003; **51**: 699–716.
3. Burch GE, De Pasquale NP, Phillips JH. Clinical manifestations of papillary muscle dysfunction. *Arch Intern Med* 1963; **112**: 112–7.
4. Miller DC. Ischemic mitral regurgitation redux—to repair or to replace? *J Thorac Cardiovasc Surg* 2001; **122**: 1059–62.
5. Lam BK, Gillinov AM, Blackstone EH, et al. Importance of moderate ischemic mitral regurgitation. *Ann Thorac Surg* 2005; **79**: 462–70.
6. Bolling SF. Mitral reconstruction in cardiomyopathy. *J Heart Valve Dis* 2002; **11** (Suppl 1): S26–31.
7. Bax JJ, Braun J, Somer ST, et al. Restrictive annuloplasty and coronary revascularization in ischemic mitral regurgitation results in reverse left ventricular remodeling. *Circulation* 2004; **110** (11 Suppl 1): II103–8.
8. Tanemoto K, Kanaoka Y, Murakami T, Kuroki K, Minami H: Anchoring the Duran flexible annuloplasty ring with continuous sutures. *J Cardiovasc Surg (Torino)* 2001; **42**: 217–9.
9. Otsuji Y, Handschumacher MD, Schwammenthal E, et al. Insights from three-dimensional echocardiography into the mechanism of functional mitral regurgitation: direct in vivo demonstration of altered leaflet tethering geometry. *Circulation* 1997; **96**: 1999–2008.
10. Messas E, Pouzet B, Touchot B, et al. Efficacy of chordal cutting to relieve chronic persistent ischemic mitral regurgitation. *Circulation* 2003; **108** (Suppl 1): II111–5.
11. Matsui Y, Fukada Y, Naito Y, Sasaki S. Integrated overlapping ventriculoplasty combined with papillary muscle plication for severely dilated heart failure. *J Thorac Cardiovasc Surg* 2004; **127**: 1221–3.
12. Grossi EA, Goldberg JD, LaPietra A, et al. Ischemic mitral valve reconstruction and replacement: comparison of long-term survival and complications. *J Thorac Cardiovasc Surg* 2001; **122**: 1107–24.
13. Hausmann H, Siniawski H, Hetzer R. Mitral valve reconstruction and replacement for ischemic mitral insufficiency: seven years' follow up. *J Heart Valve Dis* 1999; **8**: 536–42.