Case Report

A Case of Mitral Valve Replacement with a Collar-reinforced Prosthetic Valve for Heavily Calcified Mitral Annulus

Yasuhisa Fukada, MD,[1] Yoshiro Matsui, MD, PhD,[1] Shigeyuki Sasaki, MD, PhD,[2] and Keishu Yasuda, MD, PhD[3]

Mitral valve replacement in the presence of extensive calcification of the mitral annulus is a technical challenge. Dense calcification of the annulus can cause a great difficulty in the insertion of a prosthetic valve and later periprosthetic leakage. A radical calcium debridement may cause left circumflex coronary artery injury, atrioventricular rupture, and thromboembolic events. We report a case of a 65-year-old woman suffering from mitral regurgitation with a severely calcified mitral annulus. She underwent mitral valve replacement using a collar-reinforced prosthetic valve, which allowed the surgeon to safely insert a prosthetic valve, avoiding the calcification completely without any major complications. We recommend this method as a feasible technique for mitral valve replacement in the presence of heavily calcified or disrupted fragile mitral annulus. (Ann Thorac Cardiovasc Surg 2005; 11: 260–3)

Key words: mitral regurgitation, mitral valve replacement, calcification of the mitral valve annulus, collar-reinforced prosthetic valve, Edwards MIRA prosthetic valve

Introduction

Calcification of the mitral valve annulus is an age-related degenerative process that involves the posterior aspect of the annulus and may spread on the atrial and ventricular walls. Its presence lends special difficulty to seating prosthesis along the area of the posterior leaflet during mitral valve replacement, and this has been associated with an increased frequency of periprosthetic leakage. Moreover, vigorous annular decalcification will contribute to the likelihood of atrioventricular separation, coronary vessel disruption, and cardiac rupture. We described a technique that circumvents many of the problems associated with valve replacement under this condition.

From [1]Department of Cardiovascular Surgery, NTT East Corporation Sapporo Hospital, Sapporo, [2]Division of Medical Sciences, Health Science University of Hokkaido, Ishikari-Tobetsu, and [3]Department of Cardiovascular Surgery, Hokkaido University School of Medicine, Sapporo, Japan

Received November 19, 2004; accepted for publication January 23, 2005.
Address reprint requests to Yasuhisa Fukada, MD: Department of Cardiovascular Surgery, NTT East Corporation Sapporo Hospital, S1W15, Chuo-ku, Sapporo 060-0061, Japan.

Case Report

A 65-year-old woman diagnosed with mitral insufficiency and aortic stenosis (AS) was referred to our hospital for surgery. She had been treated with hemodialysis for 14 years due to chronic renal failure. Preoperative echocardiography revealed degenerative mitral valve disease with mitral regurgitation grade 3 and severe AS with an estimated pressure gradient of 100 mmHg. Computed tomography of the chest revealed massive calcification of the posterior mitral annulus (Fig. 1). Cardiac catheterization revealed normal coronary arteries, and left ventricular function was normal (ejection fraction, 70%).

Operation was performed through a median sternotomy. Cardiopulmonary bypass was instituted via right atrial venous and ascending aortic cannulas. A left ventricular venting tube was inserted through the right superior pulmonary vein. After cardioplegic arrest, exposure was obtained through a left atriotomy. The posterior mitral annulus was found to have been replaced with a mass of calcium, which extended into the ventricular cavity below the leaflet. The annulus of the anterior leaflet was less involved and pliable, and the valve leaflets themselves

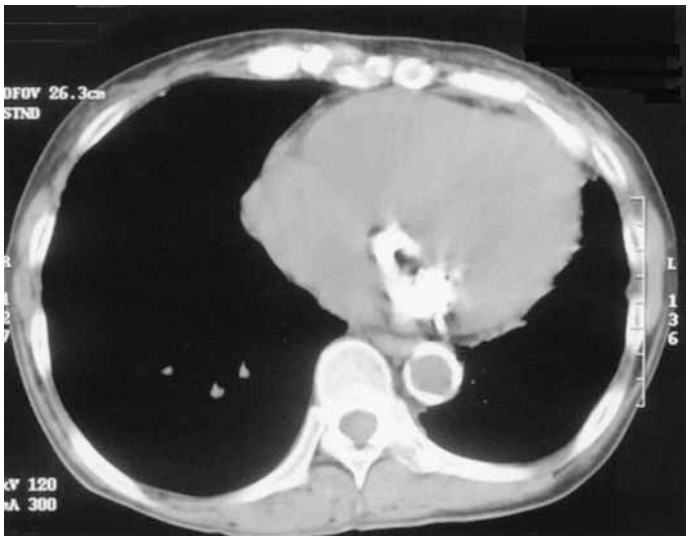

Fig. 1. Computed tomography scan demonstrated severe calcification of the mitral annulus.

were thickened but not calcified. The anterior leaflet was removed; nothing was excised from the posterior leaflet or the intramural block of calcium. A 23-mm Edwards MIRA prosthetic valve (Edwards Lifesciences LLC, Irvine, CA, USA) modified by enlarging the circumference of the sewing ring by the attachment of a 1.5 cm wide equine pericardial collar (Equine Pericardial Patch; Edwards Lifesciences LLC, Irvine, CA, USA) (Fig. 2) was secured with 2-0 polyester pledgeted mattress sutures placed through the posterior leaflet tissue from the left ventricle to the left atrium and then passed through the sewing ring of the composite valve. No sutures were placed through the calcified posterior annulus, but the anterior annulus was incorporated where suitable. After tying the mattress sutures, the free edge of equine pericardial collar was sutured to the atrial wall with a running 4-0 polypropylene suture (Fig. 3). The aortic valve was replaced with a 19-mm SJM prosthetic valve (St. Jude Medical Inc., St. Paul, MN, USA) in the usual fashion. The patient was smoothly weaned from cardiopulmonary bypass and intraoperative echocardiogram examination confirmed satisfactory valve function. The duration of cardiopulmonary bypass and aortic cross clamp was 227 min and 173 min, respectively. The postoperative course was uneventful and the patient was discharged on the 22nd postoperative day. The patient has been doing well for 16 months postoperatively without evidence of periprosthetic leakage.

Discussion

The mitral valve becomes calcified as a consequence of a degenerative process related to aging within the cardiac fibrous skeleton mainly the posterior annulus of the mitral leaflet, which is followed by erosion through the calcification of the posterior mitral leaflet. Calcification of the mitral annulus is most often found in horseshoe configuration with sparing of the majority of the anterior mitral leaflet and associated with myxomatous degeneration of the mitral valve, bacterial endocarditis, Marfan's syndrome, rheumatic disease, diabetes, and chronic renal failure.[1-3] Calcification of the mitral annulus is reported to be found at autopsy in 0.2% of patients more than 50 years old.[4] Mitral ring calcification shows a



Fig. 2. A 1.5 cm wide equine pericardial collar has been sewn to the sewing ring of a 23-mm Edwards MIRA prosthetic valve.

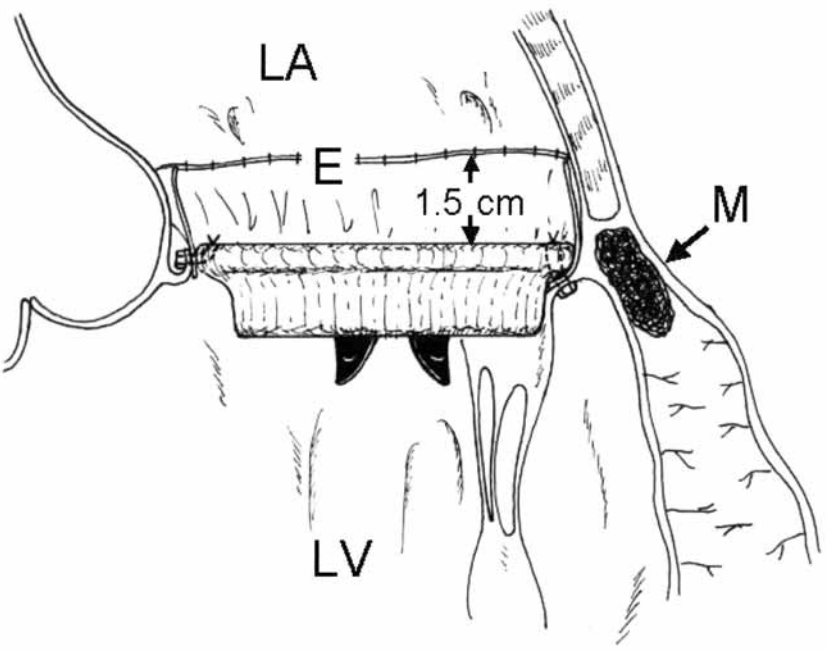

Fig. 3. A collar-reinforced Edwards MIRA prosthetic valve was secured with 2-0 polyester pledgeted mattress sutures placed through the posterior leaflet tissue from the left ventricle to the left atrium and then passed through the sewing ring of the composite valve. The free edge of equine pericardial collar was sutured to the atrial wall with a running 4-0 polypropylene suture.
LA, Left atrium; LV, left ventricle; M, mitral annular calcification; E, equine pericardial patch.

marked and statistically significant correlation with age.[5] This condition is more common in elderly woman, with a female-to-male ratio of 2:1.[4] Calcium infiltration of the base of the posterior leaflet reduces leaflet mobility, increases traction on the chordae, elevates the leaflets, and thus facilitates chordal elongation or rupture, a cause of secondary mitral valve insufficiency.[6]

Extensive calcification will jeopardize mitral valve replacement. The bulky calcium may interfere with suture placement, prevent proper insertion of prosthesis, and increase the frequency of periprosthetic leakage. Carpentier et al. reported en bloc excision of the calcific bar as a feasible procedure for patients with extensive calcification,[6] which is, however, difficult when the calcific stalactites extend into the ventricular myocardium.[3,5,6] Moreover, annular decalcification will contribute to the likelihood of atrioventricular separation, circumflex coronary artery damage, fragmentation of calcium which may cause perioperative stroke, and mid-ventricular rupture.[3,4,7]

Some surgeons reported intra-atrial insertion of a collar-reinforced prosthetic valve.[8-11] However, this technique leaves the attenuated portion of the annulus in the high-pressure chamber at risk for aneurysmal dilatation or rupture as a late complication.[12] Coselli and Crawford reported a technique of mitral valve replacement by anchoring a low-profile mechanical valve using valve leaflets to avoid the calcified annulus and to preserve the mitral apparatus.[13] However, perivalvular leakage may occur through a linear fracture in the leaflet at the site of needle penetration. The technique we describe here is a combination of these two procedures. It facilitates to avoid the risk of decalcification described above and to disperse the hemodynamic stress. The height of the collar of the valved conduit allows atrial anchorage of the sewing ring and protection against a hemodynamically significant perivalvular leakage.

We chose the Edwards MIRA prosthetic valve because of its hyperbolic shape and compressibility of the sewing ring that permits conformation to irregularities of the highly calcified annulus, reducing the possibility of perivalvular leakage.

Conclusion

We have successfully performed mitral valve replacement with a collar-reinforced prosthetic valve in a patient who exhibited massive calcification of the posterior mitral annulus without any complications. We recommend this method as an alternative to conventional mitral valve replacement in the presence of massive mitral annular calcification or disrupted fragile mitral annulus.

References

1. D'Cruz IA, Cohen HC, Prabhu R, Bisla V, Glick G. Clinical manifestations of mitral annulus calcification with emphasis on its echocardiographic features. *Am*

Heart J 1977; **94**: 367–77.
2. Umana E, Ahmed W, Alpert MA. Valvular and perivalvular abnormalities in end-stage renal disease. *Am J Med Sci* 2003; **325**: 237–42.
3. Feindel CM, Tufail Z, David TE, Ivanov J, Armstrong S. Mitral valve surgery in patients with extensive calcification of the mitral annulus. *J Thorac Cardiovasc Surg* 2003; **126**: 777–82.
4. Savage DD, Garrison RJ, Castelli WP, et al. Prevalence of submitral (annular) calcium and its correlates in a general population based sample (the Framingham Study). *Am J Cardiol* 1983; **51**: 1375–8.
5. Cammack PL, Edie RN, Edmunds LH Jr. Bar calcification of the mitral annulus: a risk factor in mitral valve operations. *J Thorac Cardiovasc Surg* 1987; **94**: 399–404.
6. Carpentier AF, Pellerin M, Fuzellier JF, Relland JY. Extensive calcification of the mitral valve annulus: pathology and surgical management. *J Thorac Cardiovasc Surg* 1996; **111**: 718–30.
7. Vander Salm TJ. Mitral annular calcification : a new technique for valve replacement. *Ann Thorac Surg* 1989; **48**: 437–9.
8. McEnany MT. Mitral valve replacement in the presence of severe valvular and annular calcification. *J Card Surg* 1993; **8**: 117–24.
9. Mills NL, McIntosh CL, Mills LJ. Techniques for management of the calcified mitral annulus. *J Card Surg* 1986; **1**: 347–55.
10. Gandjbakhch I, Lascar M, Pavie A, Cabrol C. Intraatrial insertion of a prosthetic mitral valve. *J Cardiovasc Surg (Torino)* 1988; **29**: 113–4.
11. Nataf P, Pavie A, Jault F, Bors V, Cabrol C, Gandjbakhch I. Intraatrial insertion of a mitral prosthesis in a destroyed or calcified mitral annulus. *Ann Thorac Surg* 1994; **58**: 163–7.
12. Ergin MA, Raissi S, Follos F, Lansman SL, Griepp RB. Annular destruction in acute bacterial endocarditis. Surgical techniques to meet the challenge. *J Thorac Cardiovasc Surg* 1989; **97**: 755–63.
13. Coselli JS, Crawford ES. Calcified mitral valve annulus: prosthesis insertion. *Ann Thorac Surg* 1988; **46**: 584–6.