Case Report

Endovascular Stent-grafting for Thoracoabdominal Aortic Aneurysm Following Bypass Grafting to Superior Mesenteric and Celiac Arteries: Report of Two Cases

Kazutoshi Tachibana, MD, Kiyofumi Morishita, MD, Yoshihiko Kurimoto, MD, Johji Fukada, MD, Yoshikazu Hachiro, MD, and Tomio Abe, MD

Two high-risk patients underwent an endovascular stent-grafting for thoracoabdominal aortic aneurysms (TAAA) following bypass-grafting to the visceral arteries. The first patient was a 73-year-old woman with severe ischemic heart disease (IHD) and chronic respiratory failure. The second patient was a 59-year-old woman with myelodysplastic syndromes (MDSs) and hepatic cell carcinoma (HCC). In general, TAAA is not considered to be indicated for endovascular stent-grafting because of the need to revascularize the visceral vessels. However, in some selected cases, such as the two cases presented herein, endovascular stent-grafting combined with bypass-grafting of the visceral arteries can be a feasible and a less-invasive alternative to conventional surgery. (Ann Thorac Cardiovasc Surg 2005; 11: 335–8)

Key words: endovascular stent-grafting, thoracoabdominal aortic aneurysm, celiac artery, superior mesenteric artery, paraplegia

Introduction

Usually, the conventional surgical technique of graft replacement is performed for thoracoabdominal aortic aneurysm (TAAA), but for some high-risk patients it is considered to be too invasive. New endovascular techniques and devices offer an alternative approach to the management of aortic aneurysm and endografting is less invasive and avoids thoracotomy, clamping of the thoracic aorta and circulatory assist and is feasible in high-risk patients. We describe endovascular stent-grafting for TAAA in two patients who had severe ischemic heart disease, cancer and/or pancytopenia. These patients might not have been surgical candidates prior to the emergence of endografting.

From Department of Thoracic and Cardiovascular Surgery, Sapporo Medical University School of Medicine, Sapporo, Japan

Received November 1, 2004; accepted for publication March 22, 2005.
Address reprint requests to Kazutoshi Tachibana, MD: Department of Thoracic and Cardiovascular Surgery, Sapporo Medical University School of Medicine, S1W16 Chuo-ku, Sapporo 060-8543, Japan.

Case Reports

Patient 1

A 73-year-old woman with severe ischemic heart disease and chronic respiratory failure was referred to our institute and diagnosed to have a TAAA. She underwent percuraneous transluminal coronary angioplasty for 100% occlusion of right coronary artery (RCA #2), 75% occlusion of the left anterior descending artery (LAD #9) and 90% occlusion of the circumflex artery (CX #12) eight years ago. Computed tomography(CT) and aortography revealed a Crawford type III TAAA (maximum diameter, 80 mm), involving the celiac artery (CA) and the superior mesenteric arteries (SMA) (Fig. 1A). As the patient refused coronary artery bypass grafting, we performed endovascular stent-graft repair to follow the extra-anatomic reconstruction of visceral vessels urgently. Through a median laparotomy, the CA, the SMA and the bilateral iliac arteries were exposed in preparation for the bypass-grafting. The infra-renal abdominal aorta was used as the donor vessel of inflow for the retrograde visceral bypass graft (Y-shaped Gelseal™: 14×7 mm). The common hepatic artery and the SMA were anastomosed end-to-side to each graft limb, and then the root of the CA and SMA

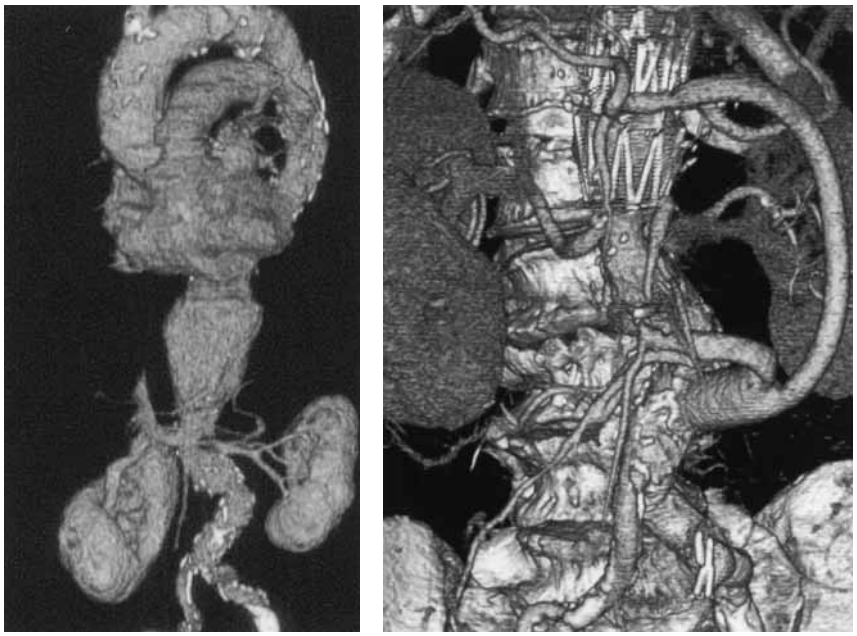

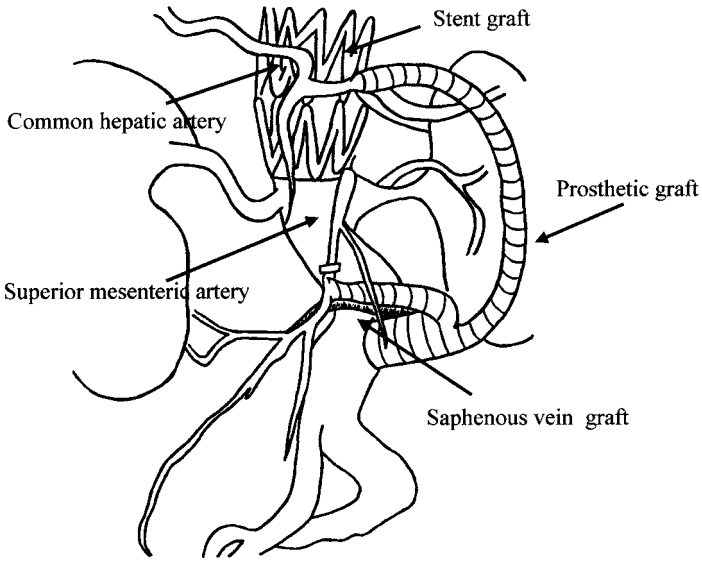

A | B

C

Fig. 1.
A: Preoperative 3-dimensional computed tomography.
B: Postoperative 3-dimensional computed tomography.
C: Illustration of the bypass and position of the stent-graft.

was ligated to prevent retrograde perfusion into the aneurysm sac. The first endografting was then performed. A guide-wire was introduced through the left brachial artery to the graft side limb that was anastomosed to the left common iliac artery as an access conduit for endografting. After exact positioning, the sheath was moved downward and the first stent-graft (hand-made using 34 mm UBE and 40 mm Z stent) was deployed from Th8 level to Th12. The second stent-graft (hand-made using 36 mm UBE and 40 mm Z stent) was deployed from Th12 to the immediate suprarenal portion of the aorta. A final intra-operative digital subtraction angiography (DSA) revealed complete exclusion of the aneurysm and adequate blood flow to the visceral vessels. Four hours after the operation, the lactate level increased to 70 mg/dl, because of kinking of the prosthetic graft to the SMA. Using the saphenous vein, we performed additional bypass-grafting of the SMA. Thereafter, the patient's lactate level promptly returned to normal, with restoration of a good general condition. One week after stent-grafting, 3-dimentional (3D)-CT showed good patency of the bypass grafts and exclusion of the aortic aneurysm by the stent graft (Fig. 1B).

Patient 2

A 59-year-old woman with myelodysplastic syndrome (MDS) and hepatic cell carcinoma (HCC) was admitted to our hospital and diagnosed as having a Crawford type

A | B

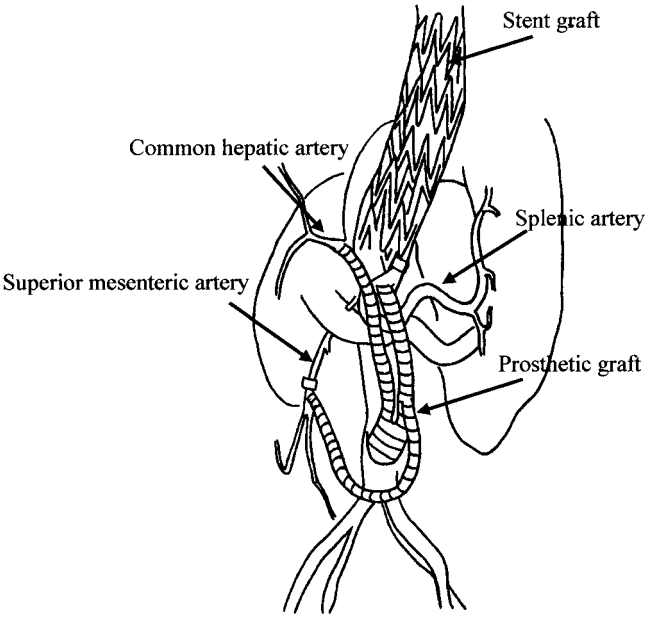

C

Fig. 2.
A: Preoperative 3-dimensional computed tomography.
B: Postoperative 3-dimensional computed tomography.
C: Illustration of the bypass and position of the stent-graft.

IV TAAA (maximum 68 mm of diameter), involving the CA (Fig. 2A). Through a median laparotomy, the CA, the SMA and the bilateral iliac artery were exposed. The infra-renal abdominal aorta was used as the donor vessel of inflow for the retrograde visceral bypass graft (Y-shaped Gelseal™: 14×7 mm). After performing end-to-side anastomoses to the hepatic and the splenic arteries, the first stent-graft (hand-made using 36 mm UBE and 40 mm Z stents) was deployed from Th9 to the immediate supra-SMA portion of the aorta using an 18 Fr long introducer through a 10-mm-diameter prosthetic woven graft anastomosed to the right common iliac artery. Intra-operative DSA indicated a major leakage from the distal side. We then anastomosed the prosthetic graft 6 mm between the SMA and the main trunk of the bifurcated graft. After that, the second stent-graft (hand-made using 36 mm UBE and 40 mm Z stents) was placed from Th11 to L2. A final intra-operative DSA showed complete exclusion of the aneurysm and adequate blood flow to the visceral vessels. The patient was weaned from the ventilator on the day of the operation. Seven days after the stent-graft repair, complete exclusion of the aneurysms and patency of the bypass grafts were confirmed by 3D-CT (Fig. 2B).

Comment

Conventional TAAA repair is one of the most invasive and challenging procedures in the field of vascular surgery.[1,2] Endografting combined with visceral bypass grafting has the potential to expand the indications for surgical repair of TAAA. This method has been used as a means of treating severe calcified TAAA.[3] We performed this procedure for high risk patients who had MDS, HCC, severe ischemic heart disease (IHD) or chronic respiratory failure. In our cases, the infra-renal abdominal aorta was used as the donor vessel of inflow for the retrograde visceral bypass graft with a Y-shaped prosthetic graft. It is considered to be a simple and feasible method for adequate flow to the visceral arteries, confirmed by 3D-CT (Figs. 1B, 2B).

Paraplegia remains the most devastating complication after repairing either a descending thoracic or TAAA. Although endograft repair is a less-invasive treatment for aortic disease, Mitchell et al. reported that the rate of paraplegia after thoracic endografting was 3%.[4] They reported that most of these patients had undergone previous abdominal aortic surgery. Carroccio et al. reported that patients undergoing endovascular repair with no previous abdominal aortic surgery had 0%.[5] In our cases, no paraplegia occurred in either patients. As endografting can avoid clamping of the thoracic aorta, and circulatory assist, it can prevent total spinal cord ischemia and reperfusion injury. Collateral arterial perfusion for the anterior spinal artery is also one of the most important points to prevent paraplegia. Collateral arterial blood supply maintains spinal cord perfusion in the resting state despite the sacrifice of intercostal vessels. Even if a critical portion of an intercostal artery or an entire intercostal artery is sacrificed, the spinal cord may escape ischemia when collateral perfusion is adequate.[2] In our institute, paraplegia and respiratory failure following TAAA operations occurred in 2 (6%) and in 7 (21%) of the 37 patients from 2000 to 2002. On the otherhand, 100 patients underwent stent-grafting for thoracic and abdominal aneurysm from 2001 to 2003. Descending or thoracoabdominal aortic endografting was performed in 70 patients. No paraplegia and respiratory failure occurred and paraparesis occurred in 2.[6] Although embolization and the inability to reperfuse intercostal arteries during endovascular repair remains a significant concern, we believe that the probability of paraplegia in endografting may be lower than that in conventional replacement. Postoperative lung disturbance can also be reduced.

In conclusion, stent-grafting with visceral bypass-grafting is a less-invasive and feasible treatment for TAAA. Improved techniques and a combination of various options will expand the range of indications for surgical repair for TAAA in the future.

References

1. Griepp RB, Ergin MA, Galla JD, et al. Looking for the artery of Adamkiewicz: a quest to minimize paraplegia after operations for aneurysms of the descending thoracic and thoracoabdominal aorta. *J Thorac Cardiovasc Surg* 1996; **112**: 1202–15.
2. Coselli JS. Thoracoabdominal aortic aneurysms: experience with 372 patients. *J Card Surg* 1994; **9**: 638–47.
3. Iguro Y, Yotsumoto G, Ishizaki N, Arata K, Sakata R. Endovascular stent-graft repair for thoracoabdominal aneurysm after reconstruction of the superior mesentric and celiac arteries. *J Thorac Cardiovasc Surg* 2003; **125**: 956–8.
4. Mitchell, RS, Miller DC, Dake MD, Semba CP, Moore KA, Sakai T. Thoracic aortic aneurysm repair with an endovascular stent graft: the “first generation”. *Ann Thorac Surg* 1999; **67**: 1971–80.
5. Carroccio A, Martin ML, Ellozy S, Hollier LH. Pathophysiology of paraplegia following endovascular thoracic aortic aneurysm repair. *J Card Surg* 2003; **18**: 359–66.
6. Kawaharada N, Morishita K, Fukada J, et al. Thoracoabdominal or descending aortic aneurysm repair after preoperative demonstration of the Adamkiewicz artery by magnetic resonance angiography. *Eur J Cardiothorac Surg* 2002; **21**: 970–4.