Original Article

Postoperative Chylothorax in Patients with a Thoracic Aortic Aneurysm

Hiroya Minami, MD, Nobuhiko Mukohara, MD, and Tsutomu Shida, MD

Objectives: Postoperative chylothorax in patients with a thoracic aneurysm is generally infrequent. We report a mode of surgery to reduce the incidence of paraplegia. We review our experience with chylothorax after resection of an aneurysm to find its cause and to evaluate the success of management.

Patients and Methods: For descending thoracic aneurysms, intercostal arteries in the aneurysm were exposed before incising the aneurysm and, they were only sacrificed no change in motor-evoked potentials (MEPs) occurred after temporary occlusion. Between January 2001 and December 2003, out of a total of 147 aneurysms including thoracic and thoracoabdominal, 4 consecutive patients (2.7%) with chylothorax were reviewed.

Results: The chylothorax was diagnosed 1.5 days after operation (range 1 to 2 days). All patients were initially treated by the cessation of oral intake. This treatment was successful for 2 patients and the remaining 2 required surgical intervention to control the fistula. Chylothorax was cured in all patients.

Conclusion: We postulate that chylothorax is caused by injury of the thoracic duct or its branch during the exposing the intercostal arteries. In the management of chylothorax, early intervention is recommended when the volume of chylous fluid is not decreased by conservative treatment. (Ann Thorac Cardiovasc Surg 2006; 12: 116–20)

Key words: chylothorax, aortic aneurysm, thoracic duct, postoperative, motor-evoked potential

Introduction

Chylothorax results in the loss of large amounts of fat and protein and produces a serious state of inanition. The mortality from chylothorax has been between 50 and 100% for years.[1)]

In operation for thoracic aortic aneurysm, a serious complication is paraplegia. To reduce the complication of paraplegia, we modified our surgery, which has decreased the incidence. A further serious complication of chylothorax has also been experienced.

We review our experience with chylothorax aneurysm resection to determine its cause and to evaluate the success of management.

From Department of Cardiovascular Surgery, Himeji Cardiovascular Center, Himeji, Japan

Received July 25, 2005; accepted for publication September 13, 2005.

Address reprint requests to Hiroya Minami, MD: Department of Cardiovascular Surgery, Himeji Cardiovascular Center, 520 Saisho-Ko, Himeji, Hyogo 670-0981, Japan.

Patients and Methods

Between January 2001 and December 2003, 147 aneurysm resections, including thoracic and thoracoabdominal, were performed at our institute. Of these, 4 consecutive patients (2.7%) with postoperative chylothorax were reviewed. These were all men, with a mean age of 73 years (range 65 to 81 years). The medical records of 4 patients were retrospectively reviewed for aneurysm type, location, maximum diameter, age, sex, and preoperative history (Table 1).

The initial operations were performed for thoracic aortic aneurysms in 2 patients and chronic type B dissection in 2. The surgical procedures depended on the location of the diseased aorta. In thoracic aneurysms, left thoracotomy was used in 3 patients and median sternotomy in 1. De-

Table 1. Preoperative clinical features

Patient no., age (years), sex	Type	Location	Diameter (mm)	Initial operation	Concomitant surgery	Past history
1. 80, M	DAIII	Descending aorta	70	Descending aortic replacement		None
2. 81, M	TAA	Descending aorta	60	Descending aortic replacement		AAA, DAIII
3. 67, M	TAA	Distal arch	65	Aortic arch replacement	CABG	None
4. 65, M	DAIII	Descending aorta	57	Descending aortic replacement		DAIII

CABG, coronary artery bypass grafting; RCA, right coronary artery; DAIII, dissecting aneurysm DeBakey type III.

scending aortic replacements were performed in 3 patients and aortic arch replacement in 1. A concomitant procedure of coronary artery bypass grafting was undertaken in 1 patient with a thoracic aneurysm.

Descending aortic replacements were undertaken with hypothermic circulatory arrest and retrograde cerebral perfusion for cerebral protection. We began sacrificing intercostal arteries before incising the aneurysm, preventing backbleeding from open intercostal arteries and potential steal from the anterior spinal artery. In the segment to be resected, the intercostal arteries were carefully exposed to a length of 10 to 15 mm by using the Harmonic Scalpel (Ethicon, Inc., Cincinnati, OH, USA) and temporarily occluded with a Ligaclip (Ethicon Endo-Surgery, Inc., Cincinnati, OH, USA). If no change in motor-evoked potentials (MEPs) occurred within 15 minutes after occlusion, intercostal arteries were subsequently sacrificed.[2)]

In aortic arch replacement, selective cerebral perfusion with hypothermic extracorporeal circulation was used with the modified elephant trunk technique to prevent leakage of the distal anastomosis.

A chest tube was placed in the pleural space after initial operation in all patients. After operation, oral feeding was resumed on the first postoperative day. The diagnosis of chylothorax was established by a milky appearance and the presence of chylomicron in the pleural fluid.

Operative mortality was defined as any death within 30 days of operation or during the same hospitalization.

Results

All patients had a chest drainage tube after their initial operation. All operations were intraoperatively uncomplicated and postoperatively the drainage was serous or faintly bloody until the 1st or 2nd postoperative day (POD) of oral feeding, when chylous material immediately began draining. Oral feeding was discontinued and total parenteral nutrition (TPN) was resumed. In the 1st and 2nd case, the volume of the chest tube drainage had decreased to the point that the patients were allowed an oral diet POD 13 and 11 respectively, when the volume had not increased and the chest tubes were removed. Subsequently, chest roentgenograms had not shown any significant abnormalities.

In the 3rd case, the volume of the chest tube drainage had not diminished. The mean volume of effusion had been about 500 ml/day, and the level of total protein had gone down to 4.3 g/dl and albumin 2.1 g/dl. Pleurodesis with minocycline of 400 mg POD 16 was undertaken, but the chylous fluid did not decrease. Preoperation ligation was undertaken on POD 28. The fistula was found near the distal anastomosis and was successfully occluded. The volume of the chest tube drainage decreased after oral feeding resumed and the chest tube was removed.

In the 4th case, the volume of the chest tube drainage had been over 1,500 ml/day and the level of the total protein had gone down to 4.0 g/dl and albumin 2.8 g/dl. Finally we concluded that the ligation of the injured thoracic duct would be necessary. At reoperations on POD 7, we found one major leakage near the distal anastomosis and ligated it. However, the amount of discharge did not diminish after the ligation. The patient required a second operation due to continued leakage of chyle the next day. The operative findings were injured networks of branches of the thoracic duct around the native aorta. Ligation of one injured branch continuously led to leakage of the other branch. Therefore, we wrapped felt strip around the aorta with the networks of the branch of the thoracic duct and successfully controlled the fistula.

Figs. 1 and 2 show changes over time in volume of chylous fluid and serous protein in these 4 patients. Arrows show the repair of the fistula (Figs. 1 and 2).

Chylothorax was successfully treated in all patients.

Discussion

Chylothorax is accumulations of fluid, characterized by

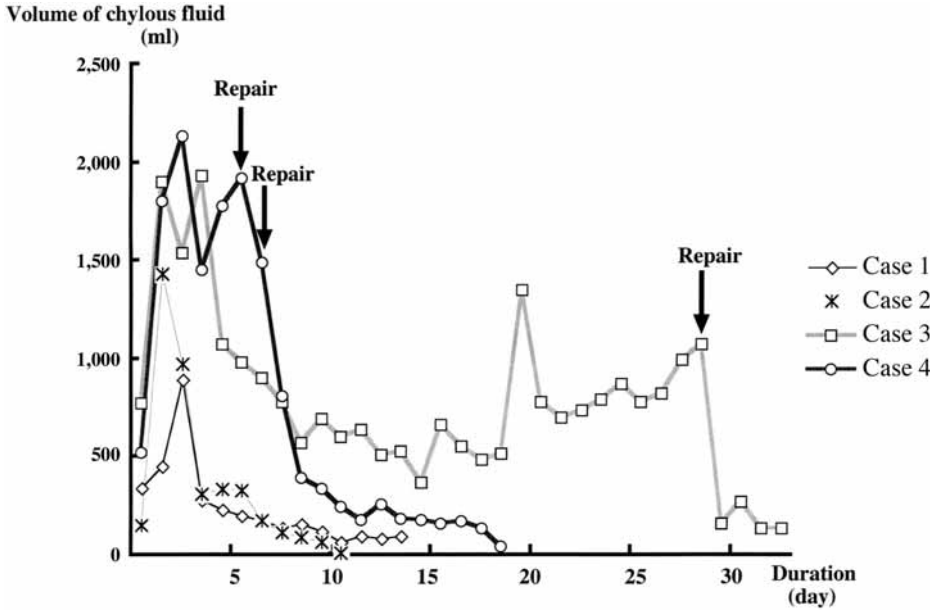

Fig. 1. Changes over time in volume of chylous fluid in 4 patients. Arrows show the repair of the fistula.

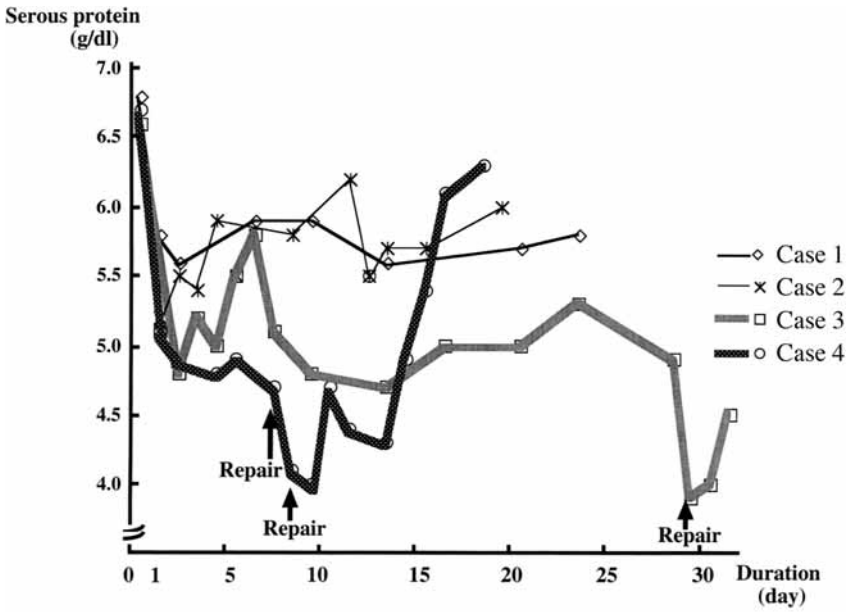

Fig. 2. Changes over time in volume of serous protein in 4 patients. Arrows show the repair of the fistula.

a high triglyceride content and the presence of chylomicrons, in the pleural cavity. Postoperative chylothorax occurs in only 0.2 to 0.5% of patients undergoing thoracic aortic aneurysm repair, but can complicate any cardiovascular operation. It is a life-threatening condition. Valentine et al.[3] reported that, out of 191 patients with chylothorax, the most common cause in 37% was lymphoma and 28% had surgical causes. The incidence of chylothorax was estimated in 0.24 to 0.5% of all intrathoracic operation including vascular, lung, and esophageal surgery,[4-6] although there is no detailed data on limited to post aneurysmectomy in the literature.

Chylothorax is a clinical sign of an internal lymphatic fistula of obstructive or traumatic origin. Chylothorax is uncommon and chyloperitoneum is more uncommon after surgical procedure. The thoracic duct was first described in 1651. A number of variations have been described. The most consistent anatomical variation in the thoracic duct extends from the cisterna chili at the 2nd lumbar vertebra and enters the chest through the aortic hiatus. It lies posterior to the aorta and courses to the right of the spine. It usually crosses the midline between the

6th and 8th thoracic vertebrae and ascends into the left posterior mediastinum. It arches into the superior mediastinum anterolaterally and empties into the left jugulo-subclavian junction.

The thoracic duct transports up to 4 l of chyle per day in a healthy adult.[7] The flow varies considerably with diet. Ingesting fat or water increases lymph flow, while starvation decreases flow to a trickle of clear lymph.[1,8] Because the thoracic duct transports 60 to 70% of ingested fat to the blood stream, the usual concentration of fat is 0.4 to 0.6 mg/dl.[1,3,9] Consequently, a prolonged chylous fistula cannot be tolerated and is associated with significant mortality if not corrected.

After operation, the first clue to the diagnosis is a milky fluid in the pleural fluid. But Staats et al.[10] reported that less than 50% of chylous effusions were serous or serosanguineous. In our cases, a milky appearance of effusion was found at first, thereafter, the effusion became serous after starvation.

We had not experienced chylothorax before 2001, when we had not exposed the intercostal arteries. Thereafter we took the new technique with the use of MEP to prevent paraplegia. Of 4 chylothoraxes, 3 descending aortic replacements were performed using this procedure. In fact the incidence of paraplegia had remarkably decreased since this technique was utilized. However, we believe the thoracic duct or its branches were injured in this procedure and the higher incidence of chylothorax was mainly due to the exposure of the intercostal arteries. Before 2001, we had not exposed intercostal arteries outside of the aneurysm and had not incurred chylothorax. The thoracic duct lies posterior to the aorta and its branches trail over the aorta. The more we exposed around the aorta as well as near the anastomosis, the more risk of chylothorax we had.

About management, 2 of 4 patients had been successfully treated without surgical intervention, while 2 needed reoperation. The decision of when to reoperate is important. Cerfolio et al.[11] and Patterson et al.[12] recommended that reoperation to ligate the thoracic duct was necessary if drainage was still greater than 1,000 ml/day for 7 days. We followed this indication and we reoperated them in the 4th case. We decided to continue the conservative therapy POD 7 because of effusion less than 1,000 ml/day, but the patient, who had experienced effusion of about 500 ml per day for about 3 weeks, needed the reoperation in the end. Additional indications are as follows. Merrigan et al.[7] states; (1) Chyle leak greater than 1,000 ml/ day for more than 5 days. (2) Persistent leak for more than 2 weeks despite conservative management. (3) Nutritional or metabolic complications. (4) Loculated chylothorax, fibrin clots or incarcerated lung.

Throughout the course of the thoracic duct there is an elaborate collateral network of lymphatic vessels. Multiple lymphaticovenous anastomoses may communicate freely with azygos, lumbar, and intercostal veins and the inferior vena cava. These collaterals and anastomoses become functional, which permits ligation at any point.[13] As for the operation, preoperative administration of cream proves useful in locating the site of lymphatic leakage.[3] The leak may then be identified by the characteristic flow of milky fluid. It has been reported the traditional open thoracic or abdominal ligation lead to a success rate of 95% and little morbidity.[1,12,14,15] In the 4th case, we dealt directly with the injured networks of the branch of the thoracic duct around the aorta, but could not easily cure the fistula by ligation. Murphy et al.[16] suggested that the thoracic duct was ligated at the diaphragmatic level. Ligation at the diaphragmatic level has the advantage of stopping flow from any accessory ducts that may not be recognized. It was reported that in the Mayo Clinic the fistula was successfully controlled in 92.2% with the first reoperations.[11]

During prolonged chyle loss, the body's reserve protein (in particular albumin), fat, and electrolytes are depleted. This hypoalbminaemia increase the risk of bacterial and viral sepsis.[17] In our study, the protein level of patients with ligation (cases 3 and 4) declined below 4 g/dl, where cases 1 and 2 who did not undergo reoperation had levels above 5 g/dl. From a nutritional viewpoint, cases 3 and 4 needed ligation reoperations as soon as possible.

Conclusion

The change of surgery for the thoracic aortic aneurysm with the use of MEP remarkably decreased the incidence paraplegia in spite of another morbidity of chylothorax. We will use this excellent technique of MEP until an alternative method of preventing critical paraplegia is established, bearing in mind that exposing the intercostal arteries may injury the thoracic duct. It is our firm belief that the paraplegia once occurring will never be successfully treated, however, chylothorax can be completely cured with medical or even surgical methods, as we have demonstrated in this study. In the management of chylothorax, early intervention is recommended when the volume of chylous fluid is not decreased by conservative treatment.

References

1. Robinson CL. The management of chylothorax. *Ann Thorac Surg* 1985; **39**: 90–5.
2. Meylaerts SA, Jacobs MJ, van Iterson V, De Haan P, Kalkman CJ. Comparison of transcranial motor evoked potentials and somatosensory evoked potentials during thoracoabdominal aortic aneurysm repair. *Ann Surg* 1999; **230**: 742–9.
3. Valentine VG, Raffin TA. The management of chylothorax. *Chest* 1992; **102**: 586–91.
4. Higgins CB, Mulder DG. Chylothorax after surgery for congenital heart disease. *J Thorac Cardiovasc Surg* 1971; **61**: 411–8.
5. Cevese PG, Vecchioni R, D'Amico DF, et al. Postoperative chylothorax. Six cases in 2,500 operations, with a survey of the world literature. *J Thorac Cardiovasc Surg* 1975; **69**: 966–71.
6. Ferguson MK, Little AG, Skinner DB. Current concepts in the management of postoperative chylothorax. *Ann Thorac Surg* 1985; **40**: 542–5.
7. Merrigan BA, Winter DC, O'Sullivan GC. Chylothorax. *Br J Surg* 1997; **84**: 15–20.
8. Sassoon CS, Light RW. Chylothorax and pseudochylothorax. *Clin Chest Med* 1985; **6**: 163–71.
9. Bessone LN, Ferguson TB, Burford TH. Chylothorax. *Ann Thorac Surg* 1971; **12**: 527–50.
10. Staats BA, Ellefson RD, Budahn LL, Dines DE, Prakash UB, Offord K. The lipoprotein profile of chylous and nonchylous pleural effusions. *Mayo Clin Proc* 1980; **55**: 700–4.
11. Cerfolio RJ, Allen MS, Deschamps C, Trastek VF, Pairolero PC. Postoperative chylothorax. *J Thorac Cardiovasc Surg* 1996; **112**: 1361–6.
12. Patterson GA, Todd TR, Delarue NC, Ilves R, Pearson FG, Cooper JD. Supradiaphragmatic ligation of the thoracic duct in intractable chylous fistula. *Ann Thorac Surg* 1981; **32**: 44–9.
13. Macfarlane JR, Holman CW. Chylothorax. *Am Rev Respir Dis* 1972; **105**: 287–91.
14. Paes ML, Powell H. Chylothorax: an update. *Br J Hosp Med* 1994; **51**: 482–90.
15. Miyamura H, Watanabe H, Eguchi S, Suzuki T. Ligation of the thoracic duct through transabdominal phrenotomy for chylothorax after heart operations. *J Thorac Cardiovasc Surg* 1994; **107**: 316.
16. Murphy TO, Piper CA. Surgical management of chylothorax. *Am Surg* 1977; **43**: 715–8.
17. Puntis JW, Roberts KD, Handy D. How should chylothorax be managed? *Arch Dis Child* 1987; **62**: 593–6.