

# FDG-PET Imaging for Lymph Node Staging and Pathologic Tumor Response after Neoadjuvant Treatment of Non-small Cell Lung Cancer

Takashi Ohtsuka, MD,<sup>1</sup> Hiroaki Nomori, MD,<sup>1</sup> Akinori Ebihara, MD,<sup>2</sup>  
Ken-ichi Watanabe, MD,<sup>1</sup> Masahiro Kaji, MD,<sup>1</sup> Tsuguo Naruke, MD,<sup>1</sup>  
Keiichi Suemasu, MD,<sup>1</sup> and Kimiichi Uno, MD<sup>3</sup>

**Purpose:** A number of studies have demonstrated that <sup>18</sup>F-fluorodeoxyglucose positron emission tomography (FDG-PET) is effective for staging of lung cancer. However, the efficacy of FDG-PET for staging lung cancer after neoadjuvant treatment is still controversial. This study compared FDG-PET and computed tomography (CT) for lung cancer staging, and evaluated the ability of the two methods to predict the pathologic response of the primary tumor to neoadjuvant treatment.

**Patients and Methods:** Twenty-two patients who underwent neoadjuvant treatment followed by surgery were investigated. Eighteen patients received chemoradiotherapy and four patients received chemotherapy only. One hundred and three lymph node stations in the 22 patients were evaluated by FDG-PET and CT. The pathologic responses of the tumors were compared by FDG-uptake and tumor size on CT for the 15 patients who underwent FDG-PET and CT both before and after neoadjuvant treatment.

**Results:** There was no significant difference in the ability of FDG-PET or CT to predict residual viable tumor. Although positive predictive value by FDG-PET (0.29) was lower than that by CT (0.64) ( $p=0.04$ ) in the mediastinal lymph nodes, there were no statistically significant differences in the other results of lymph nodes by FDG-PET and CT. Both decrease in FDG-uptake and decrease in tumor size by CT after neoadjuvant treatment correlated significantly with pathologic response in the 15 patients ( $p=0.003$  and  $0.009$ , respectively).

**Conclusion:** FDG-PET did not appear to offer any advantages over CT for lymph node staging or for predicting the pathologic response after neoadjuvant treatment of non-small cell lung cancer. (*Ann Thorac Cardiovasc Surg* 2006; 12: 89–94)

**Key words:** lung cancer, positron emission tomography, neoadjuvant treatment, pathologic response

## Introduction

It is generally accepted that multimodal therapy should be used for the treatment of locally advanced non-small

*From Departments of <sup>1</sup>Thoracic Surgery and <sup>2</sup>Internal Medicine, Saiseikai Central Hospital, and <sup>3</sup>Nishidai Clinic, Tokyo, Japan*

Received August 29, 2005; accepted for publication September 12, 2005.

Address reprint requests to Takashi Ohtsuka, MD: Department of Thoracic Surgery, Saiseikai Central Hospital, 1-4-17 Mita, Minato-ku, Tokyo 108-0073, Japan.

cell lung cancer. Neoadjuvant treatment followed by surgery is one type of multimodal therapy used for locally advanced non-small cell lung cancer.<sup>1)</sup> Several studies have demonstrated that <sup>18</sup>F-fluorodeoxyglucose positron emission tomography (FDG-PET) is effective for staging of lung cancer.<sup>2-5)</sup> However, the staging of lung cancer after neoadjuvant treatment remains difficult. This study was undertaken to evaluate the usefulness of FDG-PET for staging and predicting the pathologic tumor response to neoadjuvant treatment in 22 patients with non-small cell lung cancer, in comparison with the results of

**Table 1. Characteristics of patients**

Patient	Age	Sex	Histology	Neoadjuvant treatment	Pathologic stage	Effect
1	49	M	AD	C+R	T3N2	Partial response
2	52	M	SQ	C+R	T1N0	Partial response
3	36	M	AD	C+R	T2N0	Partial response
4	63	M	SQ	C+R	T1N0	Partial response
5	67	F	AD	C	T2N1	Partial response
6	70	M	SQ	C+R	T2N0	Partial response
7	74	M	SQ	C+R	T3N1	Partial response
8	64	M	SQ	C+R	T0N0	Partial response
9	65	M	SQ	C	T1N1	Partial response
10	64	M	AD	C+R	T1N3	Partial response
11	64	M	AD	C+R	T0N0	Partial response
12	63	M	SQ	C+R	T1N2	Partial response
13	59	F	AD	C+R	T2N1	No change
14	62	F	AD	C+R	T2N3	No change
15	53	M	AD	C+R	T1N1	No change
16	65	M	SQ	C	T1N2	No change
17	71	M	AD	C+R	T2N0	No change
18	68	F	AD	C	T2N1	No change
19	61	M	AD	C+R	T2N2	No change
20	66	M	AD	C+R	T4N2	No change
21	57	M	AD	C+R	T1N2	No change
22	65	M	AD	C+R	T2N2	No change

AD, adenocarcinoma; SQ, squamous cell carcinoma; C, chemotherapy; R, radiation therapy.

computed tomography (CT).

## Patients and Methods

Between December 2001 and September 2004, whole-body FDG-PET and CT scans of the chest were undertaken after induction treatment in 22 patients with biopsy-proven lung cancer. Of the 22 patients, 15 underwent FDG-PET and CT both before and after neoadjuvant treatment and the other seven patients underwent FDG-PET only after neoadjuvant treatment. The characteristics of the patients are shown in Table 1. There were 18 men and four women with a mean age of 61 years (range: 36-74 years). Preoperative chemotherapy was administered to all patients. Sixteen patients were administered carboplatin and vinorelbine, two were given carboplatin and docetaxel, two received carboplatin and paclitaxel, and one patient each received cisplatin and CPT-11, and carboplatin and gemcitabine. The mean number of courses was 2.3 (range: 1-6). Four patients received chemotherapy only, and 18 received both radiotherapy and chemotherapy. Seventeen patients received 30 Gy of chest irradiation and one patient received 60 Gy. The time interval between the end of neoadjuvant treatment and FDG-PET was a median of 1.6 months (range: 1-11 months). All

patients underwent pulmonary resection and systematic thoracic lymph node dissection. The lymph node stations were classified according to the original lymph node map of lung cancer.<sup>6)</sup> The pathologic diagnosis of 103 lymph node stations (N1=24, N2=72, N3=7) in the 22 patients was compared by lymph node staging with FDG-PET and CT.

## FDG-PET scanning and data analysis

Patients were instructed to fast for at least 4 hr prior to intravenous (IV) administration of <sup>18</sup>F-FDG. The administered dosage of <sup>18</sup>F-FDG was 125  $\mu$ Ci/kg (4.6 MBq/kg) body weight for non-diabetic patients and 150  $\mu$ Ci/kg (5.6 MBq/kg) body weight for diabetic patients. PET imaging was performed approximately 60 min after IV administration of FDG using a POSICAM.HZL mPOWER (Positron Corp., Houston, Texas, USA). No-attenuation-corrected emission scans were initially obtained in two-dimensional, high-sensitivity mode for 4 min per bed position, and taken from the skull to the thighs. Immediately thereafter, a two-bed-position attenuation-corrected examination was performed, with 6 min for the emission sequence and 6 min for the transmission sequence at each bed position. The images were usually reconstructed in a 256 $\times$ 256 matrix using ordered subset

expectation maximization corresponding to a pixel size of 4×4 mm, with section spacing of 2.66 mm.

PET data were evaluated semiquantitatively on the basis of the contrast ratio (CR) obtained as reported previously. Briefly, the regions of interest (ROIs) were chosen in the nodules or lymph nodes and cerebellum. The highest activities in the tumor or lymph node ROI (T or L) and in the cerebellum ROI (C) were measured. The CR was calculated by T/C in each nodule or L/C in each lymph node as an index of FDG-uptake. The primary tumors or lymph nodes with a CR  $\geq 0.25$  were diagnosed as having a viable tumor as reported previously.<sup>7)</sup> The decrease in CR after neoadjuvant treatment was calculated using the following formula: CR after neoadjuvant treatment/CR before neoadjuvant treatment.

### CT scanning and CT data analysis

Spiral CT was performed using a ProSeed SA (General Electric Health care, Milwaukee, Wisconsin, USA). The entire thorax was scanned in 1-cm-thick sections with maximal inspiration. World Health Organization (WHO) response criteria were used for efficacy analysis of the tumor.<sup>8)</sup> The criterion of CT definition for suspected metastasis of the lymph node was a short-axis diameter of 1 cm or larger. The area of the tumor was calculated as the multiplication of the longest diameter and the shortest diameter. The decrease in tumor area on CT after neoadjuvant treatment was calculated using the following formula: tumor area after neoadjuvant treatment/tumor area before neoadjuvant treatment.

### Pathologic response

Pathologic response was defined according to the article of The Japan Lung Cancer Society.<sup>9)</sup> A major pathologic response was defined as a residual tumor less than one-third the size of the original tumor. A minor pathologic response was defined as residual tumor greater than or equal to one-third of the original tumor. The pathologic response was determined by comparing the ratios of FDG-uptake and tumor area on CT before and after neoadjuvant treatment in the 15 available patients.

### Statistical analysis

True positive (TP), true negative (TN), false positive (FP) and false negative (FN) results of PET for residual tumor and lymph nodes were compared with the results of pathologic diagnosis. Sensitivity was calculated as TP/TP+FN, specificity as TN/TN+FP, positive predictive values (PPV) as TP/TP+FP, negative predictive values (NPV) as TN/

**Table 2. FDG-PET, CT, and residual viable tumor cells in the primary site**

	Viable tumor cells	
	+	-
PET positive	16	2
PET negative	4	0
CT positive	20	2
CT negative	0	0

FDG-PET, <sup>18</sup>F-fluorodeoxyglucose positron emission tomography; CT, computed tomography.

TN+FN and accuracy as TP+TN/total. The differences between major pathologic response and minor pathologic response of the tumor by FDG-uptake and size on CT were examined by the Mann-Whitney *U* test. The data obtained by FDG-PET and CT were compared by the chi-squared test. The data were considered statistically significant at  $p < 0.05$ . All values are expressed as the mean  $\pm$  SD.

## Results

### Detection of residual viable tumor at the primary site

While the effects of neoadjuvant treatment determined by CT were partial response in 12 and no change in 10 (Table 1), pathologic examination of the resected tumor showed that there were no viable cells in two patients. The results of the correlation between FDG-PET, CT and viable tumor cells are shown in Table 2. There were 16 patients with TP, four with FN and two with FP results by FDG-PET, 20 patients with TP and two patients with FP results by CT. There were no significant differences in the results of FDG-PET and CT.

### Lymph node staging with PET and CT

A comparison of clinical (after neoadjuvant treatment) and pathologic lymph node status determined by FDG-PET and CT is shown in Table 3. FDG-PET and CT accurately predicted nodal status in 11 (50%) and 10 patients (45%), respectively. A comparison of clinical and pathologic node status in N1, N2 and N3 stations determined by FDG-PET and CT is shown in Table 4. Sensitivity, specificity, PPV, NPV and accuracy of FDG-PET and CT are summarized in Tables 5 and 6. PPV by FDG-PET (0.29) was significantly lower than that by CT (0.64) ( $p = 0.04$ ) in the N2 lymph node stations. However, there were no significant differences in the other results of FDG-PET and CT.

**Table 3. Comparison of clinical and pathological nodal status by FDG-PET and CT**

PET	Pathological nodal status			
	N0	N1	N2	N3
N0	5	2	2	0
N1	0	1	1	0
N2	2	3	4	1
N3	0	0	0	1

CT	Pathological nodal status			
	N0	N1	N2	N3
N0	5	2	2	0
N1	0	1	1	0
N2	2	3	4	2
N3	0	0	0	0

FDG-PET, <sup>18</sup>F-fluorodeoxyglucose positron emission tomography; CT, computed tomography.

**Table 4. Comparisons between clinical and pathologic nodal status with FDG-PET and CT**

		Lymph node metastasis	
		+	-
N1 station (n=24)	PET positive	4	5
	PET negative	1	14
	CT positive	2	1
	CT negative	3	18
N2 station (n=72)	PET positive	8	20
	PET negative	6	38
	CT positive	7	4
	CT negative	7	54
N3 station (n=7)	PET positive	2	0
	PET negative	2	3
	CT positive	0	0
	CT negative	4	3

FDG-PET, <sup>18</sup>F-fluorodeoxyglucose positron emission tomography; CT, computed tomography.

**Table 5. The sensitivity, specificity, positive predictive value (PPV), negative predictive value (NPV) and accuracy for lymph node staging by FDG-PET after neoadjuvant treatment**

Test	N1 lymph nodes	N2 lymph nodes	N3 lymph nodes	All lymph nodes
Sensitivity	0.80	0.57	0.50	0.61
Specificity	0.74	0.66	1.00	0.69
PPV	0.44	0.29	1.00	0.36
NPV	0.93	0.86	0.60	0.86
Accuracy	0.75	0.64	0.71	0.67

PPV, positive predictive value; NPV, negative predictive value; FDG-PET, <sup>18</sup>F-fluorodeoxyglucose positron emission tomography.

**Table 6. The sensitivity, specificity, positive predictive value (PPV), negative predictive value (NPV) and accuracy for lymph node staging by CT after neoadjuvant treatment**

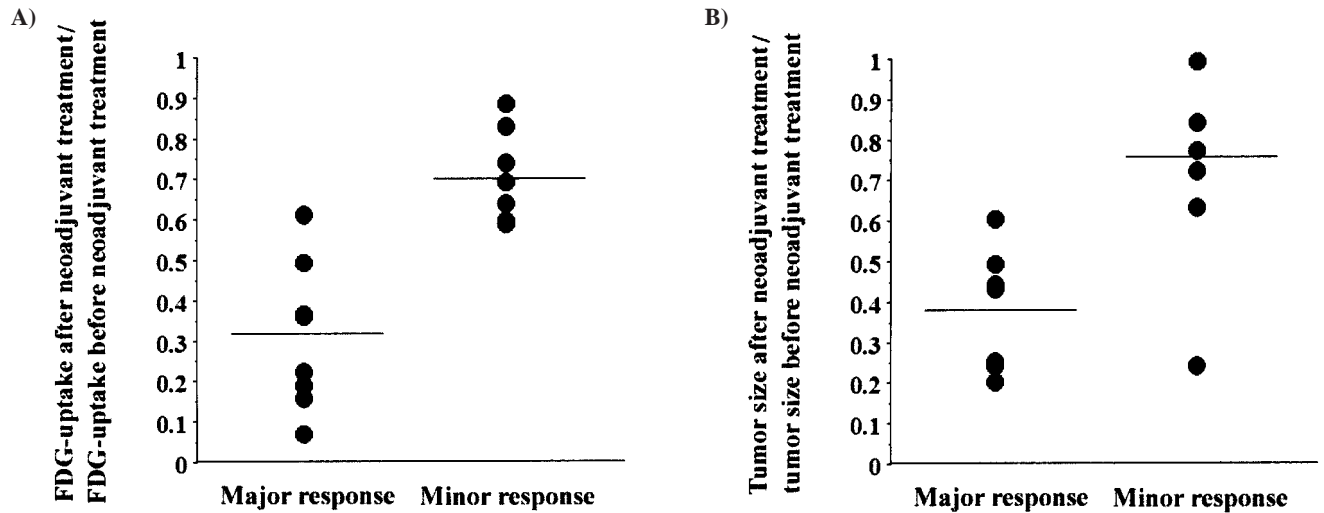
Test	N1 lymph nodes	N2 lymph nodes	N3 lymph nodes	All lymph nodes
Sensitivity	0.40	0.50	0.00	0.39
Specificity	0.95	0.93	1.00	0.94
PPV	0.67	0.64	0.00	0.64
NPV	0.86	0.89	0.43	0.84
Accuracy	0.83	0.85	0.43	0.82

PPV, positive predictive value; NPV, negative predictive value; CT, computed tomography.

### Pathologic response

In the 15 patients who underwent FDG-PET before and after neoadjuvant treatment, the ratios of FDG-uptake before and after neoadjuvant treatment in the major pathologic response patients ( $0.34 \pm 0.19$ ) were significantly lower than those in the minor response patients ( $0.73 \pm 0.10$ ) ( $p=0.003$ ) (Fig. 1A). The ratios of tumor size

on CT before and after neoadjuvant treatment in the major pathologic response patients ( $0.39 \pm 0.15$ ) were also significantly lower than those in the minor pathologic response group ( $0.78 \pm 0.25$ ) ( $p=0.009$ ) (Fig. 1B). There was no significant difference in the ability of FDG-uptake or tumor size on CT to predict pathologic response.



**Fig. 1.**  
**A:** Distributions of the ratios of FDG-uptake in patients with a major and a minor pathologic response. The ratios of FDG-uptake in patients with a major pathologic response ( $0.34 \pm 0.19$ ) were significantly lower than those in the group with minor pathologic response ( $0.73 \pm 0.10$ ) ( $p=0.003$ ).  
**B:** Distributions of the ratios of the size in patients with a major and a minor pathologic response. The ratios of tumor size in patients with a major pathologic response ( $0.39 \pm 0.15$ ) were also significantly lower than those in the group with minor pathologic response ( $0.78 \pm 0.25$ ) ( $p=0.009$ ).

**Discussion**

Surgical resection has limited success in curing locally advanced non-small cell lung cancer. Recently, combined modality treatment for locally advanced non-small cell lung cancer has been performed.<sup>2)</sup> However, accurate staging of lung cancer is still difficult after neoadjuvant treatment.<sup>10-12)</sup> FDG-PET, which does not use the criterion of size, might be more accurate for detecting the actual presence of tumor in the lymph nodes than CT. In mediastinal lymph node staging of lung cancer without neoadjuvant treatment, sensitivity and specificity are reported to be 0.71-0.91 and 0.67-0.94, respectively.<sup>2-4,13)</sup> Several studies have shown good results for FDG-PET for the staging of lung cancer, even in patients who had received neoadjuvant treatment.<sup>14-16)</sup> Akhurst et al. reported that FDG-PET could accurately detect residual viable primary tumor,<sup>15)</sup> and Cerfolio et al. showed that FDG-PET had a higher PPV and NPV than CT for detecting residual tumor and paratracheal lymph nodes in patients who had received preoperative chemotherapy.<sup>16)</sup> On the other hand, Port et al. reported that FDG-PET did not accurately predict nodal stage after neoadjuvant treatment.<sup>17)</sup>

The current study showed that FDG-PET had a low PPV (0.29) when diagnosing mediastinal lymph nodes after neoadjuvant treatment. There were 20 FP lymph

nodes (28%) among the 72 N2 lymph nodes. This poor result is thought to be due to inflammatory lesions with invasion of macrophages and lymphocytes in the lymph nodes caused by chemotherapy or radiation therapy. These lesions may be responsible for the increased uptake of FDG and the FP findings reported previously.<sup>18)</sup>

Port et al. showed that FDG-PET did not reliably predict pathologic response to preoperative chemotherapy in non-small cell lung cancer.<sup>17)</sup> However, the current study demonstrates that the FDG-uptake of the primary tumor before and after neoadjuvant treatment was a good predictor of pathologic response of the tumor. We defined a major pathologic response as ‘residual tumor less than one-third the size of the primary tumor’. According to this definition, FDG-uptake could reflect the pathologic response of the primary tumor.

Lymph node downstaging of locally advanced non-small cell lung cancer by neoadjuvant treatment correlates with long-term survival.<sup>19,20)</sup> FDG-PET did not offer any advantages over CT in the mediastinal lymph node and could not predict the lymph node downstaging of non-small cell lung cancer patients who received neoadjuvant treatment. Therefore, surgical intervention such as endoscopic biopsy or mediastinoscopy will be needed for accurate staging, since surgery after induction treatment is beneficial only in patients with pathologic downstaging.

## References

- Rosell R, Gomez-Codina J, Camps C, et al. A randomized trial comparing preoperative chemotherapy plus surgery with surgery alone in patients with non-small-cell lung cancer. *N Engl J Med* 1994; **330**: 153–8.
- Dwamena BA, Sonnad SS, Angobaldo JO, Wahl RL. Metastases from non-small cell lung cancer: mediastinal staging in the 1990s—meta-analytic comparison of PET and CT. *Radiology* 1999; **213**: 530–6.
- Gupta NC, Tamim WJ, Graeber GG, Bishop HA, Hobbs GR. Mediastinal lymph node sampling following positron emission tomography with fluorodeoxyglucose imaging in lung cancer staging. *Chest* 2001; **120**: 521–7.
- Albes JM, Dohmen BM, Schott U, Schulen E, Wehrmann M, Ziemer G. Value of positron emission tomography for lung cancer staging. *Eur J Surg Oncol* 2002; **28**: 55–62.
- Nomori H, Watanabe K, Ohtsuka T, Naruke T, Suemasu K, Uno K. The size of metastatic foci and lymph nodes yielding false-negative and false-positive lymph node staging with positron emission tomography in patients with lung cancer. *J Thorac Cardiovasc Surg* 2004; **127**: 1087–92.
- Naruke T, Suemasu K, Ishikawa S. Lymph node mapping and curability at various levels of metastasis in resected lung cancer. *J Thorac Cardiovasc Surg* 1978; **76**: 832–9.
- Nomori H, Watanabe K, Ohtsuka T, Naruke T, Suemasu K, Uno K. Visual and semiquantitative analyses for F-18 fluorodeoxyglucose PET scanning in pulmonary nodules 1 cm to 3 cm in size. *Ann Thorac Surg* 2005; **79**: 984–9.
- WHO Handbook for Reporting Results of Cancer Treatment. Geneva: WHO, 1979.
- The Japan Lung Cancer Society. General Rules for Clinical and Pathologic Recording of Lung Cancer, 6th ed. Tokyo: Kanehara, 2003. (in Jpse.)
- Lee KS, Shim YM, Han J, et al. Primary tumors and mediastinal lymph nodes after neoadjuvant concurrent chemoradiotherapy of lung cancer: serial CT findings with pathologic correlation. *J Comput Assist Tomogr* 2000; **24**: 35–40.
- Mateu-Navarro M, Rami-Porta R, Bastus-Piulats R, Cirera-Nogueras L, Gonzalez-Pont G. Remediastinoscopy after induction chemotherapy in non-small cell lung cancer. *Ann Thorac Surg* 2000; **70**: 391–5.
- Van Schil P, van der Schoot J, Poniewierski J, et al. Remediastinoscopy after neoadjuvant therapy for non-small cell lung cancer. *Lung Cancer* 2002; **37**: 281–5.
- Hellwig D, Ukena D, Paulsen F, Bamberg M, Kirsch CM, Onko-PET der Deutschen Gesellschaft für Nuklearmedizin. [Meta-analysis of the efficacy of positron emission tomography with F-18-fluorodeoxyglucose in lung tumors. Basis for discussion of the German Consensus Conference on PET in Oncology 2000]. *Pneumologie* 2001; **55**: 367–77.
- Vansteenkiste JF, Stroobants SG, De Leyn PR, Dupont PJ, Verbeken EK. Potential use of FDG-PET scan after induction chemotherapy in surgically staged IIIA-N2 non-small-cell lung cancer: a prospective pilot study. The Leuven Lung Cancer Group. *Ann Oncol* 1998; **9**: 1193–8.
- Akhurst T, Downey RJ, Ginsberg MS, et al. An initial experience with FDG-PET in the imaging of residual disease after induction therapy for lung cancer. *Ann Thorac Surg* 2002; **73**: 259–66.
- Cerfolio RJ, Ojha B, Mukherjee S, Pask AH, Bass CS, Katholi CR. Positron emission tomography scanning with 2-fluoro-2-deoxy-d-glucose as a predictor of response of neoadjuvant treatment for non-small cell carcinoma. *J Thorac Cardiovasc Surg* 2003; **125**: 938–44.
- Port JL, Kent MS, Korst RJ, Keresztes R, Levin MA, Altorki NK. Positron emission tomography scanning poorly predicts response to preoperative chemotherapy in non-small cell lung cancer. *Ann Thorac Surg* 2004; **77**: 254–9.
- Ohtsuka T, Nomori H, Watanabe K, et al. False-positive findings on <sup>18</sup>F-FDG-PET caused by non-neoplastic cellular elements after neoadjuvant chemoradiotherapy for non-small cell lung cancer. *Jpn J Clin Oncol* 2005; **35**: 271–3.
- Betticher DC, Hsu Schmitz SF, Totsch M, et al. Mediastinal lymph node clearance after docetaxel-cisplatin neoadjuvant chemotherapy is prognostic of survival in patients with stage IIIA pN2 non-small-cell lung cancer: a multicenter phase II trial. *J Clin Oncol* 2003; **21**: 1752–9.
- Trodella L, Granone P, Valente S, et al. Neoadjuvant concurrent radiochemotherapy in locally advanced (IIIA-IIIB) non-small-cell lung cancer: long-term results according to downstaging. *Ann Oncol* 2004; **15**: 389–98.