Case Report

Thoracoscopic Findings and Surgical Management of Catamenial Hemopneumothorax

Yoshio Tsunezuka, MD, PhD,[1] Makoto Oda, MD, PhD,[1] Hideki Moriyama, MD,[1] Masahiro Ohshima, MD,[1] and Hiroshi Kurumaya, MD, PhD[2]

A 43-year-old woman had experienced recurrent right pneumothoraces at the beginning of her menstrual period. Thoracoscopically, multiple small fenestrations were widely found over the tendinous part of the diaphragm. Multiple purple colored nodules were seen on the visceral surface of upper lobe containing intralobar lesions, and about 100 ml blood was pooled in the thoracic space. We performed a video-assisted thoracoscopic resection of the pleural nodule suspected to be the cause of the hemothoraces. Histologically, the resected nodule had intra-alveolar hemorrhage not seen in common endometriosis. Pleurodesis with mechanical abrasion of parietal pleura and the diaphragm was performed. Chemical pleurodesis, with minocycline hydrochloride and distilled water was applied. (Ann Thorac Cardiovasc Surg 2006; 12: 197–9)

Key words: catamenial hemopneumothorax, video-assisted thoracoscopic surgery, pleurodesis

Introduction

Catamenial pneumothorax (CPT) is a rare entity of spontaneous, recurring pneumothorax in women. Among them, catamenial hemothorax (CHT) or catamenial hemopneumothorax (CHPT) is a further rare entity. We report on a patient with CHPT, and the thoracoscopic findings of subpleural multiple hemorrhages.

Case Report

A 43-year-old woman had had an oophorocystectomy 5 years previously. Abdominal endometriosis was not confirmed at operation. She had been treated with thoracic tube drainage for spontaneous pneumothorax twice and had complained of right chest pain on day 2 of menstruation. She developed right thoracic pain and productive cough at the beginning of her menstrual periods. She had had 3 full-term pregnancies, with one normal delivery and 2 Caesarean sections, and her menstrual cycle was regular. She did not smoke or drink or have a history of trauma and associated lung disease. On chest roentgenogram, a right apical pneumothorax was noted. Chest computed tomography did not show any pleural blebs or bullae in the lung. Serum CA 125, a gynecologic tumor marker, was not elevated at 16.9 U/ml (<40 U/ml; premenopausal women) on day 5 of menstruation. CPT was suspected with the presence of these clinical findings. For definitive diagnosis and treatment, video-assisted thoracoscopic surgery was performed on day 7 of menstruation. A thoracoscope was inserted in the right mid-axillary in the 5th intercostal space. About 100 ml hemorrhage pleural effusion was seen in the thoracic space. On the inner, tendinous part of the diaphragm, multiple small fenestrations were widely found (Fig. 1). Multiple purple colored nodules were seen on the surface of the upper lobe containing intralobar lesions (Fig. 2). No bullae or blebs of the lung were seen thoracoscopically. For histological diagnosis, partial resection of the right lung containing one nodule 1.0 cm in diameter was performed with an ETS flex 45-green stapler (Ethicon. Endo-Surgery, Inc., Cincinnati, OH, USA). Pleurodesis with mechanical abrasion of the parietal pleura near the diaphragm, the diaphragmatic surface and basal surface of

From Departments of [1]General Thoracic Surgery and [2]Pathology, Ishikawa Prefectural Central Hospital, Kanazawa, Japan

Received October 31, 2005; accepted for publication December 8, 2005.
Address reprint requests to Yoshio Tsunezuka, MD, PhD: Department of General Thoracic Surgery, Ishikawa Prefectural Central Hospital, 2-1 Kuratsuki-higashi, Kanazawa, Ishikawa 920-8530, Japan.

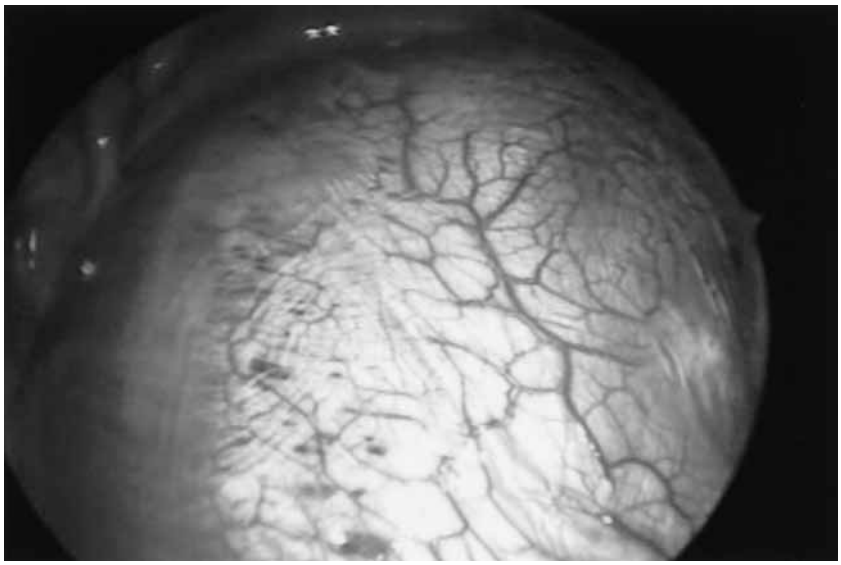

Fig. 1. Multiple fenestrations were found on the tendinous part of diaphragm.

lung was performed using folded gauze and an Endopass Cherry Dissector (BCD10, Ethicon Endo-Surgery, Inc., Cincinnati, OH, USA). As chemical pleurodesis, minocycline hydrochloride 100 mg and distilled water were used. The patient had an uneventful recovery. Postoperative histological study revealed intra-alveolar hemorrhage without endometrial tissues or mullerian metaplastic changes.

Discussion

CPT was described for the first time in 1958,[1] and named "catamenial pneumothorax" by Lillington in 1972.[2] CPT is a recurrent syndrome of pneumothorax that occurs between 48 and 72 hours after menstruation. Clinical features of CPT prevail in multiparous women in their 30s, and is almost exclusively right sided affected in 90-95% of cases,[3] represents 2.8-5.6% of spontaneous pneumothorax in women.[4]

The cause of CHT is not exactly known, but thought to be due to desquamated endometriosis of pleural lesions induced to hemothorax by destruction of visceral pleura and intrapulmonary vessels.[5]

Thoracoscopy is a very useful diagnostic tool for CPT. The main intraoperative findings in the reported 140 cases of CPT were of pleural endometriosis in 29.6% of the patients, diaphragmatic lesions in 38.8%, and bullae, blebs or scarring in 23.1%; no lesions were reported in 8.5% of the patients.[6] The thoracoscopic findings of diaphragmatic involvement are characteristic, scattered blue berry or cherry red colored patches or fenestrations on the tendinous portion of diaphragm,[6,7] while visceral pleural lesions vary. These nodules in the present case were about 1.0 cm in size but the case reported by Bhatia et al.[8] had multiple scattered small chocolate-colored cystic implants. Endometriosis was not pathologically proven in the present case. Pathological evidence of thoracic endometriosis is demonstrated in about 30% of cases.[9] Endometrial tissues retract and change through the menstrual cycle. Therefore, there is little significance in the histology of the lesions regarding pathological evidence of endometriosis after a deciduation of endometrial tissue.

The etiology and pathogenesis have not been established clearly.[1-5] Several theories on the pathogenesis of this entity have been suggested: (1) loss of cervical mucus during the menstrual phase assisting movement of air into the peritoneum, through the diaphragmatic fenestrations; (2) elevated prostaglandin F2 and platelet factor 2α in the serum during menstruation, which could cause severe vascular and bronchoalveolar constriction producing alveolar injury followed by an outlet of air to the pleural space; (3) the existence of endometrial ectopic tissue in the visceral pleura and its desquamation during menstruation; (4) spontaneous rupture of bullae or blebs during hormonal changes; and (5) composite pathogenesis. Many past surgical reviews of diaphragmatic fenestrations supported theory (1). However it was reported that CPT occurred in patients post-hysterectomy.[10] The theory (3) is best fits the pathologic evidence and it is easy to explain the relationship between extrapelvic ectopic endometoriosis containing lung, brain or skin and lymphatic and vascular metastasis theory. However, it is not necessary that ectopic endometrial tissues originate from pri-

Fig. 2. A purple colored nodule was shown on the visceral surface of upper lobe.

mary endometrial tissue. Endometriosis appears in patients without endometrial tissue such as Turner syndrome, uterine hypoplasia, or in male bladder, prostate, and testis. This means ectopic endometriac tissue may be from coelomic metaplasia rather than primary endometrial tissue.

CPT is a systemic disease; pneumothorax or hemothorax should be considered to be only localized manifestations of extrapelvic endometriosis.

As initial treatment, thoracoscope should be undertaken in any case with suspected CPT. If a lesion has caused intrathoracic hemorrhage, and endometriosis or diaphragmatic fenestrations are found in a limited small areas, those areas (diaphragm and lung) may be resected. Indeed, the lesions can be causes of hemoptysis and resection is essential. We think that the most important treatment is mechanical or chemical pleurodesis to prevent recurrent pneumothorax. In our institute, minocycline hydrochloride is selected as a chemical pleurodesis agent. Talc is a carcinogenic agent and should not be used for young patients. OK432 (Picibanil®: Chugai Pharmaceutical Co., Ltd., Tokyo, Japan), a Streptococcal preparation, has an antitumor activity and is known to be a strong pleural adhesive agent, is generally used for patients with carcinomatous pleuritis to control pleural effusion in Japan, but medical insurance does not cover its use in benign disease such as spontaneous pneumothorax. Hormone therapy must be a secondary option because of side effects and a disruption of quality of life.

References

1. Maurer ER, Schaal JA, Mendez FL Jr. Chronic recurring spontaneous pneumothorax due to endometriosis of the diaphragm. *J Am Med Assoc* 1958; **13**: 2013–4.
2. Lillington GA, Mitchell SP, Wood GA. Catamenial pneumothorax. *JAMA* 1972; **219**: 1328–32.
3. Carter EJ, Ettensohn DB. Catamenial pneumothorax. *Chest* 1990; **98**: 713–6.
4. Joseph J, Sahn SA.Thoracic endometriosis syndrome: new observations from an analysis of 110 cases. *Am J Med* 1996; **100**: 164–70.
5. Foster DC, Stern JL, Buscema J, Rock JA, Woodruff JD. Pleural and parenchymal pulmonary endometriosis. *Obstet Gynecol* 1981; **58**: 552–6.
6. Korom S, Canyurt H, Missbach A, et al. Catamenial pneumothorax revisited: clinical approach and systematic review of the literature. *J Thorac Cardiovasc Surg* 2004; **128**: 502–8.
7. Tsunezuka Y, Sato H, Kodama T, Shimizu H, Kurumaya H. Expression of CA125 in thoracic endometriosis in a patient with catamenial pneumothorax. *Respiration* 1999; **66**: 470–2.
8. Bhatia DS, McFadden PM, Kline RC. Recurrent catamenial hemopneumothorax. *South Med J* 1998; **91**: 398–401.
9. Hibbard LT, Schumann WR, Goldstein GE. Thoracic endometriosis: a review and report of two cases. *Am J Obstet Gynecol* 1981; **140**: 227–32.
10. Soderberg CH, Dahlquist EH. Catamenial pneumothorax. *Surgery* 1976; **79**: 236–9.