Case Report

A Case Report of Emergency Off-Pump CABG in an Aged Patient with ACS Renewing Ventricular Fibrillation

Hiroshi Masuhara, MD, Yoshinori Watanabe, MD, Noritsugu Shiono, MD, Muneyasu Kawasaki, MD, Hiroki Yokomuro, MD, Takeshiro Fujii, MD, and Nobuya Koyama, MD

An emergency off-pump coronary artery bypass (OPCAB) was performed successfully in an aged patient with acute coronary syndrome (ACS).
The patient, an 80-year-old woman residing in a nursing home, suddenly lost consciousness during lunch. The electrocardiogram (ECG) showed ventricular fibrillation (Vf) but defibrillation successfully recovered the sinus rhythm. The patient was brought to our hospital as an emergency. She underwent emergency cardiac catheterization. Coronary angiography demonstrated severe three vessel disease with left main coronary trunk (LMT) stenosis. Even during intra-aortic balloon pumping (IABP), the hemodynamic state was unstable, with repeated development of ventricular tachycardia and fibrillation. An emergency coronary artery bypass without a cardiopulmonary bypass was performed. Saving her life was of primary importance and revascularization of the left anterior descending artery (LAD) branch, was performed. Thanks to the advances made in various devices, safe and reliable anastomoses have become possible in OPCAB applied to ACS. OPCAB for ACS have become safe and reliable anastomoses following development of various devices. We think that OPCAB is an effective surgical technique for coronary revascularization for emergency or serious cases involving elderly patients. (Ann Thorac Cardiovasc Surg 2006; 12: 219–22)

Key words: aged patient, emergency off-pump coronary artery bypass, acute coronary syndrome, aorta no touch technique

Introduction

An elderly patient with a diagnosis of ventricular fibrillation was found to suffer from acute coronary syndrome (ACS). Following cardiopulmonary resuscitation (CPR), she was subjected to an emergency off-pump coronary artery bypass (OPCAB), which produced a satisfactory result.

From Department of Surgery, Division of Cardiovascular Surgery, School of Medicine, Faculty of Medicine, Toho University Tokyo, Japan

Received September 20, 2005; accepted for publication December 5, 2005.
Address reprint requests to Hiroshi Masuhara, MD: Department of Surgery, Division of Cardiovascular Surgery, School of Medicine, Faculty of Medicine, Toho University, 6-11-1 Omori-nishi, Ota-ku, Tokyo 143-8541, Japan.

Case

The patient, an 80-year-old woman residing in a nursing home, suddenly lost consciousness during lunch. An ambulance was called, while CPR was administered. By the time the ambulance arrived, she had regained consciousness, then lapsed into a coma for the second time. The electrocardiogram (ECG) monitor indicated ventricular fibrillation (Vf) but defibrillation successfully recovered the sinus rhythm. The patient was brought to our hospital as an emergency. At the time of arrival, her physical conditions were: a loss of consciousness; blood pressure, 160/60 mmHg; pulse, 150/min and irregular; cyanotic lips; and moist râles detected over the entire lung field. The chest radiography showed a cardiothoracic ratio (CTR) of 66.3% and congestion affecting the entire

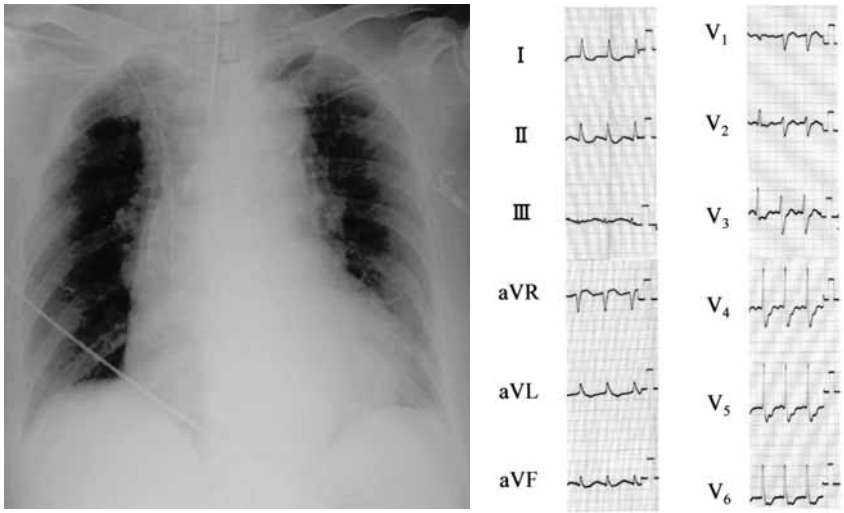

A | B

Fig. 1.
A: The chest radiogram showed CTR of 66.3% and there were signs of exaggerated pulmonary congestion.
B: ECG showed sinus tachycardia, wide QRS, and a depression ST from V3 to V6.

pulmonary field. Sinus tachycardia, wide QRS, and a depression ST from V3 to V6 were noted on an ECG (Fig. 1). The trachea was immediately intubated and, under artificial respiration, she was subjected to emergency cardiac catheterization.

Coronary angiography revealed total occlusion of the right coronary artery (RCA) and the entry to the left circumflex artery branch, 75% stenosis of the left main coronary trunk (LMT) and 50% stenosis of the left anterior descending artery (LAD) branch. The RCA was visualized through collateral circulation from LAD (Fig. 2).

Following intra-aortic balloon pumping (IABP), the patient was transferred to the intensive care unit (ICU). Even during IABP, her hemodynamics were unstable, with repeated development of ventricular tachycardia and fibrillation. An emergency coronary artery bypass was performed.

Because the patient was elderly, with extremely unstable hemodynamics, and the coronary angiographic findings pointing to the LAD region as the culprit lesion, early reconstruction of her coronary flow was considered to be crucial. Surgical revascularization of this region was scheduled. Under general anesthesia, with the patient supine, via a median sternotomy, it was found that revascularization of the LAD and the first diagonal branch (D1) was possible. Because the available left intrathoracic artery (LITA) was not long enough, an I shaped composite graft with a saphenous vein graft (SVG) was selected instead. Because the patient's hemodynamics were unstable and the use of a partial clamp on the ascending aorta was judged to be dangerous, an off-pump sequential coronary bypass was performed, applying the "aorta no touch technique" and using an off-pump CABG device (Axius™, Guidant Co., Santa Clara, CA). For anastomosis of the LAD and D1, Coronary artery shunt tube (Clearview™, Medtronic, Inc., Minneapolis, MN) 2.0 mm and 1.5 mm, respectively were used. The surgical procedure took 4 hours and 35 min. Following surgery, both ventricular tachycardia and fibrillation were no longer seen. On the first postoperative day, IABP was discontinued and on the fourth day the patient was breathing independently. On the fifth post operative day, she was extubated. Having undergone a rehabilitation program, she was judged to have recovered and was discharged on the 59th post operative day. The chest radiography taken at discharge showed a CTR of 53.3% and there were no signs of pulmonary congestion. A reduction in the ST persisted from V3 to V6 in an ECG but ventricular arrhythmia was no longer recognized (Fig. 3).

Discussion

Due to the development of cardioplegic procedures and related technological advances, conventional coronary artery bypass surgery using a cardiopulmonary bypass are being applied to a wide spectrum of disease conditions. However, it became apparent later that a cardiopulmonary bypass leads to a systemic inflammatory response syndrome (SIRS).[1] The cardiopulmonary bypass procedure certainly is a maximal form of insult to the patient. Cerebral infarction, which may develop as a consequence of cannulation or aortic cross clamping, a serious complication of the procedure.[2]

Recently, the percentage of off-pump coronary artery

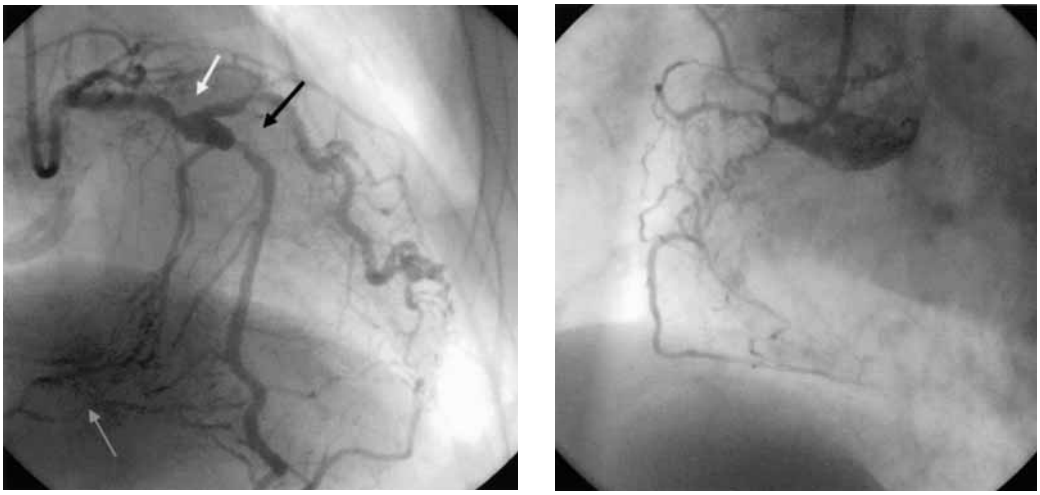

A | B

Fig. 2.
A: Coronary angiography revealed 75% stenosis of the LMT (white arrow) and 50% stenosis of the LAD (black arrow). The RCA was visualized through collateral circulation from the LAD (gray arrow).
B: Coronary angiography revealed total occlusion of the RCA and the LCx.

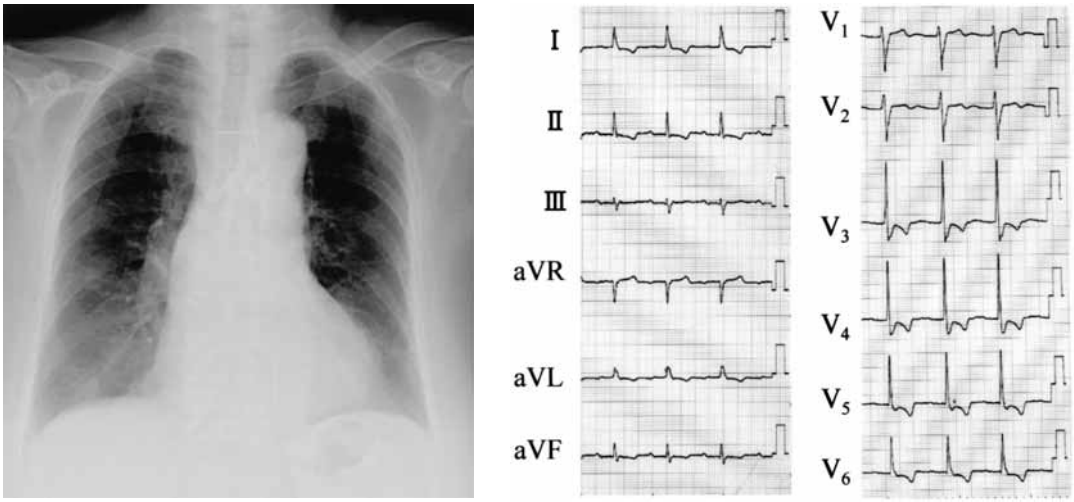

A | B

Fig. 3.
A: The chest radiogram taken at discharge showed CTR of 53.3% and there were no signs of pulmonary congestion.
B: ECG showed a depression in the ST persisted from V3 to V6, but ventricular arrhythmia was no longer recognized.

bypasses, relative to the total coronary artery bypasses, has increased. There are a number of reports attesting to the fact that the outcome of the former is comparable to conventional procedures.[3,4] In particular, in those cases in which cardiopulmonary bypass constitutes a high risk, the efficacy of the off-pump bypass has been recognized by many and sporadic cases of ACS are included in these reports.[5]

One of the advantages of OPCAB applied to ACS, the elimination of the operation to establish extracorporeal circulation, thus shortening the time prior to the start of coronary perfusion, has been cited.[6] Another is that in cases of shock, SIRS is recognized before the operation, and by using a cardiopulmonary bypass the extension of the SIRS lesion can be averted.

With recent improvements in the stabilizer, a bypass became possible while hemodynamic stability is maintained.[7] By using a coronary shunt tube, peripheral is-

chemia may be avoided during anastomoses, the preconditioning procedure may be obviated, and the desired bloodless operative field can be produced.[8] With the improvement in OPCAB devices, such as those described above, safe and reliable anastomotic procedures have become possible. Some have reported that the graft used in OPCAB is radiologically visualized during surgery to prove that the anastomotic procedure is successful.[9]

The lesions in the current case involved three vessels. The patient was 80 years old and in a state of shock due to cardio-respiratory arrest before the operation. In such a case, there is a high risk associated with cardiopulmonary bypass. Saving her life was of primary importance and revascularization of the LAD, the culprit lesion, was performed. It was believed that the procedure was also effective in salvaging the area supplied by the RCA, which was visualized by collateral circulation from the LAD.

In the present case, the CTR was exaggerated and it was not possible to revascularize the LAD and D1 with the LITA alone. Therefore a type I composite graft using the LITA and SVG was prepared. Because of her unstable hemodynamics, the use of a partial clamp on the ascending aorta was considered too dangerous: instead, a sequential bypass with the "aorta no touch technique" was performed on the LAD and D1.

Following the bypass surgery, ventricular tachycardia and fibrillation were no longer evident, which was taken as proof of effective revascularization.

The lesion in the LAD is the likely cause of ACS that precipitated the preoperative shock.[10] Although it was not an example of complete revascularization in this case, emergency OPCAB was performed to save the patient's life. The result was successful.

References

1. Puskas JD,Wright CE, Ronson RS, Brown WM 3rd, Gott JP, Guyton RA. Off-pump multivessel coronary bypass via sternotomy is safe and effective. *Ann Thorac Surg* 1988; **66**: 1068–72.
2. McKhann GM, Goldsborough MA, Borowicz LM Jr, et al. Predictors of stroke risk in coronary artery bypass patients. *Ann Thorac Surg* 1997; **63**: 516–21.
3. Turner WF Jr. "Off-pump" coronary artery bypass grafting: the first one hundred cases of the Rose City experience. *Ann Thorac Surg* 1999; **68**: 1482–5.
4. Bedi HS, Suri A, Kalkat MS, et al. Global myocardial revascularization without cardiopulmonary bypass using innovative techniques for myocardial stabilization and perfusion. *Ann Thorac Surg* 2000; **69**: 156–64.
5. Ohashi H, Tsutsumi Y, Kawai T, Ueda T, Ikeda M, Ohnaka M. Emergency coronary artery bypass grafting for acute coronary syndrome. *Kyobu Geka* 1999; **52** (8 Suppl) : 644–7. (in Jpse.)
6. Moshkovitz Y, Paz Y, Shabtai E, et al. Predictors of early and overall outcome in coronary artery bypass without cardiopulmonary bypass. *Eur J Cardiothorac Surg* 1997; **12**: 31–9.
7. Hart JC, Spooner TH, Pym J, et al. A review of 1,582 consecutive Octopus off-pump coronary artery bypass patients. *Ann Thorac Surg* 2000; **70**: 1017–20.
8. Sunami H, Irie H, Oshima Y, et al. Off-pump coronary artery bypass grafting using coronary shunt tubes. *Jpn J Cardiovasc Surg* 2002; **31**: 37–9.
9. Watanabe Y, Koyama N, Shiono N, et al. The usefulness of intra-operative angiography during off-pump CABG. *Kyobu Geka* 2001; **54**: 332–6. (in Jpse.)
10. Nakano H, Daimon M, Hayashi K, Okamura H. Evaluation of value of coronary artery bypass grafting without cardiopulmonary bypass for emergency or subemergency case. *Kyobu Geka* 2001; **54**: 298–304. (in Jpse.)