Original Article

The Use of a Water Seal to Manage Air Leaks after a Pulmonary Lobectomy: A Retrospective Study

Junichi Okamoto, MD, Tatsuro Okamoto, MD, Yasuro Fukuyama, MD, Chie Ushijima, MD, Masafumi Yamaguchi, MD, and Yukito Ichinose, MD

Background: The methods for managing chest drainage tubes during the postoperative period differ among thoracic surgeons and, as a result, the optimal method remains controversial.
Patients and Methods: We reviewed 170 consecutive patients undergoing a pulmonary lobectomy for either primary lung cancer or metastatic lung cancer from January 1998 to December 2002. After the operation, the chest drainage tube was placed on a suction pump with a negative pressure of –10 cmH_2O in 120 patients before 2001, while such drainage tubes were kept on water seal in 47 cases mainly since 2001.
Results: Regarding the preoperative and postoperative variables, postoperative air leak as well as the video-assisted thoracic surgery (VATS) procedure were more frequently observed in the water seal group than in the suction group ($p=0.01580$, $p<0.001$, respectively). In comparing these different populations, each Kaplan-Meier curve, which presented the duration of the postoperative air leak seemed to be similar between the two methods.
Conclusion: These observations suggest that applying chest tubes on water seal seems to be an effective method for preventing postoperative air leak in clinical practice. However, a prospective randomized trial using a larger series of patients is warranted for this subject. (Ann Thorac Cardiovasc Surg 2006; 12: 242–4)

Key words: chest tube, drainage, air leak, lobectomy

Introduction

Prolonged air leakage after a lung resection is still one of the most frequent complications in chest surgery. Such air leaks may increase the duration of the chest drainage, thus resulting in a longer hospitalization. Recently, some prospective trials have shown that applying water seal to chest tubes after a lung resection reduced the duration of air leakage in comparison to suction.[1,2] As a result, we have used the water seal as an alternative procedure to the use of suction –10 cmH_2O. However, a more recent study has also described a negative finding.[3] Therefore, the optimal method for managing postoperative chest tubes remains controversial. We retrospectively investigated whether or not the water seal resulted in a better outcome than suction in clinical practice at our institution.

From Department of Thoracic Oncology, National Kyushu Cancer Center, Fukuoka, Japan

Received November 14, 2005; accepted for publication January 19, 2006.
Address reprint requests to Tatsuro Okamoto, MD: Department of Thoracic Oncology, National Kyushu Cancer Center, 3–1–1 Notame, Minami-ku, Fukuoka 811–1395, Japan.

Patients and Methods

We reviewed 170 consecutive patients who underwent pulmonary lobectomy for either primary lung cancer or metastatic lung cancer at National Kyushu Cancer Center, from January 1998 to December 2002.

All pulmonary lobectomies were performed through either a standard posterolateral incision or video-assisted thoracic surgery (VATS) procedures. The VATS procedure performed in our institution has been described previously.[4] The operative techniques were standardized for all surgeons. A mediastinal lymphadenectomy (ND2a) was performed after completion of a lobectomy. Before

Table 1. Comparison between the two groups regarding the preoperative and operative variables

Group		Suction (n=120)	Water seal (n=47)	p value
Gender	Male	70 (58.3%)	27 (57.4%)	>0.999
	Female	50 (41.7%)	20 (42.6%)	
Age		64.6±10.3	63.8±10.8	0.7244
Smoking history	Presence	61 (50.8%)	27 (57.4%)	0.4928
	Absence	59 (49.2%)	20 (42.6%)	
Thoracotomy procedure	Antero-lateral	68 (56.7%)	2 (4.3%)	<0.001
	VATS	52 (43.3%)	45 (95.7%)	
Pulmonary adhesion		38 (31.7%)	14 (29.8%)	0.7152
Incomplete fissures		64 (53.3%)	24 (51.1%)	0.8637
Pathological stage	I	94 (78.3%)	40 (85.1%)	0.6240
	II	9 (7.5%)	4 (8.5%)	
	III	15 (12.5%)	3 (6.4%)	
	IV	1 (0.8%)	0 (0.0%)	
Postoperative air leak		30 (25.0%)	20 (42.6%)	0.0158

VATS, video-assisted thoracic surgery.

closing the thoracic cavity, an air leak test was performed using warmed normal saline. If an air leak was detected, it was repaired by either a suture, a synthetic sealant, or both. One 28F chest double-lumen tube was positioned posteriorly into the thorax, and the tubes were placed on suction (−10 cmH_2O) after the closure. After returning to the ward, on the same day of the operation, the tube was placed either on −10 cmH_2O suction again or on water seal. The chest tubes in all patients undergoing an operation before 2001 were used for suction. After 2001, either suction or water seal was used at the discretion of a surgeon. In fact, 120 and 47 patients underwent suction or water seal placement, respectively. Chest radiographs were routinely performed almost everyday until the chest tube was removed. When the pleural effusion was less than 200 ml in a 24-hour period and no air leak was evident, then the chest tubes were removed. Before removing the chest tube, the absence of any air leak in the water seal group was checked by −10 cmH_2O suction.

The following preoperative and operative variables were considered and compared between the suction group and the water seal group: the patient's age, gender, smoking history, type of thoracotomy procedure, degree of pleural adhesion, the status of pulmonary fissures, pathological stage, and postoperative air leak. The two-sample χ^2-test and Fisher's exact test, when appropriate, were used to compare categorical variables. The Kaplan-Meier method was used to estimate the duration of air leakage and the duration that a drainage tube remained in place. Comparisons were made using the log-rank test; a value of $p<0.05$ was considered significant.

Results

The details of the preoperative and operative variables of the patients are shown in Table 1. The VATS procedure and postoperative air leak were more frequently observed in the water seal group than in the suction group ($p<0.001$, $p=0.01580$). Thirty (25.0%) of 120 patients in the suction group and 20 (42.6%) of 47 patients in the water seal group demonstrated air leaks immediately after the operation. There was no difference in gender, age, smoking history, pulmonary adhesion, the presence of incomplete fissures, pathological stage and histological type between the two groups. Using the Kaplan-Meier method, the curves of air leak duration in both the suction group and the water seal group are shown in Fig. 1. The two curves diverged just after the operation, which represented a difference in the postoperative air leakage at the starting point between the two groups. However, the two curves had become closely similar by the next day. The mean ± standard error (SEM) of air leakage duration was 39.2±5.5 hours in the patients with postoperative air leak of the suction group and 31.6±7.3 hours in those in the water seal group (log-rank test, $p=0.29$). The mean±SEM of duration of chest drainage was 4.6±0.33 days for the suction group and 3.6±0.19 days for the water seal group (log-rank test, $p=0.01$).

Discussion

Recently, two prospective studies have shown that placing a chest tube on water seal after a lung resection can

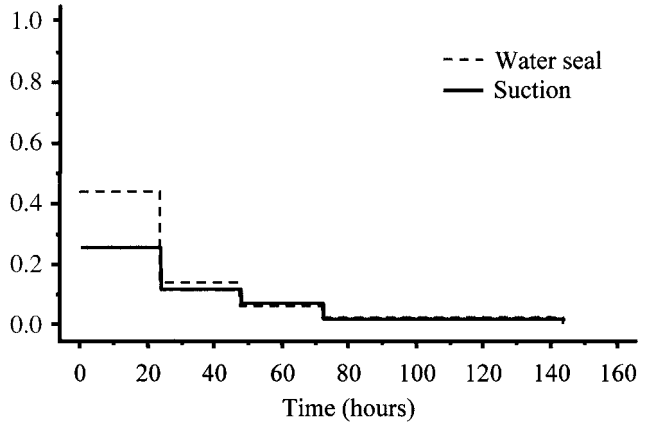

Fig. 1. Duration of postoperative air leakage in the suction group and the water seal group.

reduce the duration of air leakage in comparison to the use of suction. Cerfolio and his colleagues cited that 66% of all air leaks resolved on the 3rd postoperative day (POD3) when the water seal tubes were placed on POD2, whereas only 7% of the patients whose tubes were continuously placed on –20 cm suction showed a resolution of the air leak by POD3.[1] Another group also demonstrated the duration of air leakage to be shorter in the water seal group than in the suction group (mean±SEM, 1.50±0.32 days vs 3.27±0.80 days, respectively; p=0.05).[2] However, in both studies, the number of patients with a postoperative air leak was so small (33 and 30 patients, respectively) that they did not seem to have enough statistical power to show any true differences. Moreover, there were some variations in the types of operations performed in these trials. Brunelli and colleagues showed in their randomized clinical trial that chest tubes placed on water seal after a pulmonary lobectomy did not show a reduced duration of air leakage in comparison with suction (–20 cmH_2O).[3] As a result, the optimal way to use chest tubes remains controversial among surgeons.

Before 2001, the use of –10 cmH_2O suction had been adopted as the standard method for chest drainage after a pulmonary lobectomy at our institution. After 2001, based on the findings of Cerfolio and his colleagues, either suction or water seal was selected at the discretion of the surgeon in charge.[1] In addition, we also began using the VATS procedure as a surgical approach since 1999 in place of the standard posterolateral thoracotomy. This is the reason why a significantly large number of patients (95.7%) in the water seal group underwent a VATS lobectomy in comparison to only 43.3% in the suction group. Table 1 also shows the water seal group to demonstrate more patients with air leak than the suction group patients in the immediate postoperative period (p=0.0158). The main reason for this is due to the fact that the water seal method tended to be selected by surgeons for patients with postoperative air leaks. In the present study, the duration of air leakage was similar in both groups. Our observations indicated that the water seal method therefore appears to be a safe and effective method for treating postoperative air leaks.

Regarding the duration of chest drainage, the mean duration of chest drainage in the water seal group tended to be shorter than in the suction group in the present study. The reason of this difference is not clear because of difference in the two groups. At our institution, the decision to remove the chest tube is based on the 24-hour amount of drained fluid with no air leak. In the present study, the amount of pleural effusion in the water seal group was significantly smaller than in the suction group (average, 800 ml vs 1,132 ml; p<0.001), and this difference might influence the duration of the chest drainage.

In conclusion, our data suggests that applying chest drainage tubes on water seal seems to be an effective method for treating postoperative air leakage. Whether or not this modality provides any advantages regarding reduction in the duration of such air leakage could be evaluated by a prospective randomized trial with a large series of patients.

Acknowledgement

We thank Dr. Brian Quinn for critical comments on the manuscript, and Ms. Yumiko Oshima for her help in preparing the manuscript.

References

1. Cerfolio RJ, Bass C, Katholi CR. Prospective randomized trial compares suction versus water seal for air leaks. *Ann Thorac Surg* 2001; **71**: 1613–7.
2. Marshall MB, Deeb ME, Bleier JI, et al. Suction vs water seal after pulmonary resection: a randomized prospective study. *Chest* 2002; **121**: 831–5.
3. Brunelli A, Monteverde M, Borri A, et al. Comparison of water seal and suction after pulmonary lobectomy: a prospective, randomized trial. *Ann Thorac Surg* 2004; **77**: 1932–7.
4. Yoshino I, Ushijima C, Tomiyasu M, Suemitsu R, Ichinose Y, Sugimachi K. Unique minithoracotomy assisted by videothoracoscopy facilitates a maximal view even with a minimal wound for resection of primary lung cancer. *Surg Endosc* 2002; **16**: 148–50.