

## Delayed Hemopericardium with Constrictive Pericarditis after Blunt Trauma: A Report of a Surgical Case

Hung-Shih Lin, MD,<sup>1</sup> Hung-Chang Liu, MD,<sup>1</sup> Wen-Chieh Huang, MD,<sup>1</sup> Chao-Hung Chen, MD,<sup>1</sup> Chang-Jer Huang, MD,<sup>1</sup> Chi-Yuan Tzen, MD,<sup>3</sup> and Wei-Hung Chen, MD<sup>2</sup>

**Constrictive pericarditis (CP) following hemopericardium has been reported in the literature but its pathogenesis is open to question. Proposed mechanisms include trauma leading to damage of the mesothelial lining resulting in decreased fibrinolytic activity in the presence of blood. We present a patient who sustained blunt thoracoabdominal trauma in a car accident and subsequently developed delayed hemopericardium leading to constrictive pericarditis and impending cardiac tamponade. We performed a pericardiectomy to relieve the compression. Closely prolonged monitoring and emergent operation are suggested for such kinds of delayed complications. (Ann Thorac Cardiovasc Surg 2006; 12: 428–31)**

**Key words:** delayed hemopericardium, constrictive pericarditis, trauma

### Introduction

Constrictive pericarditis (CP) may be caused by a variety of insults, including tuberculosis, uremia, dialysis, viral or bacteria infection, delayed hemopericardium, inflammatory reaction to foreign body, or autoimmune disease. However, the exact pathophysiology is not well understood.<sup>1–9</sup> The reported incidence of tuberculous pericarditis ranges from 10 to 28% of cases,<sup>1</sup> but this has declined with improved antituberculosis agents.<sup>6</sup> Bright first described uremic pericarditis in 1836.<sup>10</sup> More recently, dialysis-induced CP is recognized as a frequent complication in acute and chronic renal failure (RF).<sup>7</sup> Few cases of CP after trauma have been reported in the English literature.<sup>1,5,6</sup> We present a case of CP with pericardial tamponade, associated with acute RF after severe blunt trauma. The etiology and treatment of CP are reviewed and discussed.

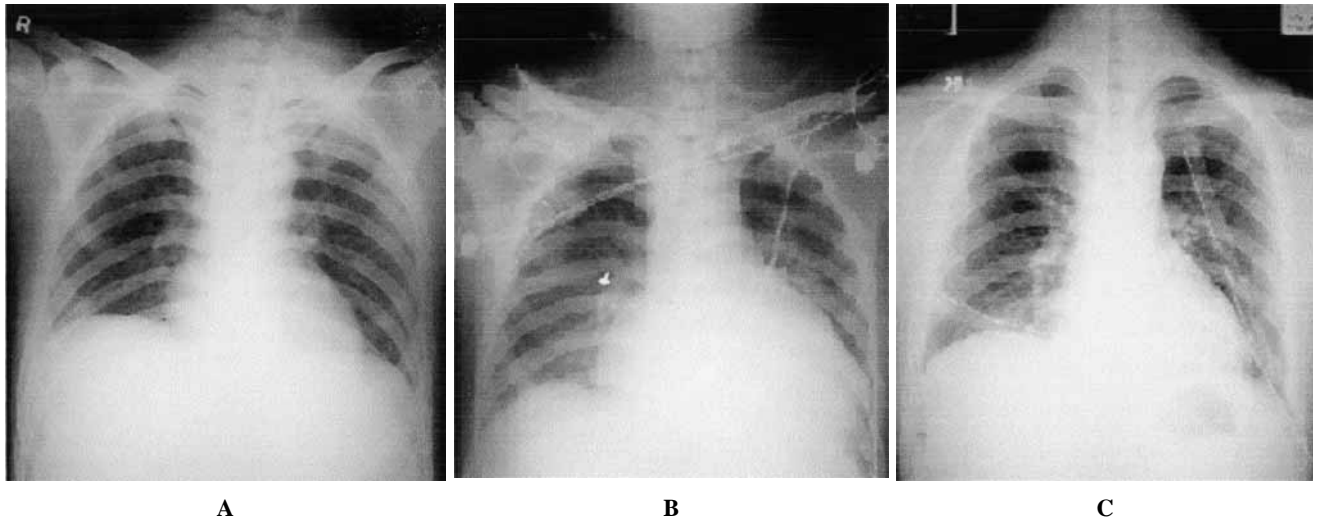
*From Divisions of <sup>1</sup>Thoracic Surgery, <sup>2</sup>General Surgery, and <sup>3</sup>Pathology, Mackey Memorial Hospital, Mackey Medicine, Nursing, and Management College, Taipei, Taiwan*

Received November 17, 2005; accepted for publication April 21, 2006.

Address reprint requests to Hung-Chang Liu, MD: Division of Thoracic Surgery, Mackey Memorial Hospital, #92, Sec 2, Chung-Shan N. Rd, Taipei 104, Taiwan.

### Case Report

A 21-year-old man had an accident when driving while intoxicated. He sustained seat belt injuries to the chest and abdomen. In the emergency room, he was confused and speaking incoherently. His vital signs were normal. He had a bleeding nasal laceration, an abdominal abrasion, and petechia from the left upper to the right lower chest. His abdomen was soft and flat, but there was severe tenderness in the lower abdomen. X-rays of the cervical spine, chest, and pelvis and brain computed tomography (CT) were all normal. Abdominal CT revealed a fluid accumulation in the peritoneal cavity. The patient was admitted to surgical intensive care unit for observation, with the initial diagnosis of blunt abdominal trauma with suspected internal bleeding. After admission, his vital signs were unstable with tachycardia, hypotension, and tachypnea despite fluid resuscitation and oxygen supply. His blood pressure fluctuated and had once dropped to 84/58 mmHg. The abdomen then became distended and severe tenderness over the lower abdomen persisted. Serial laboratory data showed gradually elevated leukocytosis and band shift. Under the impression of peritonitis and internal bleeding, an emergency exploratory laparotomy was done and revealed two perforations in the small intestine, 80 and 90 cm from the ileocecal valve and one



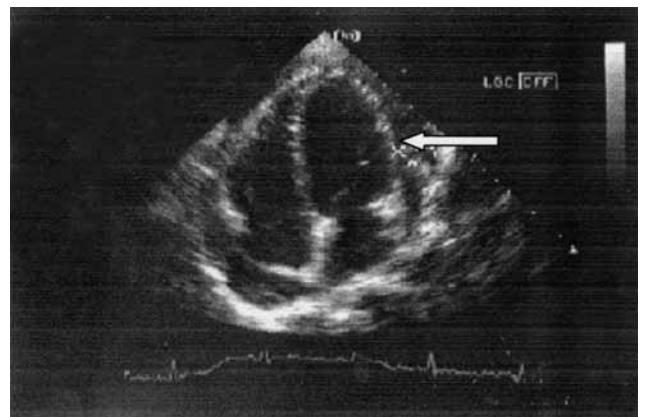
**Fig. 1.** A series of chest X-rays clearly demonstrate the disease progression and recovery after operation.

- A:** The first chest roentgenography at the emergency room did not reveal abnormality.  
**B:** Increased cardiac border with cardiomegaly and cardiac tamponade.  
**C:** Cardiac silhouette of chest film decreased in size postoperatively.

bleeding mesenteric vessel 100 cm from the ileocecal valve. After the operation, the patient remained on the ventilator and was thought to have sepsis. However, he later developed acute RF, with oliguria, azotemia and hyperkalemia: blood urea nitrogen was elevated to 125 mg/dl; urine output was less than 30 cc/hour; blood potassium was above 6.5 mEq/l. The condition could not be corrected by medication with diuretics and he required hemodialysis.

Over the following days, he gradually improved, although his condition fluctuated. His renal failure improved after hemodialysis. However, serial chest X-rays showed progressive cardiomegaly (Figs. 1A and 1B). On his 13th day in hospital, he again developed symptomatic sinus tachycardia. A transthoracic echocardiogram revealed a large pericardial effusion and a fibrin-like substance in the pericardial cavity (Fig. 2).

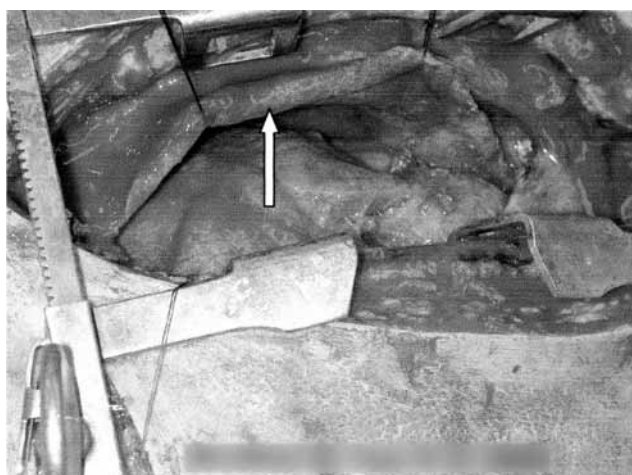His chest was opened in view of the risk of intrapericardial injury with impending pericardial tamponade. An anterior sternotomy was performed to facilitate a pericardiectomy, but no apparent cardiac injury or laceration was found in the opened pericardium. More than 600 ml of bloody effusion mixed with fibrin, tissue debris, and inflammatory peel were found in the pericardial cavity, and the pericardium was markedly thickened (Fig. 3), consistent with a diagnosis of CP. An extensive anterior pericardiectomy was done for decompression. The anterior part of pericardium, 10 cm in width and 14



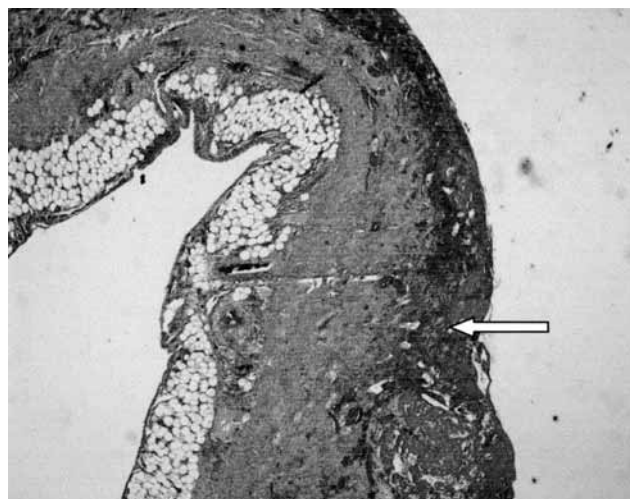
**Fig. 2.** Transthoracic echocardiogram revealed a large amount of pericardial effusion (arrow).

cm in length (including below the aortic reflexion, above the fusion of pericardium and diaphragm, and the interior of bilateral phrenic nerve), was removed. Pathologic examination of the pericardium revealed hemorrhagic fibrous tissue covered by a mixture of fibrin and red blood cells with an area of early organization (Fig. 4).

The patient remained hemodynamically stable throughout the operation. Postoperatively, his chest X-ray was normal (Fig. 1C). Symptomatic tachycardia and hypotension were no longer present after operation. His endotracheal tube was removed on his 14th day of ad-



**Fig. 3.** There were fibrin, tissue debris, and inflammatory peel in the pericardial cavity. Markedly thickened pericardium (arrow) was also noted.



**Fig. 4.** The pericardium contained hemorrhage and fibrin deposition (arrow).

mission and he was transferred to an ordinary ward the next day. He was discharged uneventfully 3 weeks following admission.

## Discussion

The current report describes a case of CP with pericardial tamponade occurring late after a complex blunt injury which was complicated by delayed hemopericardium, systemic inflammatory response syndrome, and RF. Thoracotomy with pericardiectomy proved life-saving for this patient. There are a few previously reported cases of delayed hemopericardium with CP after blunt thoracic trauma. Taylor et al. reported delayed hemopericardium in a 10-month-old infant,<sup>2)</sup> and Cil et al. described 2 cases of delayed hemopericardium after minor chest trauma.<sup>3)</sup>

The current patient had a thickened pericardium which was one of the pathologic hallmarks of CP. Schiavone reported echocardiographic findings in 18 patients with CP,<sup>4)</sup> all of whom had pericardial thickening. Several cases of CP after trauma resulting in cardiac tamponade have also been reported,<sup>5,6)</sup> although the pathogenesis is unclear. Sbokos et al.<sup>1)</sup> developed an experimental model showing that traumatic hemopericardium promotes development of CP, whereas simple injection of blood into the pericardial cavity does not cause pericardial changes. It is thought that physical or chemical trauma damages the mesothelial lining of the pericardium, leading to decreased absorption of fibrin or loss of fibrinolytic activ-

ity. The persistence of the blood induces intrapericardial inflammation, granulation tissue, and adhesions, causing constriction and subsequent cardiac tamponade. Inflammation associated with autoimmune disease may respond to corticosteroid administration. Cardiac surgery is a major cause of CP, with a higher incidence after valve replacement than after coronary bypass surgery. This has been attributed to early anticoagulation with hemorrhage into the pericardial cavity.<sup>4)</sup> CP thus appears to develop when there is both damage to the mesothelium and the presence of blood.

Discerning the cause of the delayed hemopericardium and consequent CP is complicated in this patient by the fact that he also developed RF requiring hemodialysis.<sup>7)</sup> Although pericarditis is a frequent complication of RF, it is unpredictable in that there is no close correlation between pericarditis and the levels of blood urea and creatinine.<sup>8,9)</sup> Heparinization may be a more likely culprit than the renal dysfunction itself.<sup>6)</sup> In a series of 27 patients, Beaudry et al. found that pericarditis occurred when the blood urea and serum creatinine levels were lower than they had been on admission in all but one patient studied.<sup>8)</sup> It seems likely that multiple factors contributed to our patient's CP. The blunt trauma probably caused capillary rupture and bleeding within the pericardium with subsequent fibrin organization and an inflammatory response. When the patient developed RF, he required heparinization for dialysis, thereby increasing the risk of capillary hemorrhage and potentiating the inflammatory re-

sponse. How much of the role uremia played is a debatable. Other factors including infection and electrolyte imbalance<sup>7)</sup> were also present, but the exact role of any of these in the pathogenesis of this man's CP cannot be precisely determined.

The development of CP after chest trauma may be delayed. Brown and Ivey<sup>11)</sup> reported that the period between injury and diagnosis of pericardial hematoma producing symptoms of CP ranged from 3 to 20 years. The true incidence of pericarditis due to chest trauma may be higher than reported, as a history of trauma remote from the onset of CP may be overlooked. Obviously, when a patient presents with hemopericardium, it is difficult to make sure that it is a delayed response to earlier chest injury. However, given the possibility of delayed hemopericardium that may eventually result in CP and symptomatically delayed pericardial calcification,<sup>12)</sup> it would be wise to follow patients periodically after an episode of blunt chest trauma.

Once the diagnosis of CP has been made, pericardiectomy should be performed promptly, as the disease will progress. Ideally, the pericardium should be completely removed from all surfaces of the ventricle, either through a sternotomy if possible or through a left anterolateral thoracotomy. However, sometimes in a hemodynamically unstable patient with a severely thickened pericardium, a partial pericardiectomy will suffice. This was the situation with our patient, who responded well to an anterior pericardiectomy. Miller et al. suggested that all cases of CP should be approached through a median sternotomy with cardiopulmonary bypass on standby.<sup>13)</sup>

In conclusion, CP secondary to delayed hemopericardium after blunt trauma is rare but does occur. The pathogenesis of this condition may be complex in patients with multiple problems. Close monitoring of such patients is indicated, with prompt pericardiectomy required if tamponade develops.

## References

1. Sbokos CG, Karayannacos PE, Kontaxis A, et al. Traumatic hemopericardium and chronic constrictive pericarditis. *Ann Thorac Surg* 1977; **23**: 225–9.
2. Taylor MW, Garber JC, Boswell WC, et al. Delayed hemopericardium and associated pericardial mass after blunt chest trauma. *Am Surg* 2003; **69**: 343–5.
3. Cil E, Senkaya I, Tarim O. Delayed hemopericardium due to trivial chest trauma. *Cardiol Young* 1998; **8**: 390–2.
4. Schiavone WA. The changing etiology of constrictive pericarditis in a large referral center. *Am J Cardiol* 1986; **58**: 373–5.
5. Karmy-Jones R, Yen T, Cornejo C. Pericarditis after trauma resulting in delayed cardiac tamponade. *Ann Thorac Surg* 2002; **74**: 239–41.
6. Schweitzer J, Nirula R, Romero J, et al. Successful emergent thoracotomy for pericardial tamponade caused by late constrictive pericarditis after trauma. *J Trauma* 2001; **50**: 945–8.
7. Comty CM, Cohen SL, Shapiro FL. Pericarditis in chronic uremia and its sequels. *Ann Intern Med* 1971; **75**: 173–83.
8. Beaudry C, Nakamoto S, Kolff WJ. Uremic pericarditis and cardiac tamponade in chronic renal failure. *Ann Intern Med* 1966; **64**: 990–5.
9. Ghavamian M, Gutch CF, Hughes RK, et al. Pericardial tamponade in chronic-hemodialysis patients treated by pericardiectomy. *Arch Intern Med* 1973; **131**: 249–53.
10. Bright R. Tabular view of the morbid appearances in 100 cases connected with albuminous urine: with observations. *Guy Hosp Rep* 1836; **1**: 380–400.
11. Brown DL, Ivey TD. Giant organized pericardial hematoma producing constrictive pericarditis: a case report and review of the literature. *J Trauma* 1996; **41**: 558–60.
12. Isaacs D, Stark P, Nichols C, et al. Post-traumatic pericardial calcification. *J Thorac Imaging* 2003; **18**: 250–3.
13. Miller JI, Mansour KA, Hatcher CR Jr. Pericardiectomy: Current indications, concepts, and results in a university center. *Ann Thorac Surg* 1982; **34**: 40–5.