Case Report

Large Saphenous Vein Graft Aneurysm with a Fistula to the Right Atrium

Tsutomu Sugimoto, MD, Kazuo Yamamoto, MD, Shinpei Yoshii, MD, Koji Shimada, MD, Masatake Katsu, MD, Yasunori Iida, MD, and Shigetaka Kasuya, MD

We report on a case of a 65-year-old man who was admitted for anterior chest pain on effort. He had received coronary artery bypass grafting (CABG) surgery 20 years ago with saphenous vein grafts (SVGs) to the left anterior descending artery (LAD) and right coronary artery (RCA). An angiography demonstrated large aneurysmal dilatation of both grafts and a fistulous communication between the middle portion of the right SVG and the right atrium (RA). The aneurysm was excised surgically, and the fistula was closed with the right atrial wall with additional bypass grafts of the left internal thoracic artery (LITA) and gastroepiploic artery (GEA). (Ann Thorac Cardiovasc Surg 2006; 12: 435–7)

Key words: aneurysm, fistula, coronary artery bypass grafting surgery, vein graft

Introduction

A saphenous vein graft (SVG) aneurysm after an aorto-coronary bypass is a rare but potentially fatal complication. Among them, a very unusual complication is the development of a fistula between the SVG aneurysm and a cardiac chamber. We report on a case of SVG aneurysm and fistula to the right atrium (RA) 20 years after coronary artery bypass grafting (CABG).

Case Report

In September 2004, a 65-year-old man was admitted to our hospital for anterior chest pain on effort. Twenty years ago, the patient had undergone coronary bypass surgery with SVG to the left anterior descending artery (LAD) and to the right coronary artery (RCA).

On admission, a grade II/VI systolic murmur was audible at the left lower sternal border. Electrocardiogram was consistent with ST depression in II, III, AVF, and V4–V6. Chest roentgenogram demonstrated an abnormal right-sided cardiac contour. Computed tomographic (CT) scanning showed a laminated anterior mediastinal mass measuring 3.0×3.5 cm in diameter on the right side of the RA and another mass measuring 1.5×1.7 cm in diameter on the anterior interventricular sulcus (Fig. 1). Angiography of both bypass grafts to the RCA and LAD showed a large aneurysmal dilatation of each SVG, and the RCA graft showed fistulous communication to the RA (Fig. 2). The bypass graft to the LAD showed 75% stenosis in the distal anastomosed site. Blood sampling study showed a significant increase in O_2 saturation at the middle RA.

A remedian sternotomy was performed and a tight fibrous adhesion was dissected. The left internal thoracic artery (LITA) and right gastroepiploic artery (GEA) were then harvested in a skeletonized fashion. Cardiopulmonary bypass was established with arterial cannulation into the ascending aorta and bicaval direct cannulation. All surgical procedures were performed with the heart beating, under the cardiopulmonary bypass support. The aneurysmal SVGs were dissected from the aortic anastomosed site to the distal bypass site. To avoid injury to the ventricle and LAD, removal of the aneurysmal SVG for the LAD was not undertaken. The LITA was connected just distal to the previous anastomosis site and the GEA was anastomosed to the RCA distal to the SVG aneurysm. Then the proximal and distal sides of the SVG aneurysm for the RCA were dissected. After ligation of both

From Department of Cardiovascular Surgery, Tachikawa Medical Center, Nagaoka, Japan

Received January 11, 2006; accepted for publication April 3, 2006.
Address reprint requests to Tsutomu Sugimoto, MD: Department of Cardiovascular Surgery, Tachikawa Medical Center, 3–2–11 Kanda-cho, Nagaoka, Niigata 940–8621, Japan.

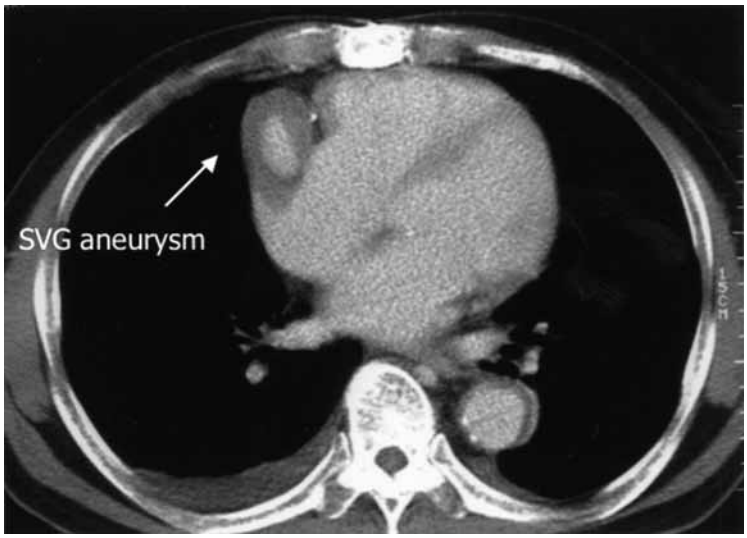

Fig. 1. Computed tomography shows a predominantly thrombosed aneurysm of the saphenous vein graft.
SVG, saphenous vein graft.

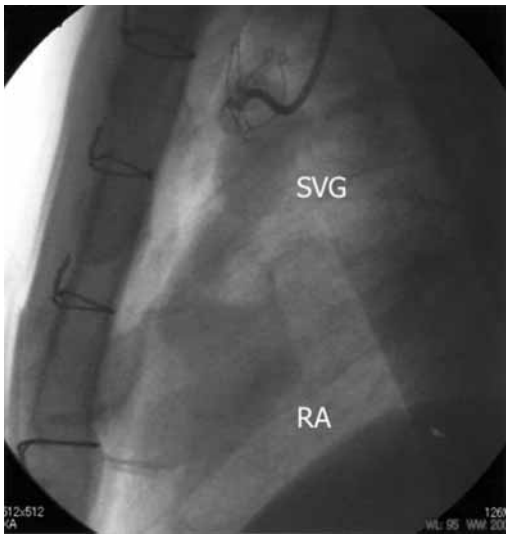

Fig. 2. Selective angiography of the saphenous vein graft to the right coronary artery shows a dilated saphenous vein graft with a fistulous tract into the right atrium.
SVG, saphenous vein graft; RA, right atrium.

the sides of aneurysmal SVG, the aneurysm was opened and a laminated thrombus within the lumen was removed. On exploration, a 2-cm fistula orifice was found in the RA, and was directly closed with 4-0 polypropylene using over and over sutures. Weaning the patient from cardiopulmonary bypass was uneventful.

The patient had an uneventful recovery, and postoperative coronary angiography (CAG) showed patent arterial grafts and no residual shunt to the RA.

Comment

We herewith present a case, where a patient developed a large aneurysm of the SVG to the RCA with a fistulous communication into the RA 20 years after CABG. Aneurysms of vein grafts are late complications of CABG, but infrequent. Reported time of development of this complication is about 10–20 years postoperatively.[1,2] Benchimol and associates[3] have pointed out the potential site of vein graft weakness, viz.; (i) in the vicinity of the venous valve because of a lack of circular muscle; (ii) at the branched site; and (iii) areas which were damaged during the initial surgical procedure. Moreover, fistulous communication between an aneurysm of a SVG and a cardiac chamber is very rare and only 8 cases including this case have been reported in the literature.[2,4–9] Five patients have developed a fistula from the SVG to the RCA to the RA,[2,4–6] one each to the right ventricle[7] and SVG to the LAD to the left atrium,[8] and in another, involving the circumflex to the pulmonary artery.[9]

Many patients with a SVG aneurysm are asymptomatic. In most of the reported cases, a hilar mass was found in the routine chest roentgenogram, which was further investigated by CT scanning and cardiac catheterization. Development of abrupt chest pain seems to occur with acute fistula formation.[5] In this case angina developed resulting from a steal phenomenon. A continuous shunting of blood flow from the vein graft to the RA via the fistulous communication might have resulted in myocardial ischemia of the distal RCA.

Options for SVG aneurysm treatment are not well established. There have been few reported cases managed with percutaneous endovascular procedures.[2,6] However, most cases have undergone surgical ligation of the graft or resection of the aneurysm with replacement by a new conduit if the native coronary artery requires further revascularization.[2,4,5,7–9] Early surgery appears to be the treatment of choice to reduce not only the risk of rupture but also the risk of embolization from muralthrombi in the aneurysmal SVG into the distal coronary and pulmonary arteries.

Although SVG aneurysm with a fistula to a cardiac chamber is a very rare complication of CABG, it carries a risk of rupture and embolization to the distal native coro-

nary artery, and acute congestive heart failure due to shunting of blood flow from the coronary circulation into the cardiac chamber. Physicians should keep in mind the possibility of this complication in patients after CABG who show abnormal contours on chest roentgenogram and an audible heart murmur.

References

1. Kalimi R, Palazzo RS, Graver LM. Giant aneurysm of saphenous vein graft to coronary artery compressing the right atrium. *Ann Thorac Surg* 1999; **68**: 1433–7.
2. Le Breton H, Pavin D, Langanay T, et al. Aneurysms and pseudoaneurysms of saphenous vein coronary artery bypass grafts. *Heart* 1998; **79**: 505–8.
3. Benchimol A, Harris CL, Desser KB, Fleming H. Aneurysms of an aorto-coronary artery saphenous vein bypass graft—a case report. *Vasc Surg* 1975; **9**: 261–4.
4. Jukema JW, van Dijkman PR, van der Wall EE. Pseudoaneurysm of a saphenous vein coronary artery bypass graft with a fistula draining into the right atrium. *Am Heart J* 1992; **124**: 1397–9.
5. Gruberg L, Satler LF, Pfister AJ, Monsein LH, Leon MB. A large coronary artery saphenous vein bypass graft aneurysm with a fistula: case report and review of the literature. *Catheter Cardiovasc Interv* 1999; **48**: 214–6.
6. Fares W, Sharifi M, Steele R, et al. Superior vena cava syndrome secondary to saphenous venous graft aneurysm with right atrial fistula. *Catheter Cardiovasc Interv* 2003; **60**: 45–7.
7. Riahi M, Stone KS, Hanni CL, Fierens E, Dean RE. Right ventricular—saphenous vein graft fistula. Unusual complication of aorta-coronary bypass grafting. *J Thorac Cardiovasc Surg* 1984; **87**: 626–8.
8. Williams ML, Rampersaud E, Wolfe WG. A man with saphenous vein graft aneurysms after bypass surgery. *Ann Thorac Surg* 2004; **77**: 1815–7.
9. Dabboussi M, Saade YA, Poncet A, Baehrel B. Fistula between a saphenous vein graft aneurysm and the pulmonary artery trunk. *Ann Thorac Surg* 2001; **71**: 1356–8.