Original Article

Feasibility of Mitral Valve Repair Using the Loop Technique

Mikihiko Kudo, MD, Ryohei Yozu, MD, Kiyokazu Kokaji, MD, and Shirou Iwanaga, MD

Purpose: The most difficult aspect of chordal replacement in a mitral valve repair using expanded polytetrafluoroethylene (ePTFE) sutures, is determining the appropriate length of artificial chorda and ligation of the ePTFE sutures without the knot sliding.

Patients and Methods: We adopted a loop technique reported by Mohr et al. in 12 consecutive cases from October 2005. Nine cases were comparative broad-range prolapses of the posterior leaflet, 2 cases were anterior and the posterior leaflet and 1 case was vegetation of the anterior leaflet. Chordal replacement was done by 4 loops in 11 cases and by 8 loops in 1 case.

Results: Postoperative echocardiography showed more physiological movement of the posterior leaflet than by the resection suture method. When comparing of the peak pressure gradient across the mitral valve on echocardiography between the loop technique group and the non-loop technique group, the gradient in the loop technique group (n=11) was 1.8±0.7 mmHg and in the non-loop technique group (n=18) was 3.2±1.0 mm Hg. There was a significant statistical difference between 2 groups. The loop technique also seemed to be superior procedure hemodynamically.

Conclusion: This technique may be useful through both port-access minimally invasive cardiac surgery (MICS) and a conventional approach to the mitral valve, and simplifying chordal replacement. We report on the feasibility of the loop technique based on our experience. (Ann Thorac Cardiovasc Surg 2007; 13: 21–6)

Key words: loop technique, mitral valve repair, artificial chordae, expanded polytetrafluoroethylene, port-access minimally invasive cardiac surgery

Introduction

Chordal replacement with expanded polytetrafluoroethylene (ePTFE) has mainly been used in anterior leaflet repair. Prolapse of the posterior leaflet has been done using the resection on suture method.[1,2] Using the sliding method is difficult, but in cases where the posterior lesion is confined to the chorda tendineae, chorda replacement was undertaken. The most difficult aspect of chorda replacement using ePTFE sutures is avoiding the knot sliding and determining the correct length of artificial chordae. Various techniques have been proposed to address these problems.[3–7] von Oppell and Mohr reported a loop technique in which a pre-mesured loop is fixed into the prolapsed leaflet.[8] Using this technique, we used multiple loops and transferred them from the anterior to the posterior leaflet, creating a broad-range mitral valvuloplasty.[9] In this paper, we report on the application of the loop technique.

From Department of Surgery, Keio University, School of Medicine, Tokyo, Japan

Received May 23, 2006; accepted for publication July 19, 2006.
Address reprint requests to Mikihiko Kudo, MD: Department of Surgery, Keio University, School of Medicine, 35 Shinano-machi, Shinjuku-ku, Tokyo 160–8582, Japan.

Surgical Technique

The operative field for mitral valve needs to be developed for mitral valve repair to succeed. Port-access minimally invasive cardiac surgery (MICS) can regard a mitral valve as an alternative to conventional median ster-



Fig. 1.
A: A measuring device measures the distance (X), after having pulled rough zone with a hook as reference in a segment either adjacent or the opposite leaflet to the prolapsing segment.
B: a: Mohr suture ruler.
b: A ruler made by ourselves whose tip is flexibility.
c: Nelaton catheter.

notomy.[10,11] Therefore, port-access MICS is chosen first for mitral valve disease. After arriving at the mitral valve via the right side of left atriotomy, the normal part of the chordal length is measured as reference in the vicinity of the prolapse region (Fig. 1A). Two initial cases were measured using the Mohr suture ruler (03-5409:00, Geister Inc.). However, a ruler made by ourselves using a flexible tip or nelaton catheter is now used for measuring the appropriate length. This has been developed because measurement by Mohr suture ruler is difficult due to the device angle (Fig. 1B). This measured length becomes the new artificial chordal length. However, the length is decided by considering the actual degree of prolapse and configuration. In summary, when the length is decided as just the length of the reference, only the length of the prolapse part becomes longer because the leaflet is not removed surgically. Next, artificial chordal loops are made using CV-5 of ePTFE on a ruler. Two suture arms are brought twice through the pledget and ligated. This can be done quickly without regard for knot sliding which is the main weakness of ePTFE sutures. A uniform loop can be manufactured with our method even when making multiple loops (Fig. 2A). Only the number of loops required for reconstruction were made previously, but now 4 loops are made for 1 papillary muscle (Fig. 2B). Each loop is the same length, and is fixed by ligating both needles of CV-5 after penetrating twice through a pledget. In addition, another CV-5 sutures is put through each loop beforehand to save time (Fig. 3). This modification allows prompt fixing with the correct turn of loops. The operator sews sutures on the mitral annulus for artificial ring insertion during manufacture of the loops.

The two suture arms of the loop are passed through the papillary muscle horizontally and tied down after being passed through the pledget (Fig. 4A). One loop acting as artificial chorda is fixed approximately in the rough zone of the prolapse leaflet using another CV-5 suture (Fig. 4B). This method can form a natural coaptation line so that the knots of CV-5 sutures are located in the left ventricle and the loop is located in the left atrium. Thin sutures such as monofilament sutures are not used for fixing the loop because of the danger of cutting the loops, therefore homogenous sutures (CV-5) are used.[11] A leakage test is performed after attaching 1 loop. Then the loops are fixed to the necessary points. Currently, 1 artificial chorda of 4 loops is standard and replacement of artificial chordal in 8 places is possible in 2 papillary muscles. After artificial chordal replacement, a ring annuloplasty is done.

Results

This technique has been employed in 12 consecutive cases

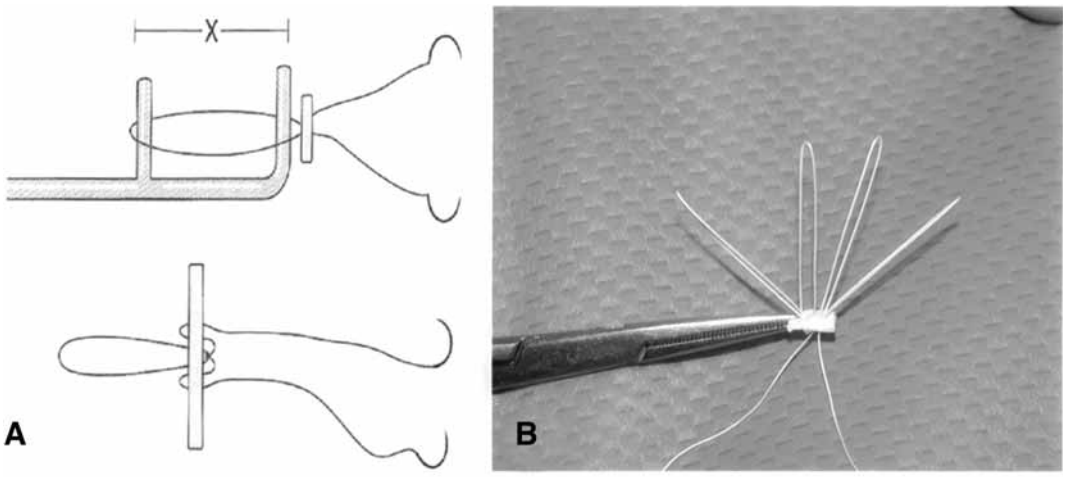

Fig. 2. A: A needle of both ends of loop is ligated in the back through a pledget. X, measuring length.
B: We make 4 loops at once about 1 papillary muscle.

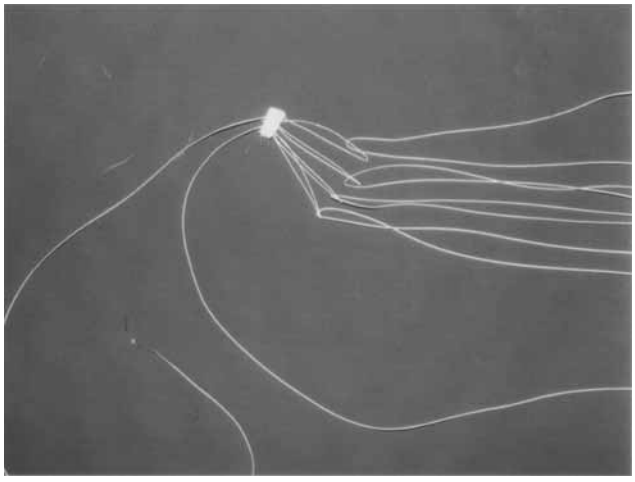

Fig. 3. After artificial chordal manufacture, CV-5 sutures are used for fixing through each loop. This modification allows prompt fixing with a right turn of the loop.

since October 2005. Nine cases were comparative broad-range prolapse of the posterior leaflet, 2 cases involved both leaflets and 1 case was of vegetation of the anterior leaflet. Chordal replacement was done by 4 loops in 11 cases, and by 8 loops in 1 case. For ring annuloplasty, we select a slightly bigger artificial annular ring because of the development of systolic anterior motion (SAM) by excessive valve leaflet movement. Since 1996, we have performed 146 cases of mitral valve repair, in which the conventional approach was used in 75 cases and port-access MICS in 71 cases. We operated on 11 cases using the port-access approach, and on 1 case using a conventional sternotomy. A loop technique with this simple reconstructive method was effective in the port-access method (Table 1). Postoperative echocardiography showed better movement of the posterior leaflet than by the resection suture method. Comparing the mean pressure gradient across the mitral valve on echocardiography between the loop technique group (n=11) and the non-loop technique group (n=18), the gradient was 1.8±0.7 mmHg in the loop technique group and 3.2±1.0 mmHg in the non-loop technique group, showing a significant statistical difference between 2 groups (p=0.001). The loop technique also seemed to be a superior procedure hemodynamically (Fig. 5).

Discussion

The method of reconstructing artificial tendon chorda by ePTFE was reported in 1985.[10] Although ectal hyperplasia by fibrous coating is acceptable,[12] this method is superior in histocompatibility, because it has same flexibility as a native chordae, and it has long-term durability.[13] Zussa et al.[3] and David et al.[4] reported on its clinical application, and the procedure has spread widely in Japan since Kawazoe et al.[5] reported it. On the other hand, ePTFE sutures have the weakness of slipping easily at ligation. In artificial chordal reconstruction using ePTFE sutures, various techniques to maintain the correct length of chorda have been reported. When fixing the ePTFE

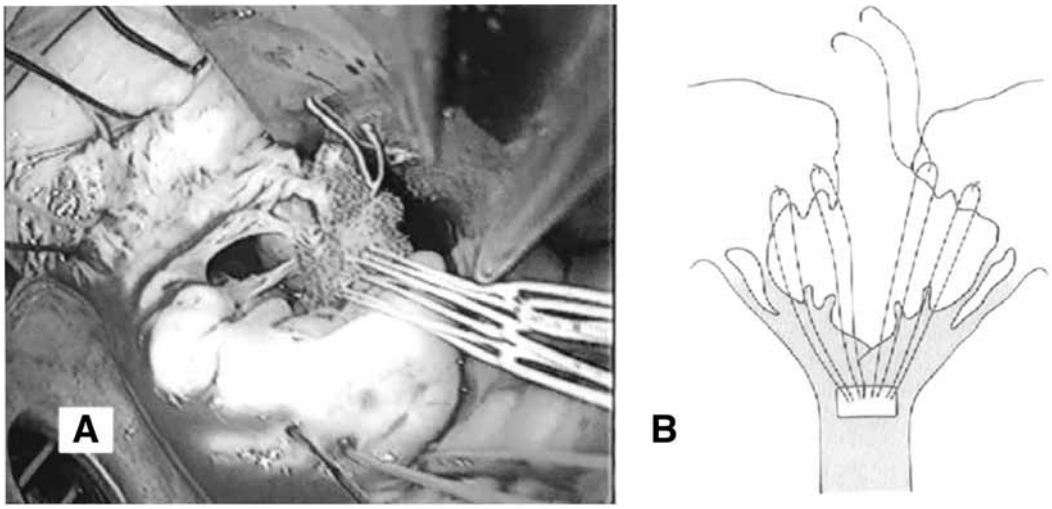

Fig. 4. **A:** Intraoperative view of the fixation of the artificial chordal loop to the papillary muscle (port-access method). **B:** One loop of artificial chorda is fixed in the rough zone of the prolapse leaflet using another CV-5 sutures.

Table 1. Case of mitral valve repair using loop technique

	Approach	Part of repair	Articifial ring	Postoperative MR
1	Port-access MICS	P2	Physio ring 34	None
2	Port-access MICS	P2, P3	Physio ring 32	None
3	Port-access MICS	P3, PC	Duran band 31	Trivial
4	Port-access MICS	P2	Physio ring 32	None
5	Full sternotomy	P1, P2, P3	Cosgrove ring 30	Mild
6	Port-access MICS	P2	Duran band 33	Trivial
7	Port-access MICS	P3	Cosgrove ring 34	None
8	Port-access MICS	P2	Duran band 33	Trivial
9	Port-access MICS	P3, A3	Cosgrove ring 34	None
10	Port-access MICS	P2	Duran band 33	None
11	Port-access MISC	P1, A1	Cosgrove ring 34	None
12	Port-access MICS	A2	(–)	Trivial

MICS, minimally invasive cardiac surgery; PC, posterior comissure; MR, mitral regurgitation.

sutures to 1 leaflet after sewing it to the papillary muscle, various maneuvers have been reported, such as bringing each arm of the suture through the leaflet edge twice to create friction.[4] Self-pericardium and pledget are used which is fixing to increase the coaptation area.[3,5] When deciding on the correct length of the artificial chorda, Kasegawa et al. reported on a simple technique of using a small tourniquet to adjust the lengths of the ePTFE sutures, before tying them during the leakage test after ring annuloplasty.[6] Matsumoto et al. reported on a simple technique to ligate ePTFE sutures to the contralateral normal length after putting them through the rough zone to the papillary muscle.[7] Techniques of tying the ePTFE without sliding include weaving the suture through the leaflet to the mitral annulus,[13] and using a hemostat clips[3] and forceps[6] to temporary fix sutures. In contrast with these methods, a loop technique is a new and simple technique of using premeasured ePTFE loops to replace diseased chordae and makes it easier for the surgeon to repair the mitral valve.

The advantages of this loop technique include: 1) when there is no destruction of the leaflet, partial resection of prolapsed leaflet is unnecessary; 2) if the leakage test shows regurgitation, immediate revision is possible by cutting the fixing CV-5 suture; 3) the dimensions of artificial tendon chorda can be finely adjusted by fixing the loop at 2 vertical or transverse points; 4) when the loop remains, the remaining loop can be fixed to the leaflet in

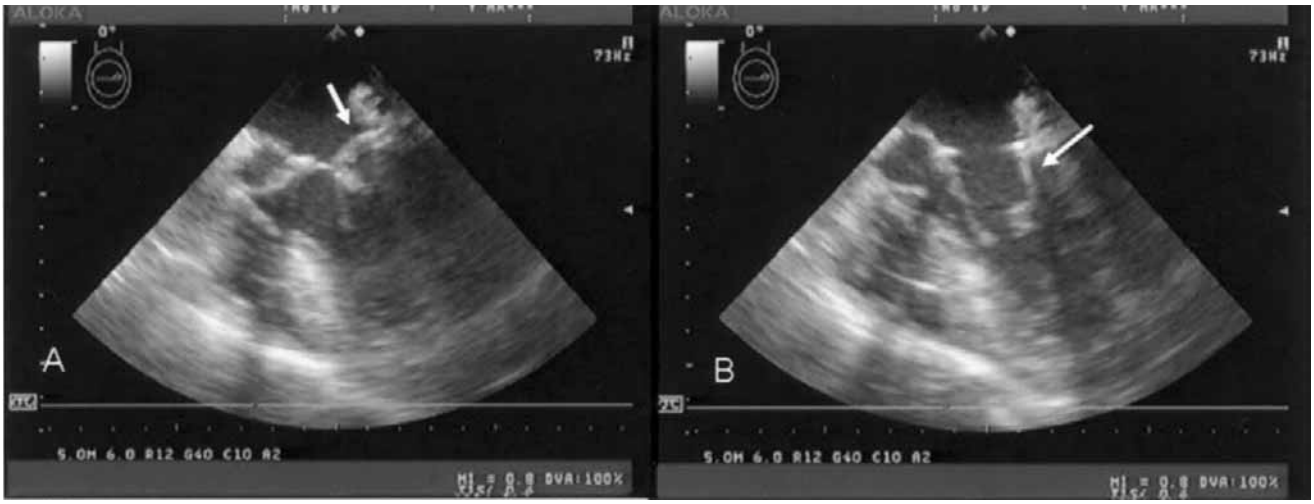

Fig. 5. Postoperative echocardiography.
A: Echocardiography revealed disappearance of mitral regurgitation at systolic phase. Arrow, repaired posterior leaflet.
B: Physiological opening of posterior leaflet at diastolic phase. Arrow, repaired posterior leaflet.

a mass. In cases of prolapse of the posterior leaflet without leaflet destruction, the resection suture method or sliding method had been used for mitral valve repair before introduction of the loop technique, and the artificial chordae replacement for the posterior leaflet was a supporting element. A difference between 2 groups in comparing the mean pressure gradient across the mitral valve on echocardiography may not correlate with clinical symptoms. However, valvular excision and re-suture can cause partial degradation of leaflet mobility as a result of consolidation and cicatrisation. Ideally, physiological movement of the leaflet should be kept if possible. Except in the case of perforation, remarkable hyperplasia and extreme anamorphosis of the leaflet, the leaflet can be preserved by using the loop technique. Therefore, replacement of the multiple chorda is fundamental to achieve a broad-range reconstruction. In addition, mitral valve repair of Barlow's type appears to be possible by transplanting a loop into anterior and posterior leaflets.

An artificial ring with a larger diameter than in the resection suture method was selected. Generally, the artificial ring enhances the coaptation zone by shortening the mitral annular diameter, reinforcing the suture site, and preventing annulus re-dilatation and remodeling of the mitral annulus. However, in the case of the loop technique, the artificial annular ring is used for preventing annulus dilatation since mitral annular plasty with a small ring diameter may cause SAM. At first, we performed full annuloplasty using slightly bigger semi-flexible or flexible artificial rings even in cases of a posterior leaflet plasty, and we now do partial annuloplasty for reconstructive locus using a flexible ring. The ring sizes of 11 cases were 30–34 mm.

We describe the feasibility of the loop technique. Although no problems occurred when using the previous procedure and its results were acceptable, we have adopted this new method as it is simple, immediate revision is possible, and comparison with a resection suture method shows it to be hemodynamically superior.

Conclusion

We report on the technique and feasibility of the loop reconstruction based on our experience. This chordal replacement technique can be useful through both port-access MICS and conventional approaches to the mitral valve, and simplifies chordal replacement with port-access MICS.

References

1. Frater RW. 10th Goretex chorda anniversary. *J Heart Valve Dis* 1996; **5**: 348–51.
2. David TE, Armstrong S, Sun Z. Replacement of chordae

tendineae with Gore-Tex sutures: a ten-year experience. *J Heart Valve Dis* 1996; **5**: 352–5.
3. Zussa C, Frater RW, Polesel E, et al. Artificial mitral valve chordae: experimental and clinical experience. *Ann Thorac Surg* 1990; **50**: 367–73.
4. David TE, Bos J, Rakowski H. Mitral valve repair by replacement of chordae tendineae with polytetrafluoroethylene sutures. *J Thorac Cardiovasc Surg* 1991; **101**: 495–501.
5. Kawazoe K, Eishi K, Sasako Y, et al. Clinical experience of mitral valve reconstruction with artificial chordae implantation. *Eur J Cariothorac Surg* 1992; **6**: 297–301.
6. Kasegawa H, Kamata S, Hirata S, et al. Simple method for determining proper length of artificial chordae in mitral valve repair. *Ann Thorac Surg* 1994; **57**: 237–9.
7. Matsumoto T, Kado H, Masuda M, et al. Clinical results of mitral valve repair by reconstructing artificial chordae tendineae in children. *J Thorac Cardiovasc Surg* 1999; **118**: 94–8.
8. von Oppell UO, Mohr FW. Chordal replacement for both minimally invasive and conventional mitral valve surgery using premeasured Gore-Tex loops. *Ann Thorac Surg* 2000; **70**: 2166–8.
9. Kudo M, Yozu R. My technique. How to hang sutures of artificial tendon chorda. In: Yozu R ed., Usefulness of Loop technigue method. Knack and Pitfalls of valvular surgery. Tokyo: Bunkodo, 2005; pp 34–36.
10. Yozu R, Shin H, Maehara T, et al. Port-access cardiac surgery. Experience with 34 cases at Keio University Hospital. *Jpn J Thorac Cardiovasc Surg* 2001; **49**: 360–4.
11. Yozu R, Shin H, Maehara T. Minimally invasive cardiac surgery by the port-access method. *Artif Organs* 2002; **26**: 430–7.
12. Vetter HO, Burack JH, Factor SM, et al. Replacement of chordae tendinae of the mitral valve using the new expanded PTFE suture in sheep. In: Bodnar E, Yacoub M eds., Biologic and Bioprosthetic Valves. New York: York Medical Books, 1985; pp 772–84.
13. Revuelta JM, Garcia-Rinaldi R, Gaite L, et al. Generation of chordae tendineae with polytetrafluoroethylene stents. Results of mitral valve chordal replacement in sheep. *J Thorac Cardiovasc Surg* 1989; **97**: 98–103.