Case Report

Atherosclerotic Aneurysm of the Right Subclavian Artery: Report of a Case

Shigeki Tabata, MD, Hiroshi Saito, MD, Masaya Takizawa, MD, and Takehisa Imagawa, MD

Subclavian artery aneurysms are uncommon. The most common causes of these aneurysms are atherosclerosis and traumatic pseudoaneurysm. We report on a case of an atherosclerotic aneurysm of the right subclavian artery. The aneurysm was resected with a combined supra-infraclavicular approach, and a primary end-to-end anastomosis was performed. The postoperative course was uneventful. In arteriosclerotic cases, the axillobrachial artery is frequently tortuous, and the proximal axillary artery can be mobilized. If possible, a direct end-to-end anastomosis is recommended for the aneurysm of the distal part of the subclavian artery. (Ann Thorac Cardiovasc Surg 2007; 13: 139–42)

Key words: subclavian artery aneurysm, atherosclerosis, peripheral artery aneurysm

Introduction

True subclavian artery aneurysm (SAA) is rare, as seen in a report by Dent et al.[1] in which SAA represented only 0.1% of the extensive series of atherosclerotic aneurysm. Other reported causes of SAAs include trauma, thoracic outlet syndrome (TOS), and infection. Cystic medial necrosis, Marfan syndrome, Turner's syndrome, and other genetic syndromes have been reported as less frequent causes of SAAs. They represent a significant risk for rupture, embolization, or thrombosis, and therefore should be considered for surgical treatment.[2] We present here our experience with an aneurysm of the right subclavian artery, and review the literature on the management of this rare vascular entity.

Case Report

The patient was a 64-year-old man whose chief complaint was a pulsatile right supraclavicular mass. He had undergone a partial gastrectomy due to peptic ulcer and had a medical history for hypertension. He had no history of traumatic lesions, infective disease, or upper extremity embolic symptoms. Physical examination revealed a pulsatile hard mass in the right supraclavicular fossa. The lung was clear and the upper extremities were neurovascularly intact. Blood work was within normal limits. The chest X-ray was normal. Chest computed tomography (CT) demonstrated a right SAA measuring 3.0×2.0 cm (Fig. 1). Three-dimensional CT reconstruction revealed an aneurysm in the third portion of the right subclavian artery (Fig. 2). Magnetic resonance angiography (MRA) revealed an aneurysm measuring 4.5×3.0 cm, and that the axillobrachial artery is frequently tortuous (Fig. 3).

The patient underwent surgical management. Two incisions were performed for this procedure. The first incision was placed above the clavicle, and the sternocleidomastoid muscle was divided. The subclavian artery proximal to the aneurysm was denuded. The other incision was placed in the infraclavicular site, and the pectoral muscles were split to mobilize the axillary artery. The aneurysm was resected, and the artery was reconstructed with a primary end-to-end anastomosis. The postoperative course was optimal, and the patient was discharged on the 11th postoperative day. Postoperative MRA showed good patency (Fig. 4). A noninvasive survey of the vascular tree

From Department of Thoracic and Cardiovascular Surgery, Kouseiren Takaoka Hospital, Takaoka, Japan

Received August 28, 2006; accepted for publication September 3, 2006.
Address reprint requests to Shigeki Tabata, MD: Department of General and Cardiothoracic Surgery, Kanazawa University School of Medicine, 13-1 Takara-machi, Kanazawa, Ishikawa 920–8641, Japan.

Fig. 1. Chest CT reveals a 3.0×2.0 cm aneurysm of the right subclavian artery.

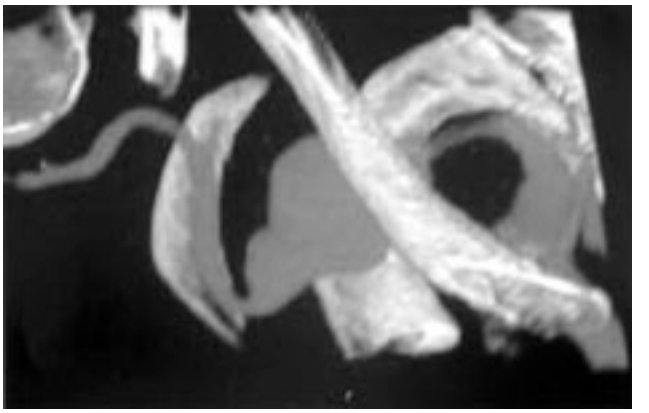

Fig. 2. Three-dimensional CT reveals an aneurysm in the third portion of the right subclavian artery.

Fig. 3. MRA reveals an aneurysm measuring 4.5×3.0 cm of the right subclavian artery.

Fig. 4. Postoperative MRA shows good patency of the reconstruction.

did not reveal any other aneurysm, except for a small aneurysm of the left SAA. Pathologic review was consistent with an atherosclerotic aneurysm without thrombosis.

Discussion

True SAAs are infrequent. Dent et al. reviewed the location of atherosclerotic aneurysms in 1,488 patients, with isolated subclavian lesions occurring in only two patients (0.13%).[1] In 1864, Smyth performed the first successful proximal ligation of an SAA.[3] The first successful resection and graft replacement of a saccular aneurysm involving the subclavian artery was reported by Bahnson in 1953.[4]

Early case reports of SAAs related predominately to

traumatic pseudoaneurysms. However, in a 1995 review, Dougherty et al.[5] found 64 patients with 70 SAAs reported in the literature since 1926. The most common etiology of true SAAs is atherosclerosis, accounting for 60% of the reported cause, followed by infectious aneurysms (syphilis,15%; tuberculosis, 10%; bacterial, few). Marfan syndrome and cystic medial necrosis represented 10% of the cases.[5–7] True aneurysm of the distal part of the subclavian artery is mostly a poststenotic one belonging to the TOS, but it is vary rare. In literature, the incident accounts for 1.1% in patients with TOS.[8]

The most commonly reported symptom of SAA is chest or shoulder pain. A pulsatile subclavicular mass may also be present. Neurologic involvement, such as hoarseness, dysphasia, or Horner's syndrome has been reported. Other clinical presentations include rupture, thrombosis, and peripheral emboli that results in upper extremity ischemia or a cerebral vascular accident.[2] Rarely, hemoptysis or dyspnea due to tracheal compression are presented.

Diagnosis of SAA can be easily accomplished with CT, but routine CT does not provide sufficient detail for complete diagnosis. Angiography is always mandatory for planning the surgical treatment,[9] but may not completely demonstrate the distal subclavian artery in some cases because of contrast medium dilution.[10] MRA may be an alternative examination, especially when a contraindication to angiography is present.[5] On the other hand, three-dimensional CT reconstructions can be used to demonstrate the whole cervical vasculature, even showing how the proximal and distal subclavian arteries are connecting to the aneurysm.[10] It is recommended to search for other aneurysms of the vascular tree because their presence has been reported in as many as 33–47% of the patients with SAAs.[11]

Surgery has been the mainstay of therapy for SAA. The surgical approach to the extrathoracic SAA is often feasible simply through the combined supra-infraclavicular incision as applied in our case. Right-sided intrathoracic SAAs are approached through a median sternotomy, whereas left-sided aneurysms can be approached through a high left posterolateral thoracotomy. It is always necessary to eliminate the cause in case of poststenotic distal aneurysms belonging to TOS. An extirpation of a cervical rib or a resection of the first rib is performed before a procedure of an aneurysm. The axillary approach is suitable for management of a distal aneurysm. It is necessary to take care of the brachial plexus, the recurrent and phrenic nerve and the thoracic duct during preparation

In the early reports, operations for SAA were limited to simple ligation without revascularization.[3] Repair of the aneurysm has been attempted by several techniques which include partial excision of the sac and repair by aneurysmorrhaphy or a patch repair with prosthetic material. Nowadays, resection of the aneurysm and revascularization is the common procedure. Arterial reconstruction options include anatomic reconstruction with interposition graft, primary end-to-end anastomosis, and extra-anatomic reconstruction such as carotid-subclavian transposition or bypass grafting. We recommend direct end-to-end anastomosis, even if the aneurysm of the distal part of the subclavian artery is large, because the axillobrachial artery is frequently tortuous in arteriosclerotic cases where the proximal axillary artery can be mobilized.[12] Reports of successful transluminal endovascular procedures in peripheral aneurysms have been published.[13–15] Despite the lack of long-term follow-up, this technique seems to be promising, especially for high-risk candidates.

References

1. Dent TL, Lindenauer SM, Ernest CB, Fry W. Multiple arteriosclerotic arterial aneurysms. *Arch Surg* 1972; **105**: 338–44.
2. Pairolero PC, Walls JT, Payne WS, Hollier LH, Fairbairn JF. Subclavian-axillary artery aneurysms. *Surgery* 1981; **90**: 757–63.
3. Thomas V. Intrathoracic aneurysm of the innominate and subclavian arteries. *J Thorac Cardiovasc Surg* 1972; **63**: 461–71.
4. Bahnson HT. Definitive treatment of saccular aneurysms of the aorta with excision of sac and aortic suture. *Surg Gynecol Obstet* 1953; **96**: 383–402.
5. Dougherty MJ, Calligaro KD, Savarese RP, DeLaurentis DA. Atherosclerotic aneurysm of the intrathoracic subclavian artery: a case report and review of the literature. *J Vasc Surg* 1995; **21**: 521–9.
6. Applebaum RE, Caniano DA, Sun CC, Azizkhan RA, Queral LA. Synchronous left subclavian and axillary artery aneurysms associated with melorheostosis. *Surgery* 1986; **90**: 249–52.
7. Akasaka T, Mitsuishi T, Nakajima H, Suzuki R, Shimizu S. Aneurysm of the left subclavian artery associated with Turner's syndrome: successful surgical treatment. *J Cardiovasc Surg* 1989; **30**: 945–9.
8. Utikal P, Bachleda P, Kocher M, Novotny J, Drac P, Drac P. Aneurysm of the subclavian artery. *Acta Univ Palacki Olomuc Fac Med* 1999; **142**: 107–9.
9. Davidovic LB, Markovic DM, Pejkic SD, Kovacevic NS, Colic MM, Doric PM. Subclavian artery aneurysms. *Asian J Surg* 2003; **26**: 7–11.
10. Miyamoto S, Hadama T, Iwata E, et al. Atheroscle-

rotic aneurysm of the intrathoracic segment of the subclavian artery: a case report. *Ann Thorac Cardiovasc Surg* 2000; **6**: 281–4.
11. McCann RI. Basic data related to peripheral artery aneurysms. *Ann Vasc Surg* 1990; **4**: 411–4.
12. Saito H, Tatsuzawa T, Kikkawa H, Hirano M, Sakatoku M, Doden K. Giant arteriosclerotic aneurysm of the axillary artery. *J Cardiovasc Surg* 1989; **30**: 134–5.
13. May J, White G, Waugh R, Yu W, Harns J. Transluminal placement of a prosthetic graft-stent device for treatment of subclavian aneurysm. *J Vasc Surg* 1993; **18**: 1056–9.
14. Ackroyd R, Singh S, Beard JD, Gaines PA. Simultaneous brachial embolectomy and endoluminal stenting of a subclavian artery aneurysm. *Eur J Vasc Endovasc Surg* 1995; **10**: 248–9.
15. Meyer T, Merkel S, Lang W. Combined operative and endovascular treatment of a post-traumatic embolizing aneurysm of the subclavian artery. *J Endovasc Surg* 1998; **5**: 52–5.