Review

The Revolution of Thoracotomy for Lung Cancer Surgery

Kiyoshi Koizumi, MD

The revolution of thoracic surgery was brought about by a thoracoscopic approach to the thorax. Until the 1960s, thoracic surgery had been developed primarily for pulmonary tuberculosis. The incidence of lung cancer will increase worldwide during the next 30 years, and the annual incidence of lung cancer in Japan is expected to increase to about 150,000 by 2015. Over the past 50 years, pulmologists and radiologists have performed clinicopathological studies to prevent lung cancer. Early detection became possible with these efforts; as a result, the rate of lung cancer detection at stage I disease has increased. Around 1995, the frequency of the histological incidence of small adenocarcinoma and of peripheral squamous cell carcinoma has increased. Thus thoracic surgeons have refined surgical procedures, such as limited pulmonary resection, and have established a minimally invasive approach to the thorax. These successes were followed by the development of thoracoscopic surgery to cover the world by the end of 20th century. However, minimally invasive surgery involving limited pulmonary resection and/or the thoracoscopic approach, which allows for functional preservation and effectiveness, has not yet been clarified as lung cancer treatment. Future investigations and the refinement of technologies are needed. (Ann Thorac Cardiovasc Surg, 2007; 13: 228–235)

Key words: lung cancer, lobectomy, thoracotomy, video-assisted thoracic surgery

Introduction

The history of surgery is characterized as a reduction of surgical intervention. This is because surgical treatment involves two opposed pursuits, namely, curability and functional preservation. Various trials and discussions regarding these pursuits have continued since Graham reported on the left pneumonectomy for primary lung cancer in 1933.[1–3] In 1960 Cahan recommended anatomical lobectomy with systemic mediastinal lymphadenectomy as "radical lobectomy" to achieve the balanced surgical effects of both curability and functional preservation.[4] Subsequently, the verification of curability was evaluated according to mediastinal lymphadenectomy, and functional preservation with the development of limited surgery and a minimally invasive approach to the thorax was investigated.[5–8] Experimental studies on anatomical pulmonary resection, such as lobectomy and segmentectomy by thoracoscopy, were performed.[9,11] In 1993, Lewis introduced the role of video-assisted thoracic surgery (VATS), utilizing thoracoscopy and minithoracotomy for carcinoma of the lung.[10] From 1993 to 2007, thoracoscopic surgery has become widely utilized for chest diseases. Many clinical researches have been performed to evaluate whether thoracoscopic surgery has become truly advantageous for functional preservation and whether it can achieve curability equal to that with conventional open thoracotomy; however, the results remain unclear.[12–14,16–40] Therefore I would like to review the background of lung cancer patients and changes in surgical procedures regarding the advantages and disadvantages particularly in Japan.

From Division of Thoracic Surgery, Department of Surgery, Nippon Medical School, Tokyo, Japan

Received April 9, 2007; accepted for publication July 30, 2007
Address reprint requests to Kiyoshi Koizumi, MD: Division of Thoracic Surgery, Department of Surgery II, Nippon Medical School, 1–1–5 Sendagi, Bunkyo-ku, Tokyo 113–8603, Japan.

1. Changes in cause of death: pulmonary tuberculosis and lung cancer

According to the historical aspects of the lung cancer

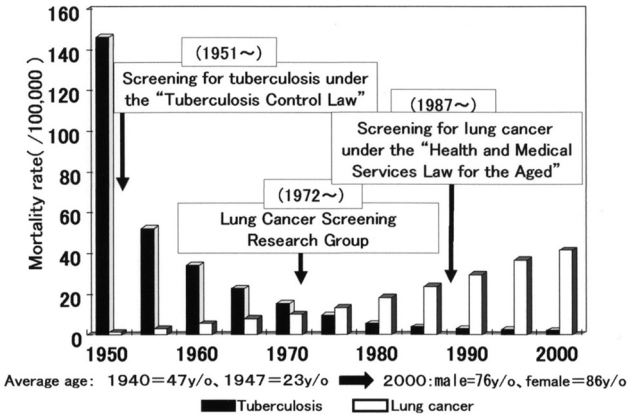

Fig. 1. Changes in the mortality rate from pulmonary tuberculosis and lung cancer during the 1950s and the 2000s.
Before World War II, tuberculosis had a very high mortality rate among the Japanese. Since the mid-1930s, mass screening for pulmonary tuberculosis has been carried out in Japan by chest X-rays. After the war, a nationwide program was established that offered an annual screening free of charge under the "Tuberculosis Control Law." Despite a rapidly decreasing mortality rate from tuberculosis throughout the 1950s and 1960s, deaths from lung cancer began to increase at this time (from Suzuki T, Osaka Medical Center for Cancer and Cardiovascular Diseases).

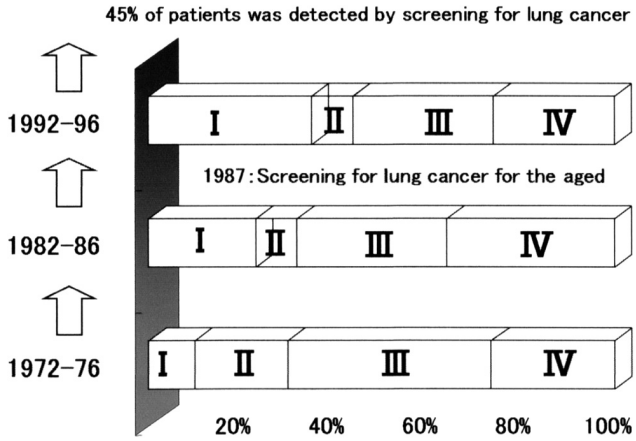

Fig. 2. In Japan, advanced lung cancer, stage III or more, accounted for 70% of all stages during 1972 and 1986, but it had markedly decreased by 1996, resulting in an increase in the percentage of patients with stage I or II disease, following the nationwide implementation of the regular health examination system enacted by screening for lung cancer in 1987.

screening system in Japan, the death rate from lung cancer has surpassed that from pulmonary tuberculosis, which until the mid-1970s was managed by the screening of tuberculosis under the "Tuberculosis Control Law" enacted in 1951. According to this change, the Japanese Lung Cancer Society was established in 1960, and a lung cancer screening research group was organized in 1972. In 1987, the screening for lung cancer under the "Health and Medical Services Law for the Aged" was developed, established, and implemented nationwide (Fig. 1). In 1998, lung cancer became the most common of cancer deaths in Japan, and death rates for males and females were similar. Annual deaths from lung cancer have exceeded 50,000, which is about 18% of all carcinoma deaths. The incidence of lung cancer will increase in the next 30 years worldwide, and the annual incidence of lung cancer in Japan is expected to reach about 150,000 by 2015. In the 1950s, its incidence was higher in the advanced nation, and pulmonary tuberculosis was common in developing countries. The average age of Westerners was about 70 at that time in comparison to 47 in Japan before World War II. Since then, the average age of Japanese has been prolonged to 86 in females and 76 in males at the end of 20th century, followed by an increase of the lung cancer population. Furthermore the average age of patients became higher associated with several concomitant diseases. Therefore, the thoracic surgeon has developed a less invasive approach to the thorax and minimal pulmonary resection to save physical reserve after surgery.

2. Changes in stage of disease and histological types of primary lung cancer

As for the recent stages of lung cancer in Japan, the advanced stage III lung cancer or higher accounted for 70% of all stages during 1972 and 1986, but they had markedly decreased by 1996, following a nationwide implementation of the regular health examination system enacted in 1987 by screening for lung cancer under the "Health and Medical Services Law for the Aged." In the past five years, more than 45% of patients who underwent surgery for primary lung cancer had been detected and diagnosed with primary lung cancer by a screening examination (Fig. 2). The central type of squamous cell carcinoma was previously the most common type of lung cancer, but peripheral squamous cell carcinoma has now become more common. This change has been attributed to self-regulation with respect to direct or indirect cancer-causing factors such as smoking. Furthermore, the decrease in the incidence of central squamous cell carcinoma has influenced a type of surgical procedure that I will mention later.

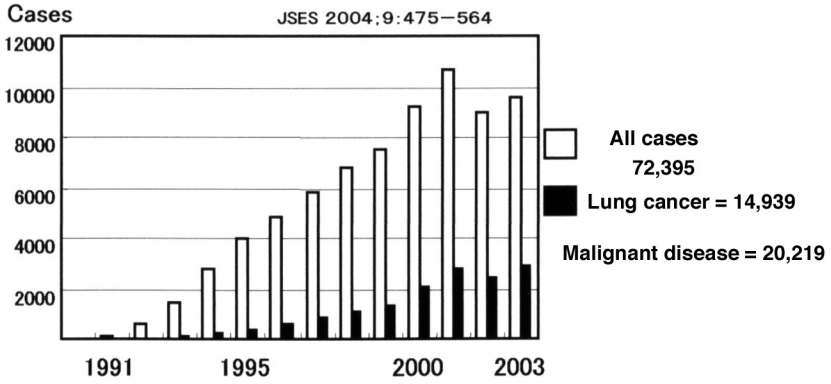

Fig. 3. The actual conditioning performed by the Japan Society for Endoscopic Surgery (JSES) reported that among all thoracoscopic surgeries, malignant pulmonary disease was 20,219, consisting of 14,939 cases of primary lung cancer (20.6% of all thoracoscopic surgeries).

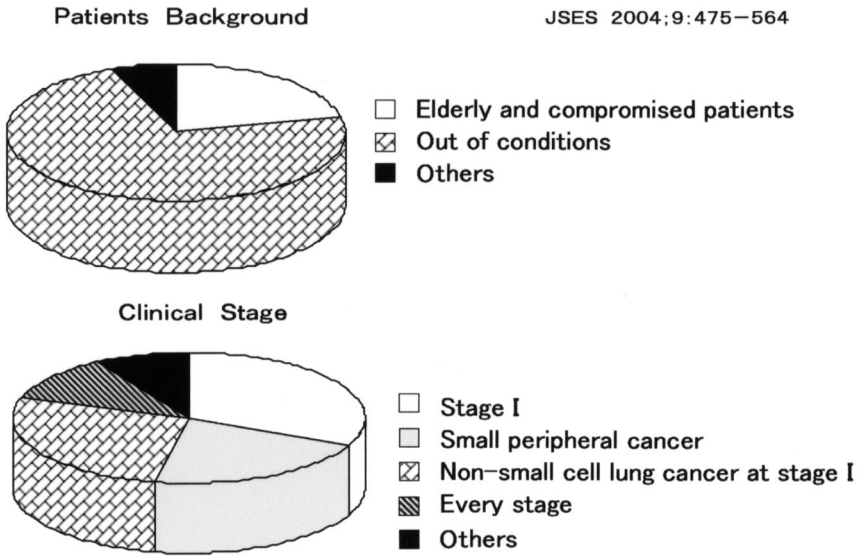

Fig. 4. Video-assisted thoracic surgery (VATS) was utilized for small peripheral lung cancer, and its advantages were expected in elderly patients and/or compromised patients.

3. Changes in surgical procedures

With the increase in the average life span, the increase of elderly lung cancer patients has become an important problem surgically. Elderly patients often have concomitant diseases, such as ischemic heart disease, chronic pulmonary disease, and diabetes mellitus, which are serious problems during perioperative periods. Over the past decade, limited pulmonary resection has been utilized for small peripheral lung cancers supported by these phenomena[6, 7]. Subsequently, VATS was introduced to lung cancer surgery as a minimally invasive approach to the thorax, which allows performing anatomical pulmonary resection with lymphadenectomy (Fig. 3). Muscle-sparing thoracotomy (MST) was introduced by Ginsberg as an alternative to posterolateral thoracotomy to reduce chest wall injury.[15] As a bridging procedure between VATS and posterolateral thoracotomy, MST has been utilized and investigated regarding invasiveness to the chest wall and the postoperative course.[16]

4. Verification of VATS as a minimally invasive surgery

In Japan, cost of thoracoscopic surgery was covered by health insurance since April 1, 1994. According to an investigation into the actual conditioning during 1993 and 2003 performed by the Japan Society for Endoscopic Surgery (JSES) in 2004, the total number of thoracoscopic surgeries was 72,395 cases among 487,111 endoscopic surgeries and held third rank. Among all thoracoscopic surgeries, malignant pulmonary disease surgeries totaled 20,219, consisting of 14,939 patients with primary lung cancer (20.6% of all thoracoscopic surgeries) (Fig. 3).

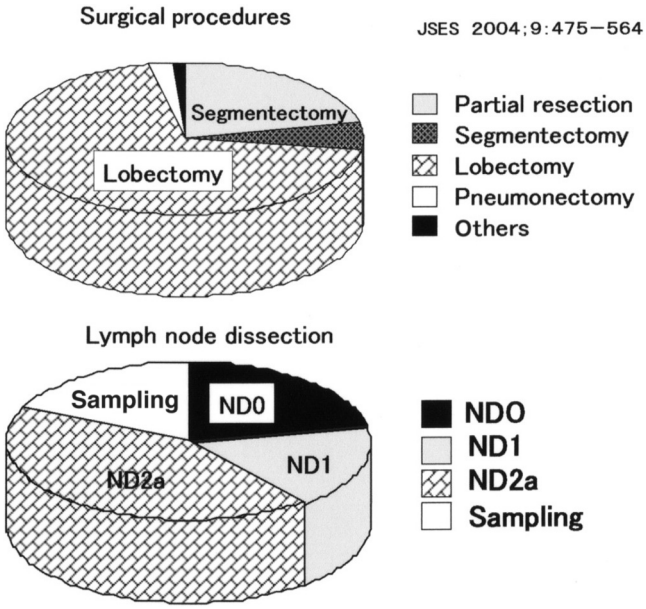

Fig. 5. Video-assisted thoracic surgery (VATS) for lung cancer surgery aimed to perform anatomical pulmonary resection for the purpose of curative lung cancer surgery.

When we consider the future of surgical treatment, it is believed that thoracoscopic surgery will spread to reduce the surgical injuries of elderly patients and/or compromised patients, and also early-stage lung cancer patients (Fig. 4). Thus the verification of thoracoscopic surgery for lung cancer started with surgery-related factors, functional factors, and tumor-related factors.

(1) Surgical procedures

Since Cahan recommended a "radical lobectomy with mediastinal lymphadenectomy" by open thoracotomy, anatomical pulmonary resection was used as an ideal method with which to control cancer progression. Therefore even in VATS or thoracoscopic surgery, anatomical pulmonary resection, i.e., lobectomy and segmentectomy with mediastinal lymphadenectomy, was performed (Fig. 5). VATS is performed by using a few entry ports and one minithoracotomy to enter the thorax, as shown in Fig. 6 and in a bird-eye's view during a VATS lobectomy (Fig. 7). The issue of whether equal mediastinal lymphadenectomy is feasible by VATS has been long discussed among thoracic surgeons.[18–22]

(2) Surgically related factors

As for surgically related factors, the duration of a lobectomy with mediastinal lymphadenectomy by VATS was considered as being longer than that by open thoracotomy, but it became shorter with the learning curve of practice. The blood loss during VATS lobectomy is significantly more minimal than that of a lobectomy by open thoracotomy. However, intrapleural adhesion, inflammatory change, and incomplete lobation influence the duration of surgery and the amount of blood loss in both groups. In many reports concerning surgical intervention of VATS lobectomy, by analyzing postoperative serum creatine phosphokinase (CPK) we find that chest wall damage seems minimal.[16,17,21,26]

(3) Postoperative inflammatory changes

A thoracic surgeon needs to know about postoperative inflammatory responses associated with extended stress because of surgical intervention. Several authors reported that the serum C-reactive protein (CRP) level was lower and the change in blood interleukin-6 (IL-6) level was also less in VATS lobectomies than in those by open thoracotomy.[19,26–30]

(4) Immunological responses

Immunosuppression associated with surgery may predispose a patient to an increased tumor growth or recurrence. Lymphocytes have a central immune network and reply to a peculiar marker by tumor immunosurveillance, which is a nonspecific reaction. Leaver measured postoperative lymphocyte counts, CD4, CD8, CD19, and natural killer T cells with respect to immunosuppression and reported that a lobectomy showed strong effects for immunosuppression.[29,30] On the other hand, as for the dissemination of cancer cells, Yamashita et al. mentioned that the detection of circulating tumor cells in patients who underwent VATS lobectomies showed a potential hazard because of intraoperative manipulation.[31] These findings indicate continued further investigation.

(5) Influence on changes in pulmonary function

An advantage of changes in pulmonary function was reported by several authors,[32,33] The recovery of pulmonary function was significantly quick in VATS lobectomy postoperatively. Lobectomy itself seemed to be as advantageous as that of lung volume reduction surgery (LVRS) for patients with severe pulmonary emphysema, and this tendency was remarkable in patients who underwent VATS.[34] Furthermore, the VATS approach seemed to be beneficial in patients suffering from interstitial pneumonia and in patients with poor pulmonary

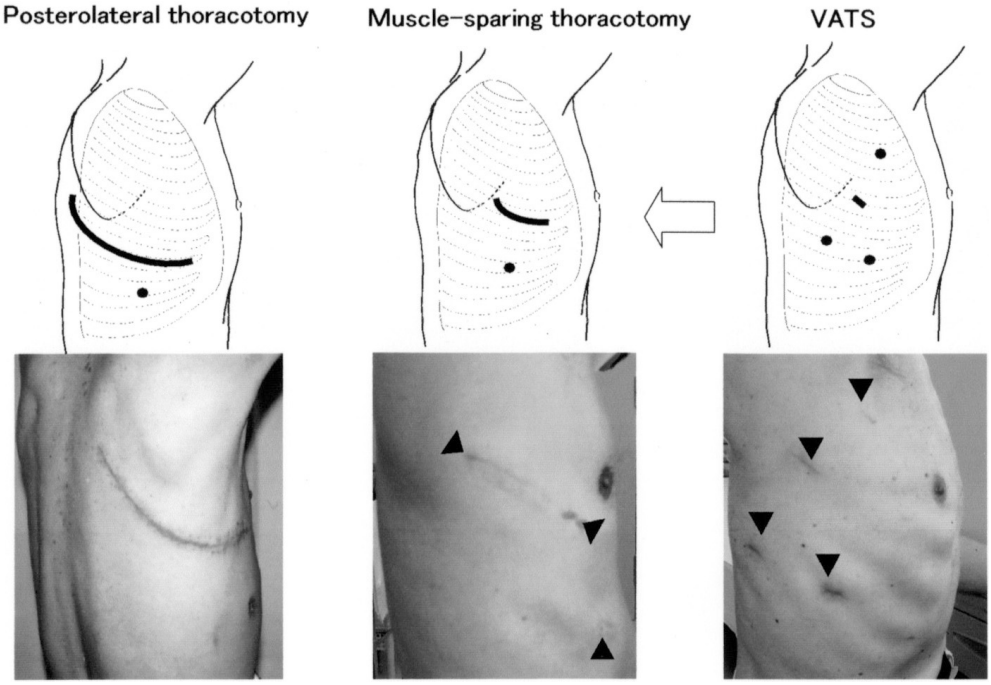

Fig. 6. The scheme and photograph shows a skin incision of thoracotomy in posterolateral thoracotomy, muscle-sparing thoracotomy (MST), and video-assisted thoracic surgery (VATS).
When thoracoscopic observation showed severe adhesions and calcified lymph nodes attached to the pulmonary artery, a thoracic surgeon must consider converting VATS to MST as a second option of a minimally invasive approach to the thorax.

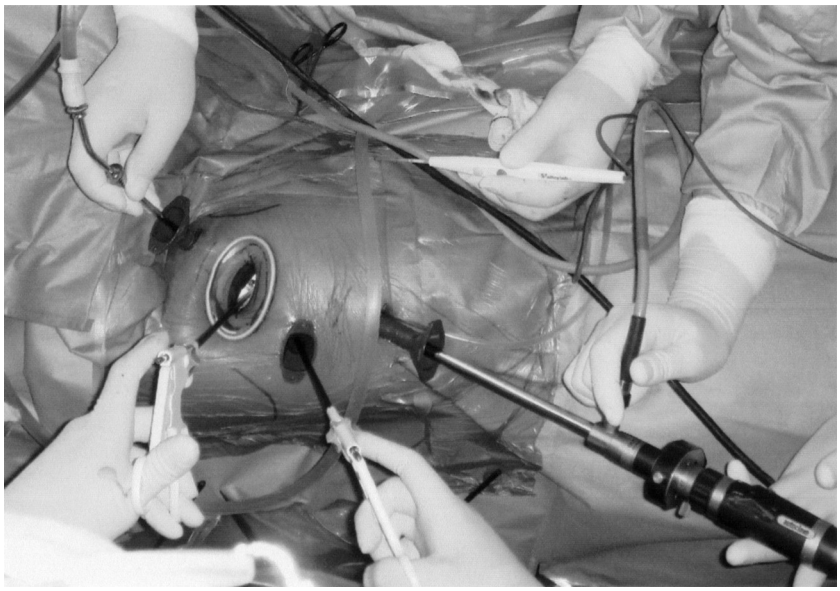

Fig. 7. A video-assisted thoracic surgery (VATS) is performed with a few entry ports and one minithoracotomy to handle endoscopic instruments.
The photograph shows a bird-eye's view of the operating field during a right upper lobectomy with mediastinal lymphadenectomy. The location of ports is used at the Nippon Medical School hospital. Left, heart; bottom, back.

function.[35,36]

(6) Effects on cardiopulmonary circulation

Major pulmonary resection exceeding 35% of lung volume often influences the right ventricular afterload, resulting in chronic right ventricular insufficiency and a marked deterioration of the activities of daily life. Hemodynamics and right ventricular performance after pulmonary resection have been studied along with the history of thoracic surgery. An acute right heart failure resulting from increased right ventricular afterload is sometimes troublesome, especially in a major pulmonary resection.[37] In a comparison of changes in hemodynamics and right ventricular performance during the perioperative phase, a VATS lobectomy showed less influence leading to quick recovery, especially in elderly patients with poor

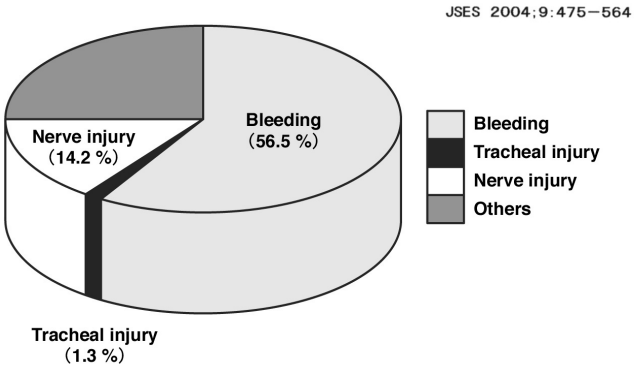

Fig. 8. The most important intraoperative accident was vascular injury (56.5%), consisting of pulmonary artery (56%), intercostal artery (15%), pulmonary vein (12%), superior vena cava, aorta, and others from 1993 to 2003.

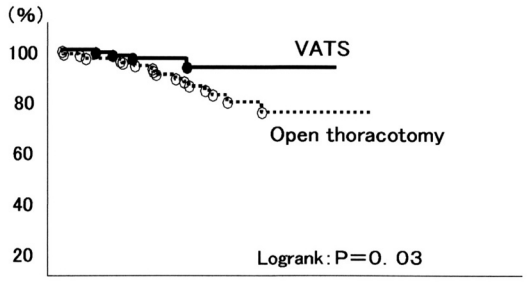

	Number	Age	1yrs	3yrs	5yrs	10yrs
Open thoracotomy	122	62±8 *)	96 %	93 %	85 %	75%
VATS	140	66±9 *)	100 %	96 %	93 %	93%

*Age: P=0.001

Fig. 9. Survival curves in patients who underwent a lobectomy with ND2a by video-assisted thoracic surgery (VATS) and open thoracotomy at the Nippon Medical School hospital.
A total of 140 patients underwent a VATS lobectomy with ND2a, and 122 underwent an open thoracotomy with ND2a during 1994 and 2006; both groups were diagnosed to be pathologically at stage IA.

physical reserve, compared to those of a lobectomy by open thoracotomy.[38,39]

(7) Incidence of intraoperative injury and postoperative complications

(a) Incidence of intraoperative injuries: An important intraoperative surgical accident was vascular injury (Fig. 8). Injury to the pulmonary artery caused massive bleeding followed by operative death. A further refinement of the technique and instrument should be developed.

(b) Postoperative complications: The incidence and types of postoperative complications are similar in patients who underwent VATS or open thoracotomy. However, the complications were less severe in patients who underwent VATS.[16,17,20,21,33] A univariate analysis showed that the duration of surgery was affected by the condition of the thoracic cavity. The Thoracoscopic Society[8] recommends that thoracoscopic surgery should not be continued and should be converted to open thoracotomy when surgery becomes lengthy. Moreover, it is very important to know when an advantage of VATS is lost during an operation. According to an analysis of receiver-operator characteristics curves (ROC curve) for risk factors of VATS lobectomy, Haraguchi et al. mentioned that a surgery lasting more than 297 minutes will offset the advantages of VATS.[40] When severe adhesions caused by chronic inflammation and calcified lymph nodes attached to the pulmonary artery are observed under thoracoscopy, a thoracic surgeon must consider the VATS approach to convert to MST as a minimally invasive approach to the thorax instead of posterolateral thoracotomy (Fig. 6).

5. Postoperative performance status and survival rate

(1) Changes in performance status pre- and postoperation

A deterioration of performance status after surgery is a subject of serious concern for patients, particularly the elderly. We reported the changes in pre- and postoperative performance status. As a result, VATS lobectomy patients showed minimal deterioration after surgery. The recovery speed and the maintenance of performance status were also quick and better in patients who underwent VATS lobectomies, compared to those in patients who underwent a lobectomy by open thoracotomy.[17,18]

(2) Prognosis

The purpose of lung cancer surgery is the achievement of a long-term prognosis. It is clear that a VATS lobectomy cannot be accepted as a surgical treatment of lung cancer if it cannot achieve a survival rate equal to that of an open thoracotomy lobectomy. The survival of lung cancer patients who underwent surgical treatment in Japan is the best worldwide. Even though convalescence and prognosis following VATS lobectomy differs among institutions, the prognosis of patients who underwent a VATS lobectomy seemed to be better survival than that in patients who underwent open thoracotomy.[20–25,33] According to the

investigation committee formed by the Japan Lung Cancer Society and the Japanese Association for Chest Surgery, the 5-year survival rate was 79% at stage IA, 60% at IB, 59% at IIA, 42% at IIB, 28% at IIIA, 20% at IIIB, and 19% at IV. Postoperative death is 3.0%, including 1.4% postoperative mortality rates and 1.6% hospital deaths. At the Nippon Medical School hospital during 1994 and 2006, the VATS lobectomy patients showed a 100% 1-year survival rate, 95% 3-year survival rate, 93% 5-year survival rate, and 93% 10-year survival rate (Fig. 9). The survival rate of VATS lobectomy patients revealed a significant difference compared to those who underwent open thoracotomy lobectomies. Even though thoracic surgeons cannot judge a uniform degree of convalescence after a VATS lobectomy because of the various patient backgrounds, they consider that the VATS procedure is a worthy lung cancer surgical treatment.

6. VATS lobectomy and future prospects

I would like to summarize the characteristic factors of a VATS lobectomy for primary lung cancer. A thoracic surgeon wants to avoid invasive surgical interventions that undermine the physical reserve of patients. It is true that an anatomical lobectomy with mediastinal lymphadenectomy by open thoracotomy has been ideal for primary lung cancer patients. Therefore when a new surgical approach is introduced, thoracic surgeons must have a detailed investigation about whether the new approach will be beneficial. I think several points at issue seem to have been improving over the past decade.

We also remember that experienced thoracic surgeons have been trained to perform VATS lobectomies for 10 years or more since this procedure was introduced to Japan. There remains the issue of how to solve the major problems of this technique, such as safety and prognosis. At present, VATS lobectomies already exceed 20% of all cases of pulmonary lobectomies. Thoracic surgeons of the next generation must attain the skills of their seniors in a shorter time. Therefore senior surgeons must provide an environment conductive for young surgeons to learn manual skills and to acquire hands-on experience in operating new devices. It has been demanded that surgical strategies have changed according to patient's needs, and improvements in surgical procedures and equipment have been made over the past 20 years. An order-made therapy for lung cancer has been investigated based on transrelational research in correlation of basic science and clinical medicine, so that thoracic surgeons should still focus on decreasing the invasiveness of surgical treatment for lung cancer as an option of the combined therapy of lung cancer.

References

1. Graham EA, Singer JJ. Successful removal of an entire lung for carcinoma. *JAMA* 1933; **101**: 1371–4.
2. Cahan WG. Radical pneumonectomy. *J Thorac Surg* 1951; **22**: 449–73.
3. Churchill ED, Sweet RH, Scoutter L, et al. The surgical management of carcinoma of the lung; a study of the cases treated at the Massachusetts General Hospital from 1930–1950. *J Thorac Surg* 1950; **20**: 349–65.
4. Cahan WG. Radical lobectomy. *J Thorac Surg* 1960; **39**: 555–72.
5. Naruke T, Suemasu K, Ishikawa S. Surgical treatment for lung cancer with metastasis to mediastinal lymph nodes. J Thorac Cardiovasc Surg 1976; **71**: 279–85.
6. Jensik RJ. Miniresection of small peripheral carcinoma of the lung. *Surg Clin North Am* 1987; **67**: 951–8.
7. Lung Cancer Study Group (Ginsberg RJ, Rubinstein LV). Randomized trial of lobectomy versus limited resection for T1N0 non-small cell lung cancer. *Ann Thorac Surg* 1995; **60**: 615–23.
8. Mack MJ. Inroduction and general techniques. *Ann Thorac Surg* 1993; **56**: 609.
9. Kohno T, Murakami T, Wakabayashi A. Anatomic lobectomy of the lung by means of thoracoscopy. An experimental study. *J Thorac Cardiovasc Surg* 1993; **105**: 729–31.
10. Lewis RJ. The role of video-assisted thoracic surgery for carcinoma of the lung: wedge resection to lobectomy by simultaneous individual stapling. *Ann Thorac Surg* 1993; **56**: 762–8.
11. Koizumi K, Akaishi T, Wakabayashi A. Anatomic segmental resection of the lung by thoracoscopy: an experimental study. *Surg Today* 1997; **27**: 1051–5.
12. McKenna RJ Jr, Wolf RK, Brenner M, et al. Is lobectomy by video-assisted thoracic surgery an adequate cancer operation? *Ann Thorac Surg* 1998; **66**: 1903–8.
13. Koizumi K, Haraguchi S, Akiyama H, et al. VATS lobectomy for primary lung cancer—experiences based on provisional indications—. *Surg Today* 1998; **28**: 36–40.
14. Iwasaki M, Kaga K, Nishiumi N, et al. Experience with the two-window method for mediastinal lymph node dissection in lung cancer. 1. *Ann Thorac Surg* 1998; **65**: 800–2
15. Ginsberg RJ. Alternative (muscle sparing) incision in thoracic surgery. *Ann Thorac Surg* 1993; **56**: 752–4.
16. Giudicelli R, Thomas P, Lonjon T, et al. Video-assisted minithoracotomy versus muscle-sparing thoracotomy for performing lobectomy. *Ann Thorac Surg* 1994; **58**: 712–7.
17. Koizumi K, Haraguchi S, Hirata T, et al. Video-assisted

lobectomy in elderly lung cancer patients. *Jpn J Thorac Cardiovasc Surg* 2002; **50**: 15–22.
18. Sagawa M, Sato M, Sakurada A, et al. A prospective trial of systematic nodal dissection for lung cancer by video-assisted thoracic surgery: can it be perfect? *Ann Thorac Surg* 2002; **73**: 900–4.
19. Inada K, Shirakusa T, Yoshinaga Y, et al. The role of video-assisted thoracic surgery for the treatment of lung cancer: lung lobectomy by thoracoscopy versus the standard thoracotomy approach. *Int Surg* 2000; **85**: 6–12.
20. Ohtsuka T, Nomori H, Horio H, et al. Is major pulmonary resection by video-assisted thoracic surgery an adequate procedure in clinical stage I lung cancer? *Chest* 2004; **125**: 1742–6.
21. Charagozloo F, Tempesta B, Margolis M, et al. Video-assisted thoracic surgery lobectomy for stage I ling cancer. *Ann Thorac Surg* 2003; **76**: 1009–14.
22. Tatsumi A, Ueda Y. Video-assisted thoracic surgery for lung cancer: is it a feasible operation for stage I lung cancer? *Jpn J Thorac Cardiovasc Surg* 2003; **51**: 646–50.
23. Walker WS, Codispoti M, Soon SY, et al. Long-term outocomes following VATS lobectomy for non-small cell bronchogenic carcinoma. *Eur J Cardiothorac Surg* 2003; **23**: 397–402.
24. Iwasaki A, Shirakusa T, Shiraishi T, et al. Results of video-assisted thoracic surgery for stage I/II non-small cell lung cancer. *Eur J Cardiothorac Surg* 2004; **26**: 158–64.
25. Sugi K, Kaneda Y, Esato K. Video-assisted thoracoscopic lobectomy achieves a satisfactory long-term prognosis in patients with clinical stage IA lung cancer. *World J Surg* 2000; **24**: 27–30.
26. Yim AP, Wan S, Lee TW, et al. VATS lobectomy reduces cytokine responses compared with conventional surgery. *Ann Thorac Surg* 2000; **70**: 243–7.
27. Sugi K, Kaneda Y, Esato K. VATS lobectomy reduces cytokine production more than conventional open thoracotomy. *Jpn J Thorac Cardiovasc Surg* 2000; **48**: 161–5.
28. Nagahiro I, Andou A, Shimizu N. Pulmonary function after lobectomy, postoperative pain, and serum cytokine level after lobectomy: A comparison of VATS and conventional procedure. *Ann Thorac Surg* 2001; **72**: 362–5.
29. Leaver HA, Craig SR, Yap PL, et al. Lymphocyte responses following open and minimally invasive thoracic surgery. *Eur J Clin Invest* 2000; **30**: 230–8.
30. Craig SR, Leaver HA, Yap PL, et al. Acute phase responses following minimal access and conventional thoracic surgery. *Eur J Cardiothorac Surg* 2001; **20**: 455–63.
31. Yamashita JI, Kurusu Y, Fujino M, et al. Detection of circulating tumor cells in patients with non-small cell lung cancer undergoing lobectomy by video-assisted thoracic surgery: a potential hazard for intraoperative hematogenous tumor cell dissemination. *J Thorac Cardiovasc Surg* 2000; **119**: 899–905.
32. Kaseda S, Aoki T, Hangai N, et al. Better pulmonary function and prognosis with video-assisted thoracic surgery than with thoracotomy. *Ann Thorac Surg* 2000; **70**: 1644–6.
33. Nomori H, Ohtsuka T, Horio H, et al. Difference in the impairment of vital capacity and 6-minutes walking after a lobectomy performed by thoracoscopic surgery, an anterior limited thoracotomy, an anteroaxillary thoracotomy, and a posterolateral thoracotomy. *Surg Today* 2003; **33**: 7–12.
34. Koizumi K, Haraguchi S, Hirata T, et al. Video-assisted lobectomy for a lung cancer patient with chronic obstructive pulmonary disease. *Jpn J Thorac Cardiovasc Surg* 2003; **51**: 569–76.
35. Koizumi K, Hirata T, Hirai K, et al. Surgical treatment of lung cancer combined with intestinal pneumonia: the effect of surgical approach on postoperative acute exacerbation. *Ann Thorac Cardiovasc Surg* 2004; **10**: 340–9.
36. Koizumi K, Haraguchi S, Hirata T, et al. Surgical treatment for lung cancer patients with poor pulmonary function. *Ann Thorac Cardiovasc Surg* 2005; **11**: 87–92.
37. Nakada T. A study on the safety limit for the resection of lung cancer from the viewpoint of the cardiopulmonary reserve capacity that is based upon unilateral pulmonary artery occlusion with exercise. *Lung Heart* 1969; **3**: 57–63
38. Mikami I, Koizumi K, Tanaka S. Changes in right ventricular performance in elderly patients who underwent lobectomy using video-assisted thoracic surgery for primary lung cancer. *Jpn J Thorac Cardiovasc Surg* 2001; **49**: 153–9.
39. Yamagishi S, Koizumi K, Shimizu K. Assessment of perioperative hemodynamics and right ventricular performance of lung cancer patient using continuous cardiac monitoring system; comparison between video-assisted thoracic surgery and muscle-sparing thoracotomy. *Ann Thorac Cardiovasc Surg* 2006; **12**: 166–73.
40. Haraguchi S, Koizumi K, Hatori N, et al. Postoperative respiratory complications of video-assisted thoracic surgery for lung cancer. *J Nippon Med Sch* 2004; **71**: 30–4.