

Early Initiation of Polymyxin B–Immobilized Fiber Therapy Effective for Septic Shock after Aortic Replacement

Masanori Murakami, MD,¹ Yoshitoyo Miyauchi, MD,² Masahiko Nishida, MD,¹ Haruhiko Okada, MD,¹ and Kimikazu Hamano, MD³

A 76-year-old female underwent ascending aorta and partial arch replacement. She developed septic shock on postoperative day 6. She was administered dopamine, 10 $\mu\text{g}\cdot\text{kg}^{-1}\cdot\text{min}^{-1}$; dobutamine, 5 $\mu\text{g}\cdot\text{kg}^{-1}\cdot\text{min}^{-1}$; and norepinephrine, 0.3 $\mu\text{g}\cdot\text{kg}^{-1}\cdot\text{min}^{-1}$. However, the blood pressure was 74/40 mmHg. Direct hemoperfusion using polymyxin B–immobilized fiber (PMX-DHP) was started; 3 h later, the blood pressure increased to 118/54 mmHg. Norepinephrine was stopped, and dopamine and dobutamine doses were decreased to 5 $\mu\text{g}\cdot\text{kg}^{-1}\cdot\text{min}^{-1}$ 3 and 12 h after completing PMX-DHP, respectively. In suspected septic shock, early PMX-DHP simultaneously with drug treatment facilitates hemodynamic improvement. (Ann Thorac Cardiovasc Surg 2007; 13: 287–289)

Key words: polymyxin B–immobilized fiber, septic shock, aortic replacement

Introduction

Direct hemoperfusion using polymyxin B–immobilized fiber (PMX-DHP) is an established treatment method for septic shock caused by gram-negative rod infections.¹⁾ However, the use of PMX-DHP after cardiac surgery has not been reported in English medical literature. Here we report one instance in which the early initiation of PMX-DHP therapy resulted in a higher treatment efficacy for postoperative septic shock after aortic replacement.

Case Report

A 76-year-old woman experienced chest pain, headache, and nausea after waking up. On examination at the hospital, her consciousness was clear, and her blood pres-

From Departments of ¹Cardiovascular Surgery and ²Anesthesiology and Critical Care, Shakaihoken Tokuyama Central Hospital, Shunan, and ³Department of Surgery and Clinical Science, Division of Cardiac Surgery, Yamaguchi University Graduate School of Medicine, Yamaguchi, Japan

Received July 25, 2006; accepted for publication December 28, 2006

Address reprint requests to Masanori Murakami, MD: Department of Cardiovascular Surgery, Shakaihoken Tokuyama Central Hospital, Kohdacho 1–1, Shunan 745–8522, Japan.

sure was 104/76 mmHg. Contrast-enhanced computed tomography of the chest revealed a dissection of the ascending aorta, including the innominate artery. We performed ascending and hemiarch aortic replacement, including the innominate artery, by using a four-branch artificial vessel (Hemashield™; Boston Scientific, NJ, USA). The operation time was 734 min; extracorporeal circulatory time, 308 min; extracorporeal circulatory arrest time, 95 min; lowest brain temperature, 19.5°C; and lowest body temperature, 23.9°C. The patient was administered dopamine and dobutamine each at a dose of 2 $\mu\text{g}\cdot\text{kg}^{-1}\cdot\text{min}^{-1}$ as a continuous drip, and the hemodynamic status of the patient was stable. On postoperative day 6, the body temperature increased to 41°C, the blood pressure suddenly decreased, and the urine output decreased (not greater than 0.5 $\text{mL}\cdot\text{kg}^{-1}\cdot\text{h}^{-1}$). Despite our increasing the dopamine and dobutamine doses to 10 and 5 $\mu\text{g}\cdot\text{kg}^{-1}\cdot\text{min}^{-1}$, respectively, the systolic blood pressure was 60 mmHg, and the heart rate was 90 bpm. Neither diarrhea nor pneumonia was observed. The initial dose of norepinephrine was 0.3 $\mu\text{g}\cdot\text{kg}^{-1}\cdot\text{min}^{-1}$; however, the systolic blood pressure remained at 74/40 mmHg. The peripheral body temperature was elevated, and the cardiac output was 7.6 $\text{L}\cdot\text{min}^{-1}$. Blood examination yielded the following values: endotoxin level, 2.55 $\text{pg}\cdot\text{mL}^{-1}$ (turbidi-

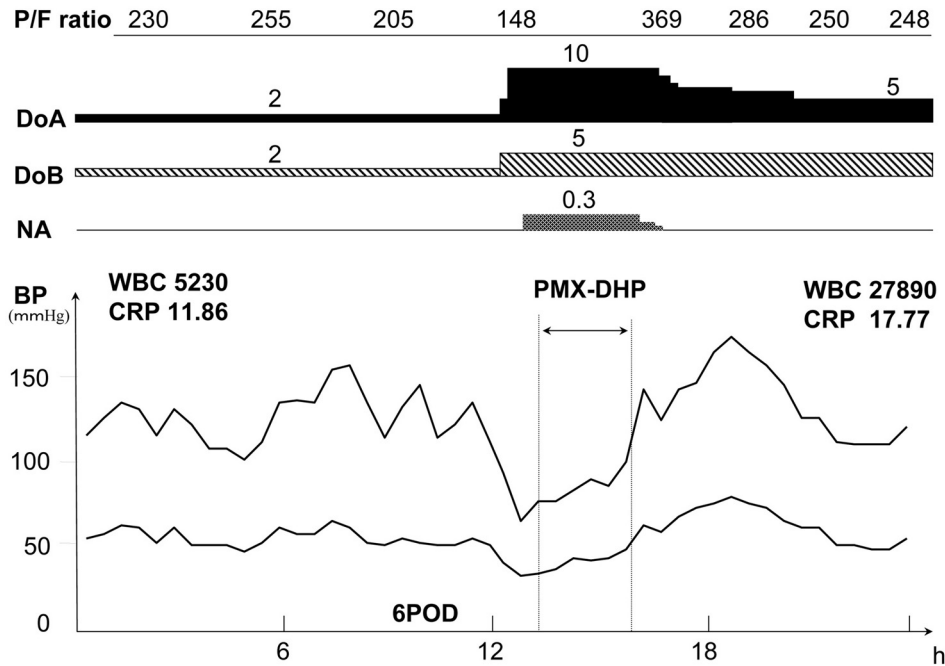


Fig. 1. Course after the operation.

P/F ratio, partial pressure of oxygen in arterial blood/fraction of inspired oxygen ratio; DoA, dopamine ($\mu\text{g}\cdot\text{kg}^{-1}\cdot\text{min}^{-1}$); DoB, dobutamine ($\mu\text{g}\cdot\text{kg}^{-1}\cdot\text{min}^{-1}$); NA, norepinephrine ($\mu\text{g}\cdot\text{kg}^{-1}\cdot\text{min}^{-1}$); BP, blood pressure; WBC, white blood cell; CRP, C-reactive protein; PMX-DHP, polymyxin-B adsorbs endogenous cannabinoids, and direct hemoperfusion therapy; POD, postoperative day.

metric time assay); β -D glucan, $5.13 \text{ pg}\cdot\text{mL}^{-1}$; leucocytes, $5,230 \text{ mm}^{-3}$ (previous day, $6,700 \text{ mm}^{-3}$); and C-reactive protein (CRP), $11.86 \text{ mg}\cdot\text{dL}^{-1}$ (previous day, 15.02). Based on general signs, we diagnosed septic shock. The antibiotic daily dose was changed from 3 g of sulbactam/ampicillin to 2 g of flomoxef and 1 g of pazufloxacin, and PMX-DHP therapy was performed in 217 min. Three hours after the initiation of PMX-DHP therapy, norepinephrine was stopped, and the urine output increased to greater than $1 \text{ mL}\cdot\text{kg}^{-1}\cdot\text{h}^{-1}$. In addition, 12 h later the dopamine and dobutamine doses were both decreased to $5 \mu\text{g}\cdot\text{kg}^{-1}\cdot\text{min}^{-1}$. Under these conditions, the heart rate was 85 bpm; blood pressure, 126/48 mmHg; and urine output, $2 \text{ mL}\cdot\text{kg}^{-1}\cdot\text{h}^{-1}$ (Fig. 1). Neither diuretic drugs nor dialysis was required afterward. After PMX-DHP therapy was performed, the sepsis-related organ failure assessment (SOFA) score improved from 9 to 6, and the acute physiology and chronic health evaluation (APACHE) II score improved from 21 to 11 (since the patient was under sedation, the score for the central nervous system was excluded). Serum creatinine was in the normal range before and after PMX-DHP therapy was performed. On the

next day, the leukocyte and CRP concentrations were $27,890 \text{ mm}^{-3}$ and $17.77 \text{ mg}\cdot\text{dL}^{-3}$, respectively. The arterial blood culture was negative; however, *Klebsiella oxytoca* was detected in a Swan-Ganz catheter tip culture. The patient was disconnected from the respirator on postoperative day 11 and was discharged 68 days after the operation.

Discussion

PMX-DHP is a blood purification therapy that was developed to adsorb blood endotoxins in serious infectious disease states resulting from gram-negative bacterial infections. For the clinical effect of PMX-DHP, raising the blood pressure is expected at the time of septic shock. Currently, an adsorption of various materials and endotoxins from blood is thought to be the mechanism by which PMX-DHP increases blood pressure. Cannabinoids²⁾ are detected in 90% of septic shock cases. These compounds are considered to be a new class of septicemic mediators that can be removed by PMX-DHP. Wang³⁾ reported that a large quantity of anandamide,⁴⁾ which is a

cannabinoid, was adsorbed by a polymyxin B-immobilized bead column. Cannabinoids are induced by various pathways as well as by gram-positive and gram-negative bacteria. Therefore PMX-DHP is thought to be effective in all systemic inflammatory response syndrome (SIRS) states with infection, irrespective of the bacterial species. The present patient had SIRS with infection. The blood endotoxin levels were low, but we diagnosed it as septic shock based on clinical symptoms such as the elevation of body temperature, hemodynamic status, and laboratory data. The causative bacterium was identified as a gram-negative rod; however, the arterial blood culture was negative; thus it is not possible to arrive at a conclusion. We started PMX-DHP 7 h after the body temperature had increased to 39°C and 3 h after the systolic blood pressure had decreased to lower than 80 mmHg; the patient was also administered dopamine and dobutamine each at a dose of 2 $\mu\text{g}\cdot\text{kg}^{-1}\cdot\text{min}^{-1}$ as a continuous drip. The systemic vascular resistance was improved by PMX-DHP. The blood pressure increased and the patient recovered from the shock; thereafter the vasopressor doses could be decreased. We consider that PMX-DHP is useful for improving the hemodynamic status, and a desirable outcome can be obtained if it is performed at an early stage. On the other hand, in the absence of PMX-DHP, the administration of large doses of norepinephrine to increase the blood pressure leads to precapillary circulation failure by stimulating alpha receptors. In a septic state, antibiotics must be administered. However, the delay in antibiotic action and protracted hypotension are very likely to result in the failure of other organs as a result of circu-

lation failure. In our case, since PMX-DHP was initiated at an early stage, we could limit the administration of norepinephrine to a short duration, and this appeared to prevent the failure of other organs.

Cardiac surgery is followed by a state of depressed cardiac function as a result of cardiac disturbances; this state can easily lead to multiple organ failure. During the postoperative course, an early initiation of PMX-DHP simultaneously with drug treatment is effective in patients who develop septic shock resulting from SIRS with infection and are refractory to vasopressor treatment. Further, the $\text{PaO}_2/\text{FIO}_2$ ratio that worsens in the presence of hypotension was improved by immediate PMX-DHP therapy. There is a possibility that PMX-DHP is also effective in improving lung function.

References

1. Aoki H, Kodama M, Tani T, Hanasawa K. Treatment of sepsis by extracorporeal elimination of endotoxin using polymyxin B-immobilized fiber. *Am J Surg* 1994; **167**: 412–7.
2. Varga K, Wagner JA, Bridgen DT, et al. Platelet- and macrophage-derived endogenous cannabinoids are involved in endotoxin-induced hypotension. *FASEB J* 1998; **12**: 1035–44.
3. Wang Y, Liu Y, Sarker KP, et al. Polymyxin B binds to anandamide and inhibits its cytotoxic effect. *FEBS Lett* 2000; **470**: 151–5.
4. Maccarrone M, van der Stelt M, Rossi A, et al. Anandamide hydrolysis by human cells in culture and brain. *J Biol Chem* 1998; **273**: 32332–9.