Case Report

Tumescent Local Anesthesia for a Revascularization of a Coronary Subclavian Steal Syndrome

Taketomo Mizukami, MD, and Masaki Hamamoto, MD, PhD

Tumescent local anesthesia (TLA), originally developed for liposuction, has found widespread application. We report a case of peripheral arterial bypass grafting under TLA. The patient was an 84-year-old female diagnosed as having coronary subclavian steal syndrome caused by proximal left subclavian artery stenosis. Because she had several risk factors for general anesthesia, we performed axilloaxillary artery bypass grafting under TLA and mild sedation. There was no morbidity related to the surgery. The TLA technique may be ideal for performing peripheral arterial bypass grafting if general anesthesia is inappropriate because of cardiac complications. (Ann Thorac Cardiovasc Surg 2007; 13: 352–354)

Key words: tumescent local anesthesia, coronary subclavian steal syndrome, peripheral vascular disease, revascularization

Introduction

The tumescent technique for local anesthesia (TLA), originally developed for liposuction, permits regional local anesthesia of the skin and subcutaneous tissues by direct infiltration. This technique uses large volumes of a dilute anesthetic solution to produce swelling and firmness of target areas. It is now being expanded for use in other surgical procedures. Here, for the first time, we report a case of axilloaxillary arterial bypass grafting under TLA in a patient with coronary artery disease who had several risk factors for general anesthesia.

Case Report

The patient was an 84-year-old female who in May 1996 underwent coronary artery bypass grafting with a left internal mammary artery (LIMA) graft anastomosed to the left anterior descending coronary artery. The postoperative course was uneventful, and she had been free from anginal symptoms until the onset of anterior chest pain in June 2005. Coronary arteriography showed that the LIMA graft was patent, but flow was reserved. Brachiocephalic arteriography showed 90% stenosis of the proximal left subclavian artery (Fig. 1). She was diagnosed as having coronary subclavian steal syndrome (CSSS). We first planned axilloaxillary arterial bypass surgery under general anesthesia. However, she was classified as American Society of Anesthesiologists class IV because of her advanced age, angina pectoris, hypertension, diabetes mellitus, and respiratory obstruction. Therefore we tried to perform this procedure under TLA.

Mild sedation was initiated using a combination of midazolam and fentanyl. After local anesthesia using 1% lidocaine, the bilateral axillary arteries were exposed and isolated with umbilical tape. The TLA solution was infiltrated subcutaneously along the route of an artificial graft between the subclavian skin incisions by means of a handheld syringe injection using a 16-gauge cannula of appropriate length (Fig. 2). The solution consisted of 450 mL of 0.9 normal saline, 50 mL of lidocaine 1% with epinephrine 1:100,000, and 16 mL of sodium bicarbonate 8.4% as described by Bush and Hammond.[1] The total amount of TLA solution we used was 105 mL. An 8 mm expanded polytetrafluoethylene artificial graft was passed through subcutaneously and anastomosed to both axillary arteries in end-to-side fashion. The patient required

Department of Cardiovascular Surgery, Onomichi General Hospital, Hiroshima, Japan

Received January 9, 2007; accepted for publication July 1, 2007
Address reprint requests to Taketomo Mizukami, MD: Department of Cardiovascular Surgery, Onomichi General Hospital, 7–19 Kohama-cho, Onomichi, Hiroshima 722–8508, Japan.

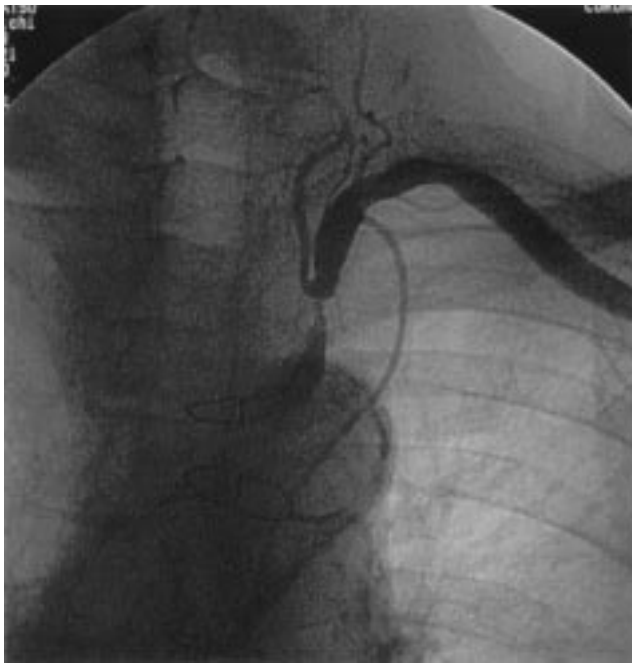

Fig. 1. Arteriogram demonstrating 90% stenosis of the proximal left subclavian artery and a patent internal mammary artery graft with a reversal of flow.

no airway management with the exception of supplemental mask oxygen. There was no peri- or postoperative morbidity, mortality, or graft occlusion. She had no anginal attack for 15 months after the operation.

Comment

CSSS is an unusual clinical syndrome after successful internal mammary coronary artery bypass grafting. Several procedures such as extra-anatomical surgical reconstruction and percutaneous transluminal angioplasty (PTA) and stenting can be used for treatment of CSSS. A carotid-subclavian bypass had been a standard treatment, but an ultrasonography of neck vessels demonstrated severe atherosclerosis in the left common carotid artery, suggesting a high risk of brain ischemia and atheroembolism during the operation. PTA and stent emplacement might lead to atheroembolism in an LIMA graft. In our patient, general anesthesia seemed inappropriate because of advanced age, angina pectoris, hypertension, diabetes mellitus, and respiratory obstruction (categorized as American Society of Anesthesiologists class IV). Patients with vascular disease have a particularly high prevalence of associated medical conditions. Forty percent to 60% have hypertension, 50–70% have intrinsic cardiac disease, 25–50% have chronic obstructive pulmonary disease, and approximately 10% have diabetes mellitus or renal insufficiency. Conditions that have been identified as risk factors for vascular surgery include angina pectoris, previous myocardial infarction, and congestive heart failure, and the higher incidence of coronary artery occlusive disease accompanies peripheral atherosclerotic disease. To reduce these complications, local anesthesia has theoretical and practical advantages and should be considered as an alternative to general or regional anesthesia.[2] Therefore we tried to perform axilloaxillary arterial bypass grafting under TLA.

TLA, a special kind of local anesthesia, was originally developed for liposuction surgery and has been applied to many other surgical procedures. In the field of vascular surgery, TLA has been used for ambulatory phlebectomy and for high ligation of the saphenous vein with stripping.[1,3] The advantages of using it include ability to anesthetize large areas without lidocaine levels in the plasma reaching toxic levels, improved hemostasis, positive effect on intravascular fluid status, avoidance of general anesthesia, less pain, and shorter postoperative recovery time.[4] Treated areas remain at least partially anesthetized for up to 18 h after surgery. The prolonged and profound anesthesia of skin and subcutaneous tissues pro-

Fig. 2. Anesthetic cannula being inserted along the bypass graft passage as the anesthetic is delivered by the tumescent technique.

vided by the tumescent technique is probably a result of exposing sufficient lengths of sensory axons to marginal blocking concentrations of lidocaine. The traditional maximal safe dosage of lidocaine is 7 mg/kg. When the tumescent technique is used, however, the maximal safe dosage of dilute lidocaine is 35 mg/kg.[4] We were therefore able to use up to 3,000 mL of the solution. In this case, we used only 105 mL of TLA solution (including about 10 mg of lidocaine), which is far from the toxic dose. Postoperative pain was well controlled without analgesia, and we observed no evidence of systemic toxicity. Besides minimizing lidocaine toxicity, the potential advantage of the tumescent technique may be the reduced volume of IV fluid required during the procedure. Extensive vasoconstriction included by large volumes of dilute epinephrine minimizes blood loss without tachycardia and hypertension. The mechanical and pharmacological properties of the solution that is injected subcutaneously prevent massive shifts of intravascular fluids. There is no longer any need to replace significant volumes of IV fluids. The maintenance of adequate blood pressure and peripheral perfusion throughout vascular procedures may improve the perioperative patency of bypass grafts. There was no perioperative instability of circulatory dynamics and graft occlusion in our patient, who was free from anginal symptoms and congestive heart failure after the surgery.

In summary, we successfully performed axilloaxillary arterial bypass grafting for CSSS under TLA. Although we have not analyzed the feasibility of TLA for a large contemporary series of patients undergoing peripheral arterial bypass grafting, TLA can be considered as an efficient, easy-to-apply, and low-risk alternative to general or regional anesthesia in selected patients with cardiac complications.

References

1. Bush RG, Hammond KA. Tumescent anesthetic technique for long saphenous stripping. J *Am Coll Surg* 1999; **189**: 626–8.
2. Barkmeier LD, Hood DB, Sumner DS, et al. Local anesthesia for infrainguinal arterial reconstruction. *Am J Surg* 1997; **174**: 202–4.
3. Cohn MS, Sieger E, Goldman S. Ambulatory phlebectomy using the tumescent technique for local anesthesia. *Dermatol Surg* 1995; **21**: 315–8.
4. Klein JA. The tumescent technique. Anesthesia and modified liposuction technique. *Dermatol Clin* 1990; **8**: 425–37.