Case Report

Aortic Root Replacement with a Mechanical Valve and Prosthetic Conduit for the Complicated Degeneration of the Ascending Aorta Resulting from Infective Endocarditis

Hirotaka Inaba, MD,[1] Tatsuo Kaneko, MD,[2] Masahiko Ezure, MD,[2] Yasushi Sato, MD,[2] Yutaka Hasegawa, MD,[2] and Ikuko Shibasaki, MD[2]

A 28-year-old man with infective endocarditis of the aortic valve underwent a course of antibiotic therapy, but developed severe aortic root deformity requiring aortic root replacement with a mechanical composite valve conduit. Of note, this patient had undergone a previous aortic valve operation for bicuspid valve stenosis, and indurations and fragility of the aortic root caused by the preceding operation may have contributed to subsequent aortic root deformity during the course of infective endocarditis of the aortic valve. Over the 7-year follow-up period, the patient showed no signs of recurrent infection or new cardiac events. For younger patients with endocarditis, the use of a mechanical valve and prosthetic conduit with sufficient surgical debridement and appropriate antibiotic therapy appears to be a safe and effective treatment strategy. (Ann Thorac Cardiovasc Surg 2007; 13: 355–359)

Key words: infective endocarditis, aortic root replacement, congenital bicuspid aortic valve stenosis, mechanical valve, prosthetic conduit

Introduction

Surgical management of infective endocarditis involving the heart valve preferably takes place after a course of intravenous antibiotics has been administrated and after the resolution of the active phase of infection. However, a sudden deterioration of the aortic root can occur anytime during the infection, even after antibiotics have been initiated.

Several strategies can be used to improve outcomes in patients undergoing surgical management of infective endocarditis, including the use of homografts,[1–3] the Ross procedure,[4] or stentless xenografts.[5,6] Indeed, investigators have suggested that mechanical valves and prosthetic conduit yield results that are comparable to those achieved by the use of homografts.[7–9]

The present report describes a patient with a deformation of the aortic root secondary to infective endocarditis who underwent surgical management with a mechanical valve and prosthetic conduit and who experienced good results.

Case

A 28-year-old man with a single coronary artery and a history of valvotomy of the aortic valve (division of the fused commissures) at 13 years of age secondary to a diagnosis of congenital bicuspid aortic valve stenosis presented with general fatigue, loss of appetite, and high-grade fever lasting for 2 weeks. The patient was admitted to our hospital for evaluation and treatment. An echocardiography revealed a vegetation on the aortic valve, 3/4 grade aortic regurgitation, and a left ventricular ejection fraction of 0.71. There was no particular change in the

From [1]Department of Cardiac Surgery, Asahi General Hospital, Chiba, and [2]Division of Cardiovascular Surgery, Gunma Prefectural Cardiovascular Center, Gunma, Japan

Received September 13, 2006; accepted for publication July 1, 2007
Address reprint requests to Hirotaka Inaba, MD: Department of Cardiac Surgery, Asahi General Hospital, I–1326 Asahi, Chiba 289–2511, Japan.

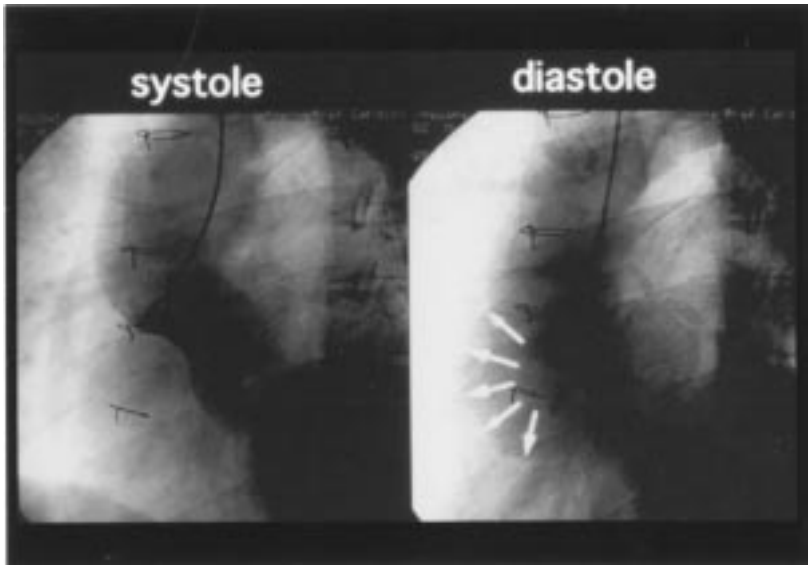

Fig. 1. The preoperative aortography.
Arrows show the margin of the aneurysmal cavity in front of the ascending aorta, which was contrasted during the diastolic phase.

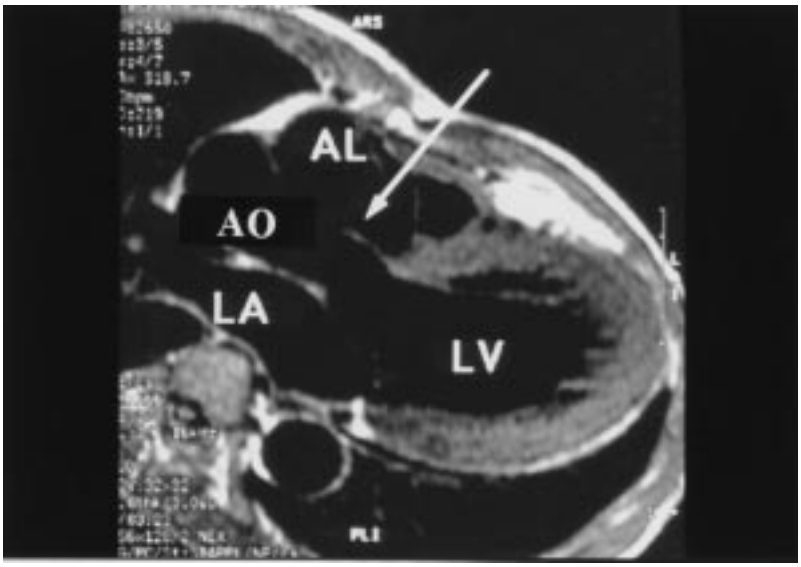

Fig. 2. The aneurysmal lesion depicted by magnetic resonance imaging.
The arrow shows the wall separating the aneurysmal lesion from the ascending aorta. AL, aneurysmal lesion; AO, ascending aorta; LA, left atrium; LV, left ventricle.

aortic root. Streptococcus was detected in blood cultures, and antibiotics were initiated for a diagnosis of infective endocarditis. After an administration of antibiotics for 12 weeks, the patient's fever had resolved, and his white blood cell count and C-reactive protein normalized. However, the patient subsequently developed dyspnea, and echocardiography revealed a progression of the aortic regurgitation to grade 4/4, formation of an aneurysmal lesion just proximal to the aortic root that was not detected at the time of the admission, and a left ventricular

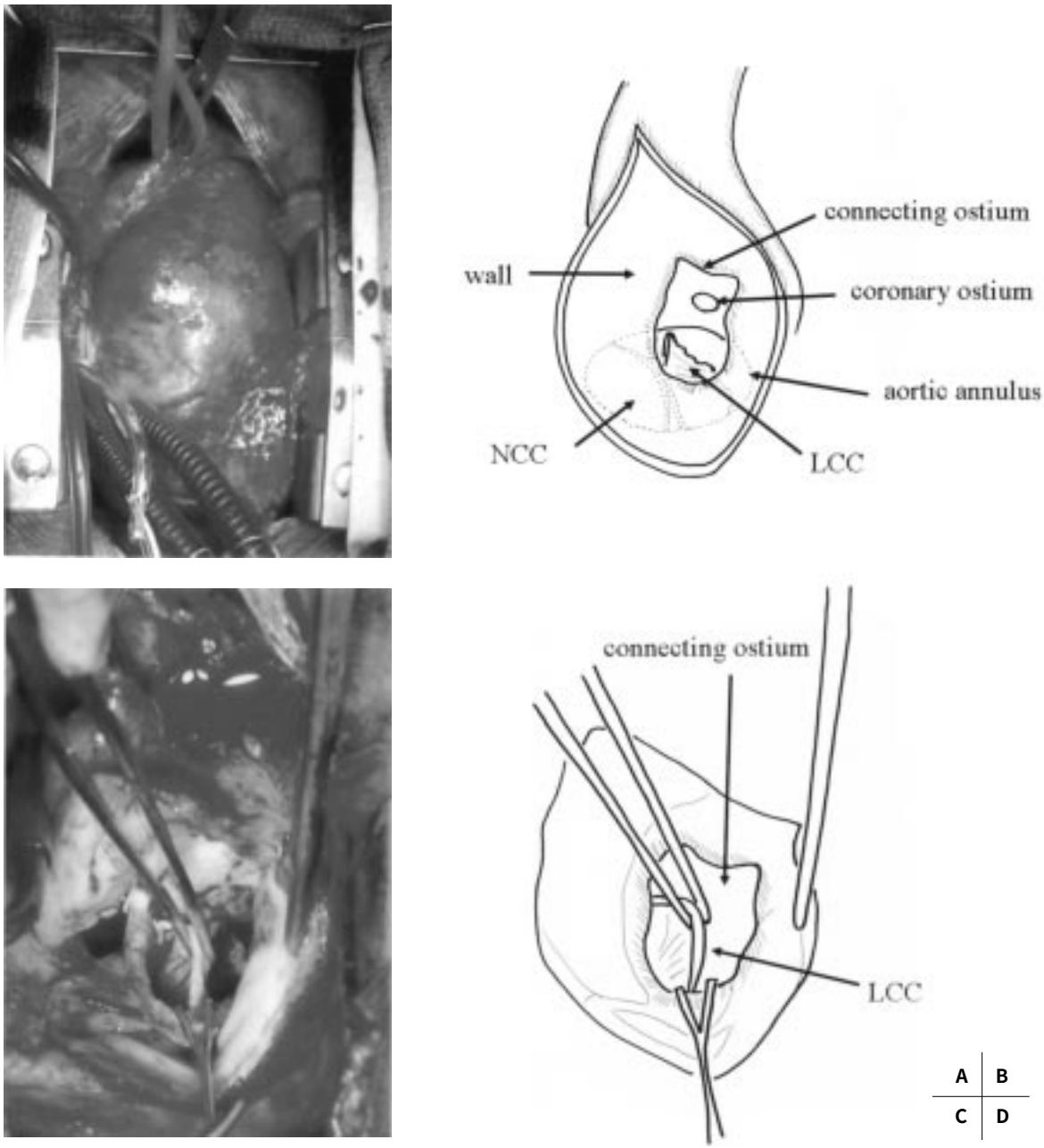

Fig. 3.

A: Intraoperative finding of the ascending aorta. The aortic root has aneurysmal change including Valsalva.

B: Schematic drawing of the inside of the aneurysmal cavity. The true aortic lumen was located posterior to the wall between the aneurysmal cavity and the ascending aorta. The LCC detached from the annulus was extruded through the connecting ostium. The single left coronary artery could be seen through the ostium. The NCC, located posterior to the wall, could not be seen through the ostium. LCC, left coronary cusp; NCC, noncoronary cusp.

C: The finding of the inside of the aneurysmal cavity. The LCC picked with a forceps extruded into the aneurysmal cavity through the connecting ostium.

D: Schematic drawing on the C panel focused on the inside of the aneurismal cavity.

ejection fraction of 0.41. Further, aortography showed a cavity just proximal to the ascending aorta, which was contrasted during the diastolic phase (Fig. 1). Magnetic resonance imaging showed an aneurysmal lesion incompletely separated from the ascending aorta by a septal wall (Fig. 2).

The patient underwent operative management of the affected valve on September 24, 1998, through a midline sternotomy. The right femoral artery and both cavae were cannulated. A cardiopulmonary bypass was established with normothermia, and the minimal temperature of the urinary bladder was maintained above 33.5°C. An aneurysmal change was observed in the ascending aortic root, including the sinus of Valsalva (Fig. 3A). After cross-clamping of the aorta, the aneurysmal lesion was opened. The inside of the wall of the aneurysm was smooth with no signs of abscess formation. An opening of the aneurysm revealed another wall with an ostium to the aortic lumen, through which a single left coronary artery was visualized. The left coronary cusp had vegetation, was widely perforated at its annular portion, was detached from the annulus, and extruded into the aneurysmal cavity through this connecting ostium (Fig. 3, B–D). This cusp was dissected first, followed by the wall between the cavity and the aortic lumen, revealing the ascending aorta and the noninfected aortic cusp (e.g., the noncoronary cusp) with an intact annulus. This cusp was also dissected, and a reinspection of the annulus of the infected left cusp revealed destruction and wide dilation of the annulus. The diameter of the aortic annulus was estimated as 21 mm by preoperative echocardiography, but the actual size measured during the surgery was 27 mm, probably because of the destruction and dilatation of the annulus. The single coronary artery was located at the same point as the normal left coronary artery. The annulus and the sinus of Valsalva were also destroyed.

A Bentall type of operation was performed. After an excision of all structures that were destroyed and deformed by infection, a composite graft replacement of the ascending aorta was performed with a mechanical valve (27 mm St. Jude Medical mitral valve; St. Jude Medical, St. Paul, MN, USA) and a prosthetic conduit (28 mm Hemashield Woven Double Velour Vascular Graft; Meadox Medicals Inc., Oakland, NJ, USA). The valve was placed on the aortic annulus in an inverse orientation. The coronary artery was directly anastomosed to the conduit.

Although preoperative laboratory data suggested the resolution of active infection, a culture of the vegetations obtained during surgery was positive for Acinetobacter, which is sensitive to almost all antibiotics. Although it could be possible that the result was falsely positive as a result of contamination, a 3-week course of intravenous antibiotics was subsequently administered, followed by an 8-week course of oral antibiotics, just as a precaution. The patient was discharged from the hospital on December 14, 1998. Over the 7-year follow-up period, the patient experienced no recurrent infection or any new cardiac events.

Discussion

A surgical management of infective endocarditis involving the heart valve preferably takes place after a course of intravenous antibiotics has been administrated and after a resolution of the active phase of infection. In the present case, a long course of antibiotics presumptively resulted in the resolution of the active phase of infective endocarditis. However, the patient experienced symptomatic progression of aortic regurgitation and deformation of the aortic root. Of note, this patient had undergone a previous aortic valve operation for bicuspid valve stenosis, and indurations and fragility of the aortic root caused by the preceding operation may have contributed to subsequent aortic root deformity. According to the site of the deformation, we thought that the cause of the aneurysmal change was infection at the previous aortotomy site during the course of infective endocarditis of the aortic valve.

There are several alternatives to the use of mechanical prosthetic valves for the surgical management of infective endocarditis. Indeed, investigators have reported that homografts[1–3] or the Ross procedure[4] may produce results that are superior to those obtained with the use of mechanical prosthetic valves. However, the limited availability of aortic and pulmonary homografts precludes their widespread use, especially in Japan. Furthermore, in the present case, an uncertainty regarding the diameter of the aortic annulus made the use of a homograft problematic.

Although stentless xenografts have been increasingly used in patients with infective endocarditis,[5,6] the long-term durability of the stentless valve remains unclear. Bach et al. observed that the durability data of the stentless valve in older patient cohorts may not apply to younger patients, though they reported excellent 10-year outcomes.[10] Thus the use of a stentless valve was not thought to be appropriate in the present case.

By contrast, mechanical valves and prosthetic conduit have sufficient durability. Furthermore, some investiga-

tors suggest that the use of a mechanical valve and prosthetic conduit is the procedure of choice for patients with endocarditis and a low risk of recurrence.[7–9] However, the radical debridement of infected and necrotic tissue may be the most decisive factor for a successful outcome[7] and may have a more serious impact on it than the choice of the replacement device.[8] Hagl et al. suggested that appropriate postoperative antibiotic therapy also contributes to the low operative mortality and incidence of recurrent endocarditis.[7] In the present case, although preoperative laboratory data suggested the resolution of active infection, a culture of the vegetations obtained during surgery was positive for Acinetobacter. However, a complete excision of the infected tissues and postoperative antibiotic therapy rather than the choice of the replacement device were quite likely the main factors related to the good outcome.

Conclusions

A frequent reevaluation of valvular function is necessary in cases of endocarditis because the unexpected progression of the lesion may occur despite a resolution of the active phase of infection. For younger patients with endocarditis, the use of a mechanical valve and prosthetic conduit with sufficient surgical debridement and appropriate antibiotic therapy appears to be a safe and effective treatment strategy.

References

1. Grinda JM, Mainardi JL, D'Attellis N, et al. Cryopreserved aortic viable homograft for active aortic endocarditis. *Ann Thorac Surg* 2005; **79**: 767–71.
2. Niwaya K, Knott-Craig CJ, Santangelo K, et al. Advantage of autograft and homograft valve replacement for complex aortic valve endocarditis. *Ann Thorac Surg* 1999; **67**: 1603–8.
3. Sabik JF, Lytle BW, Blackstone EH, et al. Aortic root replacement with cryopreserved allograft for prosthetic valve endocarditis. *Ann Thorac Surg* 2002; **74**: 650–9.
4. Pettersson G, Tingleff J, Joyce FS. Trearment of aortic valve endocarditis with the Ross operation. *Eur J Cardiothorac Surg* 1998; **13**: 678–84.
5. Fukui T, Suehiro S, Shibata T, et al. Aortic root replacement with Freestyle stentless valve for complex aortic root infection. *J Thorac Cardiovasc Surg* 2003; **125**: 200–203
6. Sakaguchi T, Sawa Y, Ohtake S, et al. The Freestyle stentless bioprosthesis for prosthetic valve endocarditis. *Ann Thorac Surg* 1999; **67**: 533–5.
7. Hagl C, Galla JD, Lansman SL, et al. Replacing the ascending aorta and aortic valve for acute prosthetic valve endocarditis: is using prosthetic material contraindicated? *Ann Thorac Surg* 2002; **74**: S1781–5.
8. Aagaard J, Andersen PV. Acute endocarditis treated with radical debridement and implantation of mechanical or stented bioprosthetis devices. *Ann Thorac Surg* 2001; **71**: 100–4.
9. Bauernschmitt R, Jokob HG, Vahl CF, et al. Operation for infective endocarditis: results after implantation of mechanical valves. A*nn Thorac Surg* 1998; **65**: 359–64.
10. Bach DS, Kon ND, Dumesnil JG, et al. Ten-year outcome after aortic valve replacement with Freestyle stentless bioprosthesis. *Ann Thorac Surg* 2005; **80**: 480–7.